SCHEMATIC ANATOMY

WILLIAM. P. MEARS. M. B.

SCHEMATIC ANATOMY;

OR,

DIAGRAMS, TABLES AND NOTES
TREATING OF THE ASSOCIATION AND SYSTEMATIC ARRANGEMENT OF
STRUCTURAL DETAILS OF HUMAN ANATOMY.

BY

WILLIAM P. MEARS, M.B.,

CO-LECTURER ON ANATOMY, SUPERVISOR OF DISSECTIONS AND MEDICAL TUTOR AT THE UNIVERSITY OF
DURHAM COLLEGE OF MEDICINE, NEWCASTLE-UPON-TYNE.

LONDON:
BAILLIÈRE, TINDALL, AND COX, 20, KING WILLIAM STREET, STRAND.
1882.

PREFACE.

THIS series of Tables and Diagrams was originally devised by the Author for the use of Students in his own Classes at the University of Durham College of Medicine, to supplement his Lectures delivered during the Winter Session of 1880—1881 by supplying notes of greater accuracy on important details than might else have been collected by the Students themselves. The work, therefore, makes no pretension to being a complete descriptive Manual of Anatomy; to have made it so would have defeated the aim kept in view in its compilation, which is to afford, as its title expresses, a series of systematic and associated Schemata.

For a considerable period the Author has found the system here adopted of the utmost service, alike to the Teacher whilst demonstrating and to the Student whilst learning. By its aid the multitude of otherwise unassociated anatomical facts are docketed, as it were, and arranged for immediate use when required; and details, classified in their proper relation, are more readily retained in the memory. When fully worked out, it renders the omission of any one of the facts under consideration impossible, thus also tending to remedy the fault most frequently deplored by Examiners in Anatomy.

It is essential for the Reader to understand, that as the Tables and Diagrams cannot be used without reference to the full descriptions and representations given in the various Text-books of Anatomy, the former are in no way intended to take the place of the latter; still less are they intended to supplant the *only* method of obtaining a real knowledge of Anatomy, viz., actual work in the Dissecting-Room. They are meant rather to supplement those means of study. Their presumed value lies in the clearer knowledge to be obtained by comparing them with the dissected part: the Diagram is thus imprinted, as it were, upon the Region, and a more lasting mental impression is carried away by the observer. The facts to be noted are first displayed on the dead subject, and then fixed in the memory by means of the corresponding Schema or Diagram.

It is the disappointing experience of every Medical Student, in consequence of the enormous amount of material with which he is now obliged to overload his memory, that facts such as those with which Anatomy deals, being as they are isolated and independent, hung together by no uniting bond, and amenable apparently to no law, are speedily crowded out by fresh matter and forgotten, or, at the best, left before the mind as dim and blurred pictures, intermingled and confused. That there is often, however, some method of associating together such details—as, for example, by their analogies and dissimilarities, their points of agreement or antithesis—it is the object of the present volume to show. In it the design above indicated will be apparent, both in the Diagrams, where for a number of ideas one idea is generally substituted, and also in the Text, where common or opposite characteristics of facts or groups of facts are used for the purpose of classification.

In the present volume the Bones, Ligaments, Muscles, Vessels and Nerves only are treated of, since they were more especially dealt with by the Author last Winter. The remainder of the series he hopes to complete later on. Of the many shortcomings of the book as it is he is deeply conscious, especially in regard to the Diagrams, which, in order to ensure accuracy and to keep the price of the book within reasonable limits, have been for the most part home-drawn.

Whether any of the analogies or homologies hinted at (some of which certainly appear to be remarkable,) have a wider or deeper meaning, the Author cannot at present undertake to say; but believing that much more may be done in the same direction, and trusting that what has been done may perhaps prove of some little service to others, he has ventured to bring the subject forward, although it is by no means so fully worked out as he hopes it may in time become.

University of Durham College of Medicine,
October, 1881.

LIST OF DIAGRAMS.

BONES.

DIAGRAM		TO FACE PAGE
1.	Occipital Bone	10
2.	Parietal Bone	11
3.	Temporal Bone (External Aspect)	12
4.	Petrous Part of Temporal Bone	13
5.	Hyoid Bone and Inferior Maxilla	18
6.	Base of Skull	19
7.	Foramina on Anterior Surface of Sphenoid	20
8.	Orbital Fossa and Nasal Fossa	21
9.	Sternum and First Rib	22
10.	Clavicle	24
11.	Humerus	25
12.	Ulna	28
13.	Radius	29
14.	Grooves on lower ends of Radius and Ulna, and Carpal Bones (Articular Surfaces)	30
15.	Metacarpal Bones (Bases), and Phalanges of Hand	31
16.	Pubes and Ischium (External Surfaces)	34
17.	Diameters of Pelvis	35
18.	Femur (Muscles on posterior aspect)	36
19.	Great Trochanter (Lines and Muscles of)	37
20.	Patella—Articular Surface	38
21.	Tibia (Upper Surface of Head)	
22.	Tibia and Fibula (Muscles on posterior aspect)	39
23.	Fibula, transverse section—Tibia and Fibula (Grooves on Lower Extremities)	40
24.	Tarsus and Metatarsus	41
25.	Ossification of Vertebræ, Atlas, Axis and Sacrum	44
26.	„ „ Coccyx, Occipital and Sphenoid Bones	45
27.	„ „ Sternum, Clavicle and Scapula	46
28.	„ „ Humerus, Radius, Ulna and Carpus	47
29.	„ „ Os Innominatum, Femur, Tibia, Fibula and Tarsus	48

LIGAMENTS.

30.	Ligaments of Vertebræ	52
31.	Atlo-axoid and Occipito-atloid Ligaments	53
32.	Ligaments of Clavicle	54
33.	Shoulder Joint	55
34.	Radio-ulnar Joints, etc., and Carpo-metacarpal Ligaments	56
35.	Hip-joint	60
36.	Knee-joint (Ligaments)	61
37.	Knee-joint (Bursæ and Cartilages)	62
38.	Tibio-fibular Ligaments and Tarso-metatarsal Ligaments	63

MUSCLES.

39.	Muscles of Face	68
40.	Origins of Recti Oculi, and Relation of Muscles to Orbit, etc.	70
41.	Layers in Upper Eyelid, and Relation of Obliqui to Recti Oculi	71
42.	Muscles of Pterygo-maxillary Space and External Pterygoid Muscle (relation to Nerves)	72
43.	Longus Colli and Muscles of Posterior Triangle	73
44.	Hyoid Muscles and Submaxillary Region (Section)	76
45.	Constrictors of Pharynx	77
46.	Soft Palate and Tongue (Muscles of)	80
47.	Longissimus Dorsi, etc.	82
48.	Muscular attachments at Back of Neck	83

Muscles—*continued.*

DIAGRAM		TO FACE PAGE
49.	Muscles of Abdominal Wall and of Thoracic Wall	86
50.	Pelvic attachments of Lateral Muscles of Abdomen	87
51.	Muscles acting on Shoulder-joint and Shoulder-girdle	92
52.	Muscles of Shoulder-girdle	93
53.	Muscles of Shoulder and Elbow	94
54.	Muscles of Forearm	95
55.	Muscles of Hand (relative positions)	98
56.	Muscles of Hand (transverse section)	99
57.	Section of Thigh	100
58.	Psoas Magnus (relation to Nerves)	101
59.	Muscles in relation with Neck of Femur and Muscles arising from Tuber Ischii	102
60.	Muscles of Front of Leg and of Back of Leg	104
61.	Section above Ankle and at middle third of Leg	105
62.	Muscles of Foot (relative positions)	106
63.	Section of Foot	107

VESSELS.

64.	Intercostal Arteries, Posterior Mediastinum and Spinal Arteries	118
65.	Relations of Abdominal Aorta	119
66.	Branches of Aorta	120
67.	Cœliac Axis and Diaphragmatic Arteries	121
68.	Relations of Common Iliac Artery and Branches of Internal Pudic Artery and Pudic Nerve	124
69.	Relations of Femoral Artery	125
70.	Anastomoses around Hip	128
71.	Anastomoses around Knee	129
72.	Dorsal Arteries of Foot and Hand	130
73.	Lingual, Facial and Pharyngeal Arteries	136
74.	Internal Maxillary Artery (Branches)	137
75.	Arteries of Cerebrum	140
76.	Axillary Artery (Relation to Nerves and Branches)	141
77.	Anastomoses of Scapular Arteries and Anastomoses round Elbow	142
78.	Arteries of Forearm (relative positions)	143
79.	Arteries of Scalp and Arteries of Nose	146
80.	Arteries and Nerves of Eyelids	147
81.	Arteries and Nerves of Teeth and Arteries of Stomach	148
82.	Arteries and Veins in relation with Pancreas	149
83.	Arteries of Trunk-walls	150
84.	Veins of Neck	151
85.	Azygos Veins, etc.	154

NERVES.

86.	Deep Nerves of Neck, Diagram A	160
87.	Deep Nerves of Neck, Diagram B	161
88.	Cardiac Plexus (Deep and Superficial)	162
89.	Solar Plexus	163
90.	Hypogastric and Pelvic Plexuses	164
91.	Cutaneous Nerves of Head and Neck and of Arm	165
92.	Cutaneous Nerves (Posterior Aspect of Body)	168
93.	Cutaneous Nerves (Anterior Aspect of Body)	169
94.	Intercostal Nerves, and Ilio-hypogastric and Ilio-inguinal Nerves	170
95.	Nerves of Orbit	171
96.	Superior Maxillary Nerve, Meckel's Ganglion, and Nerves of Nose	172
97.	Inferior Maxillary Nerve, Ganglia of Fifth Nerve and Tympanic Plexus	173
98.	Nerves of Submaxillary Region	176
99.	Cervical Plexus	177
100.	Brachial Plexus, Diagram A	178
101.	Brachial Plexus, Diagram B	179
102.	Lumbar Plexus	180
103.	Anterior Crural Nerve and Obturator Nerves	181
104.	Sacral Plexus	184
105.	Nerves over Ischial Spine and Plantar Nerves	185

ADDENDA.

RADIAL AND POSTERIOR INTEROSSEOUS NERVES * (terminal branches of Musculo-spiral Nerve).

Radial	passes down outer side of Forearm in front under cover of the Supinator Longus.	
Post. Interosseous	,, ,, to back ,, ,, through the fibres ,, ,, Brevis.	
Radial	supplies	*Skin* on outer side of back of Hand and dorsal aspect of 3½ outer Fingers.
Post. Interosseous	,,	*Muscles* of the whole ,, ,, ,, Forearm, except those supplied by Musculo-spiral. *Joints* of Carpus by ganglionic terminal branches.

* Omitted on page 180.

ERRATA.

PAGE	LINE	
11	7	*For* "Supercilli" *read* "Supercilii."
12	15	*For* "Sterno-mastoid" *read* "Mastoid."
19	4	*For* "Frontal" *read* "Frontal with Nasal."
27	13	*Insert a comma between* "behind" *and* "Triceps."
36	2	*For* "in childhood" *read* "after childhood."
41	13	*After* "External Lateral Ligament" *add* "Ankle."
41	20	*For* "upper and outer" *read* "upper and inner."
44	5	*For* "each transverse process" *read* "transverse processes."
45	15	*For* "**2nd to 3rd**" *read* "23rd."
56	15	*For* "Trapezoid" *read* "Trapezium."
59	7	*For* "**3rd** Lumbar V." *read* "5th."
71, 72	Title	*For* "Temporo-maxillary" *read* "Pterygo-maxillary."
83	9	*After* "Semispinalis" *add* "Colli."
91	2	*For* "⅔" *read* "½" in each case.
101	6	*For insertion of* "Adductor Magnus" *see Diagram of Femur.*
104	13, 14	Transpose "*first*" and "*last.*"
106		*Transpose insertions of* "Abductor" *and* "Adductor Pollicis."

PAGE	LINE	
109	16, 18	*For* "Biceps" *read* "Triceps.
129	8	*For* "Sup. Ext. Artic. Art." *read* "Sup. Artic. Arts.
176, last line,		*For* "Thyro-hyoid" *read* "Sterno-hyoid."
178	24	*For* "Suprascuplar" *read* "Suprascapular."

Plates.

Base of Skull, *For* "e Palatine Foramina" *read* "d and d′ Palatine Foramina.
Muscles of Hand, opp. p. 99, *Transpose numbers* "14" *and* "16" in Plate.
Psoas Magnus, etc., *Read* "3 — ,, lower ,, ."
Muscles in relation with Neck of Femur, *Transpose* "a" *and* "b" in Plate.
,, ,, ,, ,, ,, ,, *For* "2—Semimembranosus" *read* "2—Semitendinosus."
Section at middle third of Leg, opp. p. 105, *Transpose* "5" and "6."

BONES.

BODIES.

Structure — Like that of short bones,—Cancelli increase in size from above downwards.

Size — Increases from above down.

Form.
- *Cervical*,—quadrilateral, broadened transversely, as line of centre of gravity falls within them.
- *Lumbar*,— oval, ,, transversely, ,, ,, ,, ,, within ,,
- *Dorsal*, —heart-shaped, ,, antero-posteriorly, ,, ,, ,, ,, in front of them.

Surfaces.

Upper.
- *Cervical*,—bevelled in front, lipped at sides and behind, to limit movement.
- *Lumbar*,—slightly concave opposite centre of Intervertebral Disc, to allow free movement.
- *Dorsal*, —flattened, movement being very limited.

Lower.
- *Cervical*,—obverse of upper.
- *Lumbar*,—similar to ,,
- *Dorsal*, — ,, ,, ,,

Lateral.
- *Cervical*,—flat.
- *Lumbar*,—much constricted.
- *Dorsal*, —slightly ,,

Anterior and Posterior.
- *Cervical*,—of equal depth, curve being formed by Intervertebral Discs.
- *Lumbar*,—anterior deeper than posterior, ,, ,, Bodies and Intervertebral Discs.
- *Dorsal*, —posterior deeper than anterior, ,, ,, Bodies chiefly.
- In the cervical the anterior surfaces are at a lower level than the posterior.
- In the dorsal and lumbar they are at the same level.

Special Points.
- *Cervical*,—side of Body bears anterior root of Transverse Process.
- *Lumbar*,— ,, ,, continued into margin of ,, ,,
- *Dorsal*, — ,, ,, bears facet for Rib.
- In all there are foramina for vessels on lateral and posterior surfaces.

PEDICLES.
- Increase in size from above downwards.
- *Cervical*,—run backwards and outwards, placed between roots of Transverse Processes.
- *Lumbar*,— ,, ,, directly, and carry Transverse Processes.
- *Dorsal*, — ,, ,, ,, lowest three bear facets for Ribs.

LAMINÆ.	*Cervical,*—thin, narrow, slender, not imbricated, to permit movement.							
	Lumbar,—short, broad, strong,	,,	,,	,,	,,	,,		
	Dorsal, —	,,	,,	,,	imbricated,	to protect spinal cord.		
SPINOUS PROCESSES.	*Cervical,*—	bifid	for muscular attachment,		short and horizontal	to permit movement.		
	Lumbar,—tubercular	,,	,,	,,	quadrilateral, horizontal	,,	,,	,,
	Dorsal, —	,,	,,	ligamentous	,,	prismoid, directed downwards and backwards to prevent movement.		
TRANSVERSE PROCESSES.	*Cervical,*—situated between Intervertebral Foramina, in front of Articular Processes.							
	Lumbar,—	,,	behind	,,	,,	,,	,,	
	Dorsal, —	,,	behind	,,	,,	behind	,,	
	Cervical,—short and slight, with 2 roots, bifid extremity,					directed outwards, forwards and downwards.		
	Lumbar,—long and slender, with 1 root,* bearing 2 tubercles,					,,	,,	
	Dorsal, —	,,	strong,	,,	† clubbed extremity,	,,	,,	backwards and upwards.
ARTICULAR PROCESSES (Sup.)	*Cervical,*—oval, flat, looking backwards and upwards, to permit flexion and extension.							
	Lumbar,—	,,	concave	,,	,,	inwards,	,,	,, ,,
	Dorsal, —	,,	flat,	,,	,,	outwards,	,,	rotation.
	The Inferior Processes are obverse of Superior, in the Lumbar region they are closer together than Superior.							
SPINAL FORAMEN.	*Cervical,*—large,		triangular, to allow free movement without injury to cord.					
	Lumbar,—medium-sized,		,,	,,	,,	,,	,,	
	Dorsal, —small		round, movement being limited.					
INTERVERTEBRAL FORAMEN.	*Cervical,*—formed chiefly by Pedicle of lower of the two Vertebræ which bound the Foramen.							
	Lumbar,—	,,	,,	,,	upper ,,	,,	,,	,, ,,
	Dorsal, —	,,	,,	,,	,, ,,	,,	,,	,, ,,

* Corresponding to anterior root of cervical Transverse Process.
† ,, posterior ,, ,, ,,

CERVICAL.

Atlas

- Anterior Arch
  - *Anterior surface*,—tubercle for Longus Colli.
  - *Posterior* ,, —facet ,, Odontoid Process.
- Posterior ,,
  - *Posterior* ,, —tubercle ,, Rectus Capitis Posticus Minor.
  - *Upper* ,, —groove ,, Vertebral Artery and 1st Cervical Nerve, close to Lateral Mass.
- Lateral Mass
  - *Inner edge* —tubercle for Transverse Ligament.
  - *Outer side* —Transverse Process.
  - The mass itself is wedge-shaped, base outwards, and is situated nearer front than back of the bone, hence
  - *Upper surface* —looks upwards, backwards, inwards ; is oval, and deeply concave.
  - *Under* ,, — ,, downwards ,, ,, ,, circular, and flattened.

Axis

- Under Surface — similar to typical Cervical Vertebra.
- Upper ,,
  - *Body* — is prolonged upwards as Odontoid Process.
  - *Articular facet* (sup.) — supported on lateral part of Body, Pedicle and root of Transverse Process. circular and flattened, looking upwards, forwards and outwards.
  - on Lamina behind Articular facet, is the Superior Intervertebral Groove.
- Special Points
  - *Body*.—Ridge on front for Longus Colli.
  - *Pedicles*.—Laminæ and Spinous Process are broad and strong.
- Odontoid Process
  - *above*, pointed for Check Ligament.
  - *below*, constricted for Transverse Ligament.
  - *in front* bearing facet for Atlas.
  - *behind* ,, ,, Transverse Ligament.

7th Cervical	Spinous Process	long, thick, not bifid, horizontal.	
1st ,,	Transverse ,,	,, large, ,, perforated by Vertebral Foramen.	
2nd ,,	,, ,,	short, small ,, ,, ,, ,,	
7th ,,	,, ,,	long, large ,, ,, ,, ,,	sometimes.

DORSAL.

9th	presents demi-facet for Rib on Body above, none below.
10th	,, whole ,, ,, Pedicle chiefly.
11th	,, ,, ,, ,, ,, ,, no facet on Transverse Process.
12th	,, ,, ,, ,, ,, ,, ,, ,, ,, ,, Inf. Articular Process like Lumbar.
1st	,, ,, ,, ,, Body above, demi-facet below : Body like Cervical.

LUMBAR.

4th Transverse Process directed upwards as well as outwards.

5th
- Body " " " " " much thicker in front than behind.
- Spinous Process small.
- Inferior Articular Processes more widely separated than Superior.

SACRUM.

Anterior Surface
- in centre —*5 Bodies* coalesced, separated by ridges.
- laterally —*5 Anterior Transverse Processes* coalesced, separated by grooves.
- intermediately —*5 Pedicles* distinct, separated by Anterior Sacral Foramina.

Posterior "
- in mid-line —*3 Spines* **1st** distinct, **2nd** and **3rd** united, **4th** and **5th** deficient.
- external to Spines —*3 Laminæ* **1st** " **2nd** " **3rd** " **4th** " **5th** "
- " " Laminæ —*5 Articular Processes* **1st** " **2nd** " **3rd** tubercular, **4th** and **5th** form [Cornua.
- " " Artic. Process —*4½ Post.-Sacral Foramina*
- " " Foramina —*5 Post.-Transverse Processes* **1st** attaching Ilio-lumbar Ligament, **2nd** and **3rd** Sacro-iliac Ligaments, **4th** and **5th** Sacro-sciatic Ligaments.

Lateral "
- upper end —formed by **1st** piece rough for Ilio-lumbar Ligament.
- Auricular Surface — " **2nd** & **3rd** pieces smooth for articulation with Ilium.
- lower part — " **4th** & **5th** " sharp for Sacro-sciatic Ligaments.

Muscles on Anterior Surface { Pyriformis, Coccygæus } on Posterior Surface { Erector Spinæ, Glutæus Maximus. }

Note that the parts of the 1st piece are distinct, that those of the 2nd are associated with those of the 3rd, and those of the 4th with those of the 5th.

COCCYX.

1st Piece
- Rudimentary *Body.*
- *Articular Processes* (Cornua) behind, joining Cornua of Sacrum to complete 5th Posterior Sacral Foramen.
- *Transverse* " at side, " 5th Sacral Transverse Processes " 5th Anterior " "

2nd, 3rd and 4th Pieces are blended, separated by ridges on back and front.

Muscles on Anterior Surface { Levator Ani, Coccygæus } on Posterior Surface { Sphincter Ani, Glutæus Maximus. }

Consists of four parts, each having two surfaces, and presents four borders and four angles.

Occipital Part (single)	External Surface	at about centre	External Occipital Protuberance.
		from Protuberance to Foramen Magnum	,, ,, Crest.
		,, ,, Lateral Angle	Superior Curved Line.
		,, Crest (mid-point) parallel to Superior Line	Inferior ,, ,,
	Internal ,,	at about centre	Internal Occipital Protuberance.
		from Protuberance to Foramen Magnum	,, ,, Crest.
		,, ,, Lateral Angle	Groove for Lateral Sinus.
		,, ,, Superior ,,	,, Superior Longitudinal Sinus.
Condyloid ,, (double)	External ,,	Condyle nearer front than back of Foramen Magnum	
		to inner side of Condyle	Tubercle for Check Ligaments.
		,, outer ,, ,,	Jugular Process for Rectus Lateralis.
		in front of ,,	Ant. Condyloid Foramen for 9th Nerve.
		at back of ,,	Post. ,, ,, for Emissary Vein.
	Internal ,,	on upper surface of Jugular Process	Groove for Lateral Sinus.
		in front ,, ,,	Jugular Notch.
		to inner side ,, ,,	Posterior Condyloid Foramen.
		on outer side of Foramen Magnum	Anterior ,, ,,
Basilar ,, (single)	External ,,	at mid-point	Pharyngeal Spine.
		in mid-line	Basilar Crest.
	Internal ,,	,, ,,	Groove for Medulla Oblongata.
		on lateral margin	,, Inferior Petrosal Sinus.

Muscles attached.

To Sup. Curved Line	To inner third or half	Trapezius,	covering back of Neck.
	,, outer ,, ,,	Occipito-Frontalis,	,, ,, Head.
	,, ,, end above	Sterno-mastoid,	passing to mid-line in front (Sternum).
	,, ,, ,, below	Splenius	,, ,, behind (Spine).
Between Curved Lines	,, inner side	Complexus	the chief extensor of the Head.
	,, outer ,,	Superior Oblique	,, rotator ,, ,,
On Basilar Process	next to mid-line	Rectus Capitis Anticus *Major.*	
	externally and behind	,, ,, ,, Minor.	
On Jugular Process		Rectus Capitis Lateralis.	
To Inf. Curved Line	externally	Rectus Capitis Posticus *Major.*	
	next to mid-line	,, ,, ,, Minor.	

Articulations.

By Superior Borders with Parietals,—by Inferior Borders with Temporals,—by Inferior Angle with Sphenoid.

Note correspondence of points on the External and Internal Surfaces of the Occipital Part and their symmetry on each of the Parts.

PARIETAL BONE.

On outer Surface { Parietal Eminence. Temporal Ridge. } **on inner Surface** { Depressions for Convolutions and Pacchionian Bodies. Grooves for Arteries of Dura Mater. }

Borders.

- *Anterior* (for Frontal) bevelled externally above, internally below.
- *Inferior* (,, { Sphenoid / Temporal }) ,, ,, in front, ,, behind
- *Superior* (,, opposite Parietal) and *Posterior* (for Occipital) dentated, not bevelled.

Angles.

- *Anterior-superior,* a right angle } marked internally by a groove for Superior Longitudinal Sinus.
- *Posterior* ,, an obtuse ,, }
- *Anterior-inferior,* an acute ,, ,, ,, ,, Middle Meningeal Artery.
- *Posterior* ,, a truncated ,, ,, ,, ,, Lateral Sinus.

OCCIPITAL BONE.

1.-Trapezius
2.-Occipito-frontalis
3.-Sterno-mastoid
4.-Splenius Capitis

5.-Rectus Cap. Post. Minor
6.-Rectus Cap. Post. Major
7.-Rectus Lateralis

8.-Rectus Cap. Ant Minor
9.-Rectus Cap. Ant. Major.

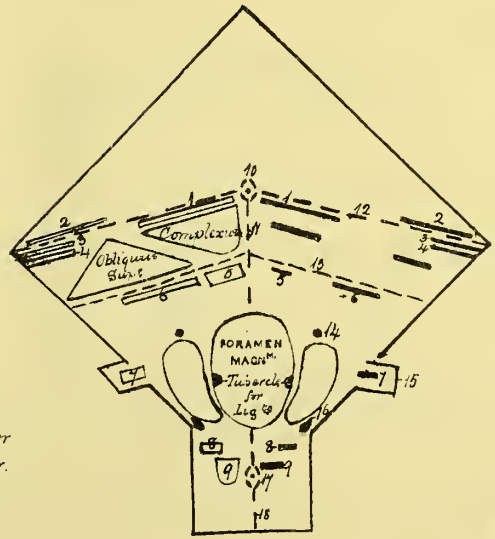

10-Ext Occipital Protuberance
11-Occipital Crest.
12-Sup.r Curved Line
13-Inf.r Curved Line.

14-Post. Condyloid Foramen
15-Jugular Process
16-Ant. Condyloid Foramen.

Pharyngeal Spine
Basilar Crest.

PARIETAL BONE.

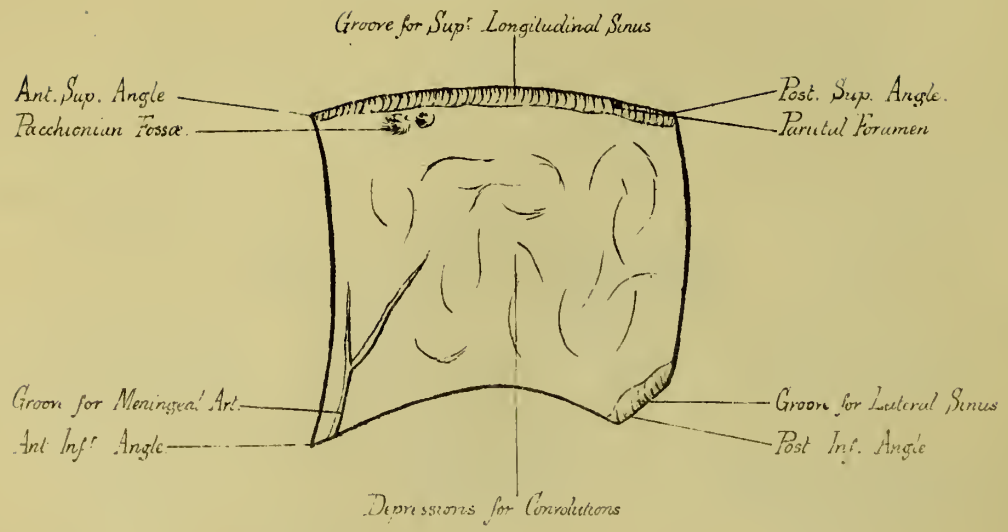

VERTICAL PORTION	**Outer surface**	4 Eminences	Frontal Eminence Superciliary Ridge	and Supra-orbital Arch. Temporal Ridge.
		2 Processes	External Angular, at outer end of Supra-orbital Arch. Internal „ inner „ „ „	
		2 Foramina, for	Supra-orbital Artery and Nerve on „ „ Frontal Vein from Diploe „ „ „	
		4 Muscular attachments	Corrugator Supercilli, Orbicularis Palpebrarum	Temporal. Occipito-frontalis.
	Inner „	2 Depressions	Groove for Superior Longitudinal Sinus in mid-line above. Foramen Cæcum „ below.	
		2 Prominences	Frontal Crest „ above Foramen Cæcum. „ Spine „ below „ „	
		Markings for	Arteries of Dura Mater. Convolutions of Brain and Pacchionian Bodies.	
HORIZONTAL PORTION	**Under** „	2 Depressions for	Lachrymal Gland, externally. Pulley of Superior Oblique, internally.	
	Upper „	Markings for	Convolutions. Vessels.	
	Edge of Ethmoidal Notch	4 Depressions	Opening of Frontal Sinus. Ethmoidal Cells. Anterior Ethmoidal Canal, for Anterior Ethmoidal Artery and Nasal Nerve. Posterior „ „ Posterior „	

Articulations.

Vertical Portion with	Parietal	*Orbital Plate* with	Malar on outer side Sphenoid „ „	and	Nasal on inner side. Superior Maxillary „ „ Lachrymal „ „ Ethmoid „ „

SQUAMOUS PART	Surfaces	*External*	Temporal Ridge	and Zygomatic Process.
		Internal	Grooves for Convolutions	„ Meningeal Artery.
		Inferior	Eminentia Articularis	„ Tubercle for Ligament.
			Glenoid Fossa	„ Glaserian Fissure.
	Borders	*Superior,*	bevelled internally	for Parietal.
		Anterior,	„ „	above and externally below for Sphenoid.
	Articulations	by *Superior Border*	with Parietal	by Glenoid Fossa with Inferior Maxilla.
		„ *Anterior* „	„ Sphenoid	„ Zygoma „ Malar.
MASTOID PART	Surfaces	*Outer*	Surface mark above for	Retrahens Aurem passing to Ear.
			Groove below „	Digastric „ Larynx.
			Surface intermediately „	Sterno-mastoid „ mid-line in front.
				Splenius „ „ behind.
				Trachelo-mastoid „ side of Spine.
		Inner	Groove for	Lateral Sinus.
			Orifice of	Sterno-mastoid Foramen.
	Borders	*Superior*	bevelled externally for	Parietal Bone.
		Posterior	serrated „	Occipital „
	Articulations	by Superior Border with Parietal Bone.		
		„ Posterior „ „ Occipital „		

TEMPORAL BONE.

EXTERNAL ASPECT.

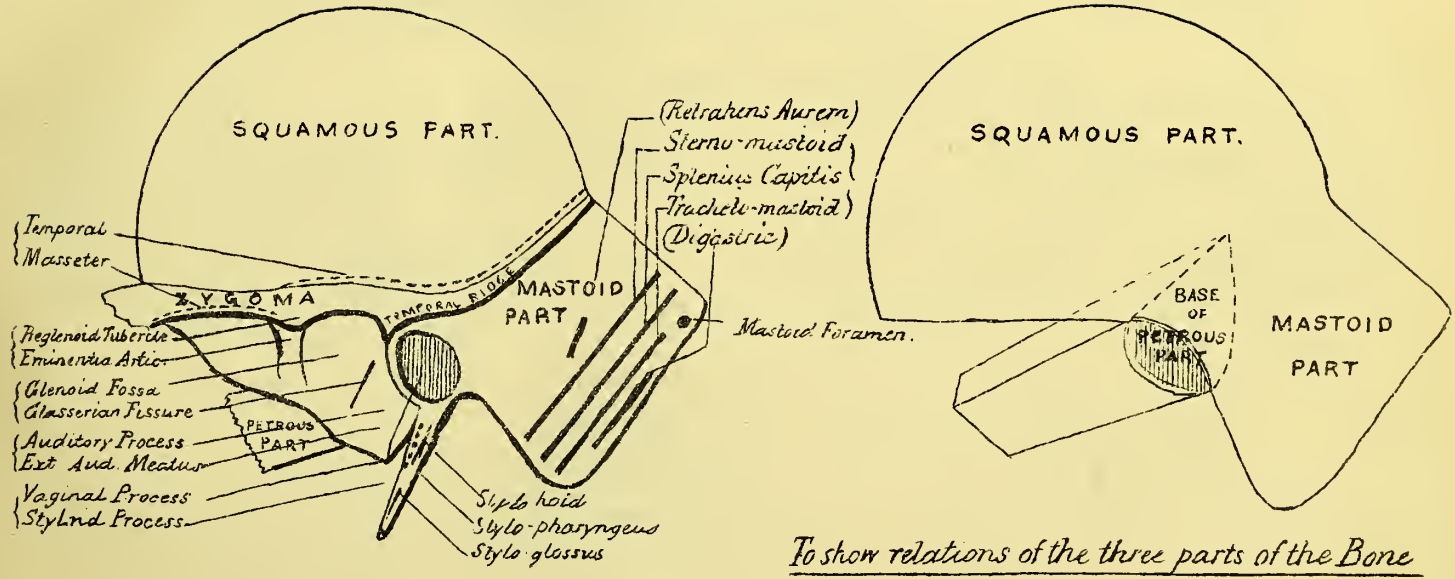

To show relations of the three parts of the Bone

PETROUS PART OF TEMPORAL BONE.

UPPER SURFACES.

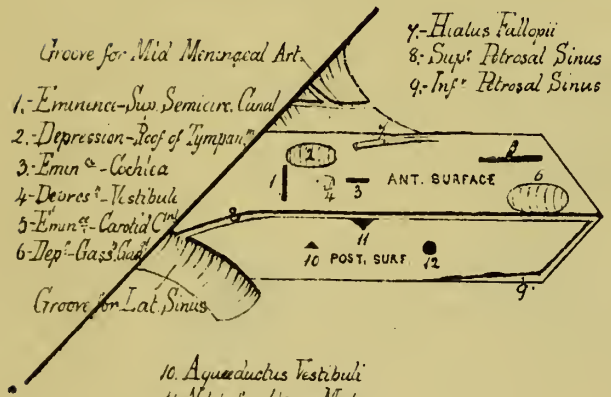

LOWER SURFACE.

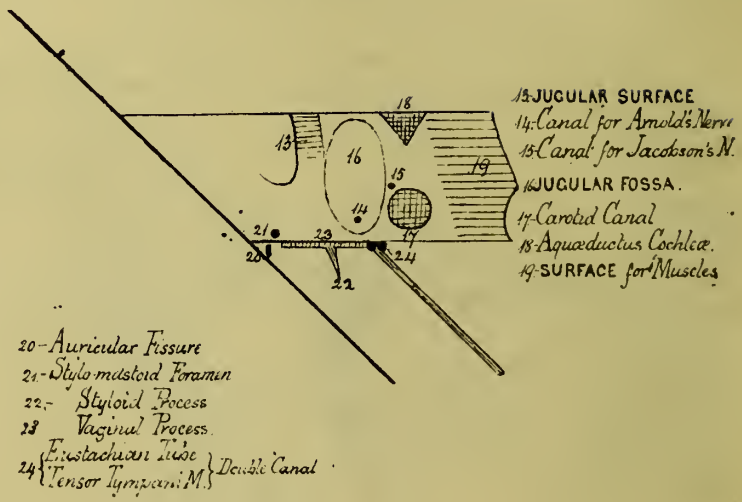

PETROUS PART

- **Base** — pierced by — External Auditory Meatus.
- **Apex** — „ „ — Carotid Canal.
- **Surfaces**
  - **Posterior** (3 points)
    - on same level — Aqueductus Vestibuli for Vein from Vestibule.
    - on same level — Internal Auditory Meatus for { 7th Nerve. Auditory Art.
    - above intermediately — Notch for attachment of Dura Mater.
  - **Anterior** (6 points) { 3 Depressions (D) & 3 Elevations (E).
    - externally and behind, Roof of Tympanum (D), with Ridge for Sup. Semicirc. Canal (E) int. to it.
    - in front of Sup. Canal, „ Vestibule (D), „ „ „ Cochlea (E) anterior to it.
    - int. and in front, Fossa for Gasserian Ganglion (D) with Roof of Carotid Canal (E) ext. to it.
  - **Inferior** (12 points)
    - near apex, *quadrilateral surface*, rough for — Tensor Tympani and Levator Palati.
    - „ base, „ „ smooth — (Jugular Surface) for Artic. with Occipital.
    - intermediately, *oval depression*, large „ — (Jugular Fossa) for Lateral Sinus, etc.
    - in front of Jugular Fossa, *two canals* — Carotid Canal for Carotid Artery.
    - in front of Jugular Fossa, *two canals* — Aqueductus Cochleæ for Vein from Cochlea.
    - within „ „ „ — for Jacobson's Nerve on ant. border of Fossa.
    - within „ „ „ — „ Arnold's „ at outer side „
    - near anterior end of outer border a *double orifice* — Canal for Eustachian Tube.
    - near anterior end of outer border a *double orifice* — „ Tensor Tympani.
    - „ posterior „ „ *two orifices* — Stylo-mastoid Foramen for Facial Nerve.
    - „ posterior „ „ *two orifices* — Auricular Fissure „ Arnold's „
    - along mid-part „ „ *two processes* — Styloid Process.
    - along mid-part „ „ *two processes* — Vaginal „
- **Borders**
  - *Superior* presents — Groove for Superior Petrosal Sinus.
  - *Posterior* „ — ½ „ Inferior „ „ [Suture.
  - *Anterior* „ — Hiatus Fallopii internal to Squamo-petrosal
- **Articulations**
  - by *Posterior Border* with — Occipital Bone.
  - „ *Anterior* „ „ — Sphenoid „

BODY	Cuboidal in form, presenting six Surfaces :—		
Superior Surface	*Anterior Part* (quadrilateral plate)	*Two* Depressions and *One* Eminence	Groove for Olfactory Nerve. „ „ Optic „ Olivary Eminence.
	Middle Part (deep depression)	„ „ „ „	Sella Turcica. Groove for Cavernous Sinus. Middle Clinoid Process.
	Posterior Part (quadrilateral plate)	„ „ „ „	Notch for Sixth Nerve. Groove for Pons Varolii. Posterior Clinoid Process.
Anterior „		*One* Depression and *Two* Eminences	Ethmoidal Spine. Lamella for Vertical Plate of Ethmoid. Opening of Spheuoidal Sinus.
Inferior „		„ „ „ „	Rostrum. Vaginal Process. Pterygo-palatine Canal.
Posterior „	Conjoined with		Basilar Process of Occipital Bone.
Lateral „	Prolonged into		Lesser Wing above and in front. Greater „ below „ behind.
GREATER WINGS	First run *horizontally* outwards, then curve *upwards*, forwards and outwards.		
Horizontal Portion	*Sup.* (*Cerebral*) *Surface* *Inf.* (*Zygomatic*) „	*Four* Foramina and *Two* Processes	*Pterygoid Process.* *Spinous* „ for Laxator Tympani. Int. Lateral Ligament. Foramen Rotundum for Sup. Maxillary Nerve „ Ovale „ Inf. „ „ „ Spinosum „ Great Meningeal Art. „ Vesalii „ Emissary Vein.

Vertical Portion

- *Posterior Surface* (Cerebral) — Grooves for Convolutions and Vessels.
- *External Surface* (Temporal) *one* Eminence and *two* Surfaces
  - Pterygoid Ridge.
  - Surface for Temporal Muscle above Ridge.
  - „ Ext. Pterygoid „ below „
- *Internal Surface* (Orbital) „ „ „ Depressions
  - Ext. Orbital Foramina for small vessels.
  - Notch for branch of Lachrymal Art. } on post. edge.
  - Spine „ outer head of Ext. Rectus } on post. edge.

LESSER WINGS connected with the Body by two Roots, having two Surfaces, superior and inferior,

and presenting *two* Eminences and *one* Depression
- Anterior Clinoid Process, behind.
- Tubercle for Orbital Muscles, on lower Root.
- Optic Foramen between Roots.

PTERYGOID PROCESS

Formed by **two Plates**
- united together by *anterior* margins to form posterior wall of — Spheno-maxillary Fossa.
- separated *behind* to form — Pterygoid Fossa.
- perforated at *base* by — Vidian Canal.
- split apart at *extremities* by notch for — Tuberosity of Palate Bone.

External Plate broad, directed backwards and outwards, attaching
- External Pterygoid on outer surface.
- Internal „ „ inner „

Internal „ narrow, „ „
- attaching
  - Tensor Palati „ outer „
  - Sup. Constrictor „ posterior border.
- presenting
  - Scaphoid Fossa at base.
  - Hamular Process „ extremity.

Anterior Surface of Body
- *articulates* with three Orbital Plates
  - Orbital Plate of Frontal by upper edge.
  - „ Process „ Ethmoid „ lateral „
  - „ „ „ Palate below.
  - (The Vertical Plate of Ethmoid articulating in mid-line.)
- is in *relation* with six Foramina
  - Opening of Sphenoidal Sinus centrally on [each side.
  - Optic Foramen } circumferentially on each side.
  - Foramen Lacerum Anterius } circumferentially on each side.
  - „ Rotundum } circumferentially on each side.
  - Ant. end of Vidian Canal } circumferentially on each side.
  - „ Pterygo-palatine Canal } circumferentially on each side.

SURFACES (4)

Superior (Orbital)	presents *one* Elevation and *one* Depression	Infraorbital Canal along mid-line. Lachrymal Tubercle on anterior border.
Posterior (Zygomatic)	„ „ „ *two* Depressions	Posterior Dental Canal at mid-point. Half of Posterior Palatine Canal on posterior border. Tuberosity of Superior Maxilla at posterior inferior angle.
Anterior (Facial)	„ „ „ *three* „	Incisive Fossa. Canine „ Opening of Infraorbital Canal. Canine Eminence.
Internal (Nasal)	„ „ „ *four* „	Opening of Antrum, centrally. Portion of Ethmoidal Cells, along upper edge. Lachrymal Groove near anterior border above. Maxillary Fissure „ posterior „ below. Inferior Turbinated Crest.

PROCESSES (4)

Alveolar	forming *lower* margin of Body	for Teeth.
Malar	situated *above* and to *outer* side	separating Facial and Zygomatic Surfaces.
Nasal	„ „ „ *inner* „ presenting	no mark in front. Lachrymal Groove behind. Superior Turbinated Crest / Anterior Ethmoidal Cells — on inner surface
Palatine*	„ along *inner* surface near *lower* border „	Maxillary Crest along inner edge. Anterior Nasal Spine at anterior end of „ „ Palatine Fossa „ „ under surface. Groove for Ant. Palatine Nerve on post. part of „ „

* Compare with horizontal plate of Palate Bone.

- **PLATES**
  - **Horizontal**
    - *inner edge* — raised to form — Crest for Vomer.
    - „ „ — prolonged backwards as — Posterior Nasal Spine.
    - *posterior* „ — marked by — „ Palatine Canal; Accessory „ Canals.
  - **Vertical**
    - *Internal Surface* — presents from below upwards — Inferior Meatus (part of); „ Turb. Crest for Inf. Turb. Bone; Middle Meatus (part of); Superior Turb. Crest for Mid. Turb. Bone; „ Meatus (part of)
    - *External* „ — below and in front smooth, above „ behind „ , — covering opening of Antrum behind, forming inner wall of Spheno-maxil. Fossa; intermediately rough, — articulating with Superior Maxilla, marked by Posterior Palatine Canal.
    - *Anterior border* — prolonged forward over Antrum as — Maxillary Process.
    - *Posterior* „ — „ back between Pterygoid Plates as — Pterygoid „ or Tuberosity.
- **PROCESSES**
  - **Sphenoidal** — a curved plate — directed upward and inward to under surface of body of Sphenoid.
  - **Orbital**
    - a hollow cube — „ „ „ outward to posterior inferior angle of Ethmoid, turned so that anterior surface looks downwards and outwards as well as forwards, and the other surfaces in corresponding directions.
    - with six Surfaces
      - *Inferior* — connected with — Vertical Plate of Palate.
      - *Sup.* or *Orbital* — forming — Floor of Orbit (back part).
      - *Ext.* „ *Zygomatic* — „ — Zygomatic Fossa (part of anterior wall).
      - *Ant.* „ *Maxillary* — articulating with — Superior Maxilla.
      - *Post.* „ *Sphenoidal* — „ „ — Anterior surface of Body of Sphenoid.
      - *Int.* „ *Ethmoidal* — „ „ — Lateral Mass of Ethmoid.

INFERIOR MAXILLA.

- **BODY** (12 points)
  - **Surfaces**
    - *External*
      - three Eminences
        - Ridge of Symphysis vertically in mid-line.
        - Mental Process at lower end of Symphysis.
        - Ext. Oblique Line from Mental Process to Ramus.
      - three Depressions
        - Incisive Fossa below Incisor Tooth.
        - Mental Foramen ,, second Bicuspid ,,
        - Groove for Facial Artery, at junction with Ramus.
    - *Internal*
      - three Eminences
        - Genio-hyoid Tubercle } behind Symphysis.
        - Genio-hyo-glossus ,, } behind Symphysis.
        - Int. Oblique Line from Symphysis to last Molar.
      - three Depressions
        - Digastric Fossa, near Symphysis, below Tubercles.
        - Sublingual ,, above Mylo-hyoid Ridge.
        - Submaxillary ,, below ,, ,,
- **RAMUS** (6 Points)
  - **Processes**
    - on upper border
      - Coronoid, grooved anteriorly for Temporal Muscle.
    - *each* with a *depression* in front of it
      - Condyloid, hollowed ,, ,, Ext. Pterygoid ,,
  - **Surfaces**
    - *Internal*, with *two Depressions*
      - Inferior Dental Foramen.
      - Mylo-hyoid Groove.
    - *External*, showing no special marking.

HYOID BONE.

- **Muscles attached**
  - On Body
    - *Four* Hyoid Muscles.
      - Genio-hyo-glossus to upper border of anterior surface.
      - Genio-hyoid ,, chief part ,, ,,
      - Mylo-hyoid ,, lower ,, ,, ,,
      - Sterno-hyoid ,, ,, border ,, ,,
  - At junction of Body and Great Cornu
    - *Three* ,, ,,
      - Stylo-hyoid.
      - Aponeurosis of Digastric above Stylo-hyoid.
      - Omo-hyoid below ,, ,,
  - On Great Cornu
    - *Two* ,, ,,
      - Hyo-glossus above, extending also to Body and Small Cornu.
      - Thyro-hyoid below
    - *One* Pharyngeal Muscle. Middle Constrictor, extending to Small Cornu along upper edge.

HYOID BONE AND INFERIOR MAXILLA.

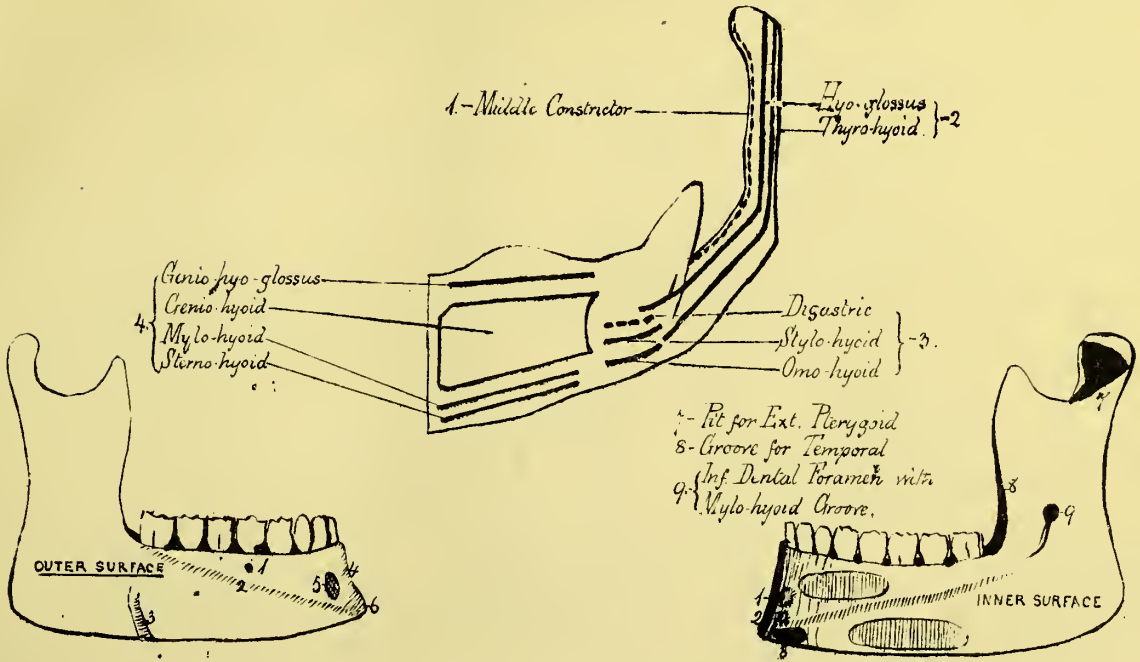

1.-Mental Foramen.
2-Ext. Oblique Line.
3-Groove for Facial Art.
4.-Symphysis
5.-Incisive Fossa.
6.-Mental Process

1-Genio-hyo-glossus Tubercle
2-Genio-hyoid Tubercle
3-Digastric Fossa.
4.-Sublingual Fossa.
5.-Mylo-hyoid Ridge.
6.-Submaxillary Fossa

BASE OF SKULL.

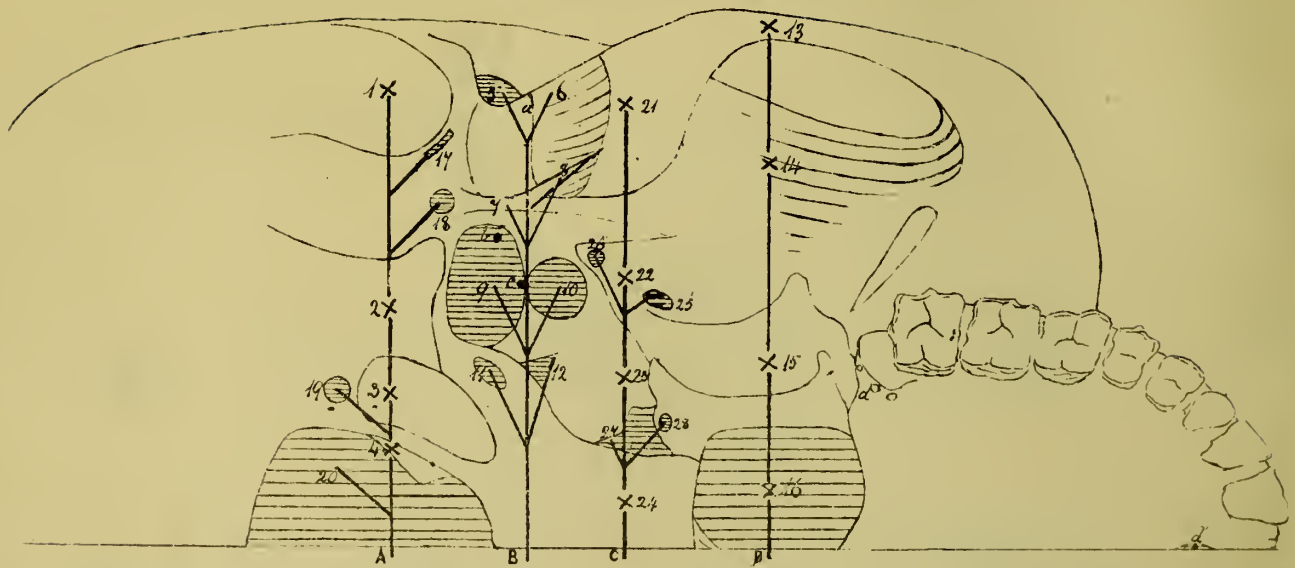

A
- 1.- Mastoid Process
- 2.- Jugular Process.
- 3.- Condyloid Process.
- 4.- Process for Check Ligts. with
- 17.- Auricular Fissure.
- 18.- Stylo-mastoid Foramen.
- 19.- Post. Condyloid Foramen
- 20.- Foramen Magnum.

B
- 5.- Ext. Auditory Meatus with 6.- Glenoid Fossa.
- 7.- Vaginal Process with 8.- Styloid Process.
- 9.- Jugular Fossa with 10.- Carotid Canal.
- 11.- Ant. Condyloid Foramen with 12.- Aquæductus Cochleæ.

C
- 21.- Eminentia Articularis
- 22.- Spine of Sphenoid
- 23.- Surf. for Tensor Tympani etc.
- 24.- Basular Process

D
- 13.- Zygomatic Process.
- 14.- Zygomatic Fossa.
- 15.- Pterygoid Process
- 16.- Nasal Fossa

25.- Foramen Ovale.
26.- Foramen Spinosum.
27.- Foramen Lacerum Medium.
28.- Opening of Vidian Canal.

a. Glaserian Fissure.
b. Canal for Arnold's N.
c. Canal for Jacobson's N
e. Palatine Foramina

Foramen Lacerum Anterius	(in Middle Fossa) transmits *six* Nerves, *two* Arteries and *one* Vein	Third Nerve. Fourth ,, Lachrymal ,, } of Ophthalmic Division of fifth Nerve. Frontal ,, Sixth ,, Sympathetic Root of Lenticular Ganglion. Orbital Branches of Middle Meningeal Art. Recurrent Branch of Lachrymal ,, Ophthalmic Vein.
Foramen Lacerum Medium	,, ,, ,, *three* ,, ,, ,, ,,	Vidian Nerve. Carotid Division } of Sympathetic. Cavernous ,, Carotid Artery. Meningeal Branch of Ascending Pharyngeal Artery. Emissary Vein from Cavernous or Petrosal Sinus.
Foramen Lacerum Posterius	(in Posterior ,,) ,, ,, ,, *one* Artery and *two* Veins	Glosso-pharyngeal Nerve. Pneumogastric ,, Spinal Accessory ,, Meningeal Branch from Occipital Artery. Lateral Sinus } terminal portions. Inferior Petrosal Sinus
Foramen Magnum	,, ,, ,, Spinal Cord and *one* pair of Nerves *four* pairs of Arteries and *one* pair of Veins	Spinal Cord. Right and Left Spinal Accessory Nerves. ,, ,, Vertebral Arteries. ,, ,, Meningeal Branches of Vertebral Arteries. Right and Left Anterior Spinal Branches of Vertebral Arteries. Right and Left Posterior Spinal Branches of Vertebral Arteries. Right and Left Spinal Plexus of Veins.

Foramina of Cranium—*continued.*

Lamina Cribriformis	(in Anterior Fossa) transmits *two* Nerves and *two* Arteries	Olfactory Nerve. Nasal ,, Anterior Ethmoidal Artery. Posterior ,, ,,
Foramen Opticum	,, ,, ,, ,, ,, *one* Artery.	Optic Nerve. Sympathetic on Ophthalmic Artery. Ophthalmic Artery.
,, **Ovale**	(in Middle ,,) ,, ,, ,, ,,	Inferior Maxillary Nerve. Small Petrosal ,, ,, Meningeal Artery.
Meatus Auditorius Internus	(in Posterior ,,) ,, ,, ,, ,,	Facial Nerve. Auditory ,, ,, Branch of Basilar Artery.
Hiatus Fallopii	(in Middle ,,) ,, *one* Nerve ,, ,,	Great Superficial Petrosal Nerve. Branch of Great Meningeal Artery to Ear.
Foramen Spinosum	,, ,, ,, ,, ,, ,,	Sympathetic twigs on Great Meningeal Artery. Great Meningeal Artery.
,, **Rotundum**	,, ,, ,, ,,	Superior Maxillary Nerve.
,, **Condyloid. Anterius**	(in Posterior ,,) ,, ,,	Hypoglossal Nerve.

Foramina for Emissary Veins.

One in each Bone of the Cranium, except Ethmoid.

In **Frontal,** —*Foramen Cæcum,* for Emissary Vein to Nose ,, **Parietal,** —*Parietal Foramen,* ,, ,, ,, join Occipital Vein	opening into Superior Longitudinal Sinus.	
,, **Occipital,** —*Post. Condyloid* ,, ,, ,, ,, ,, ,, ,, **Temporal,**—*Mastoid* ,, ,, ,, ,, ,, ,,	,, ,, Lateral ,,	
,, **Sphenoid,** —*Foramen of Vesalius,* ,, ,, ,, ,, Pterygoid Veins ,, ,, —*Sphenoidal Fissure,* for Ophthalmic Vein	,, ,, Cavernous ,,	

FORAMINA ON ANTERIOR SURFACE OF SPHENOID. —

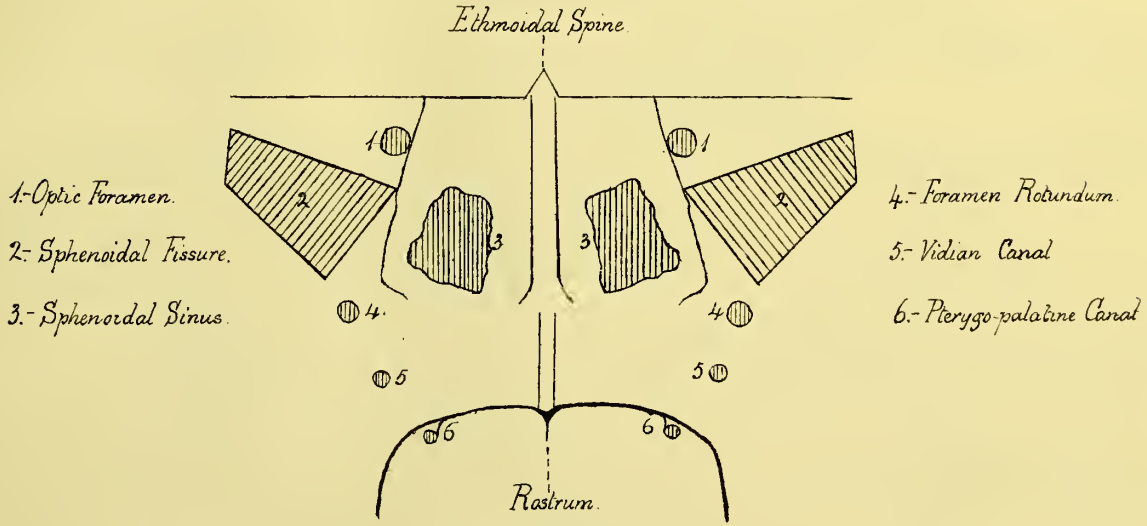

ORBITAL FOSSA.

BONES.

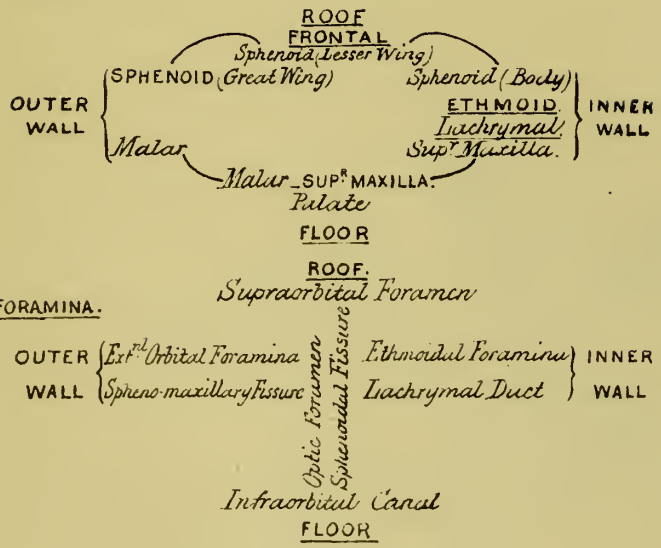

NASAL FOSSA.

BONES.

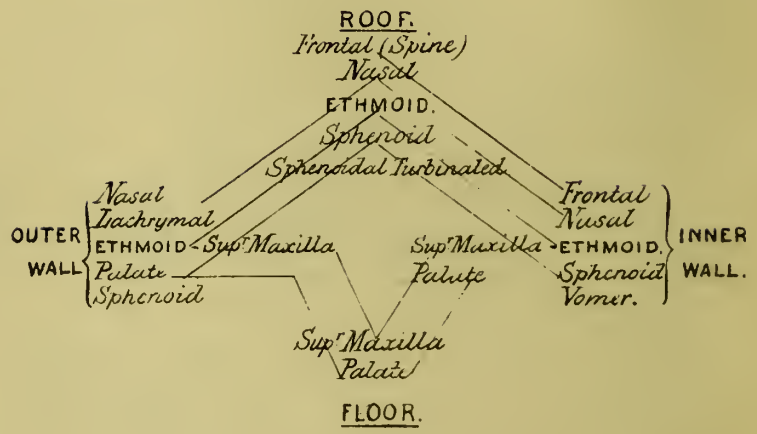

ORBITAL FOSSA.

Two **Bones** form the Roof, *two* the Outer Wall, *three* the Floor, and *four* the Inner Wall.

The Frontal	forms part of	Roof only.	
„ Palate	„ „	Floor only.	
„ Lachrymal, „ Ethmoid	form „	Inner Wall only.	
„ Superior Maxilla	forms „	„	and Floor.
„ Malar	„ „	Outer Wall „	„
„ Sphenoid	„ „	„ „	Roof and Inner Wall.

Foramina, etc.

- in Roof — Supraorbital Foramen
- „ Floor — Infraorbital Canal
- in Outer Wall — External Orbital Foramina. Spheno-maxillary Fissure.
- in Inner „ — Ethmoidal Foramina. Lachrymal Canal.

NASAL FOSSA.

Five **Bones** form the Roof, *six* the Outer Wall, *seven* the Inner Wall, and *two* the Floor.

The Vomer	forms part of	the Inner Wall only.			
„ Lachrymal	„ „	Outer	„	„	
„ Sphenoidal Turbinated	„ „	Roof	„		
„ Frontal	„ „	„	and Inner Wall.		
„ Nasal, „ Ethmoid, „ Sphenoid, „ Superior Maxilla, „ Palate	form „	„	„	„	and Outer Wall.
	„ „	Floor	„	„	„ „

Foramina, etc.

- in Floor — Anterior Palatine Foramina.
- „ Roof — Foramina in Cribriform Plate.
- in Outer Wall
  - in Sup. Meatus (which is of one-third the length of Outer Wall) *three* — Orifice of Sphenoidal Sinus. „ Post. Ethmoid Cells. Spheno-palatine Foramen.
  - „ Middle „ („ two-thirds „ „ „) *two* — Orifice of Antrum. „ Infundibulum.
  - „ Inferior „ („ nearly the same length as „ „) *one* — „ Lachrymal Canal.

Compare with Diagram.

A Rib consists of
- a Posterior Extremity, comprising a Head, Neck and Tuberosity.
- an Anterior „
- a Shaft,

and presents two Surfaces, two Borders and five Curves.

Curves
- A short curve corresponding to the Posterior Extremity.
- A long „ „ „ Shaft.
- An upward „ „ „ Posterior Extremity.
- A downward „ „ „ Anterior „
- A twist of the Bone upon its own axis, the outer surface looking upwards in front, and downwards behind.

The junction of the short and long curves is indicated on the outer surface by a ridge,—the *Posterior Angle.*

The same point marks the beginning of the upward Curve, and is the point round which the bone is twisted.

The junction of the downward curve with the shaft is indicated by the *Anterior Angle.*

The first Rib has only one curve, its Posterior Angle coinciding with its Tubercle.

The last „ „ „ „ falling upon its Anterior Extremity.

The Curves and Angles are all most marked in the seventh Rib, thence upwards and downwards becoming less distinct.

The distance between the Posterior Angle and the Tubercle increases from above downwards.

The Posterior Extremities (Heads and Necks) increase in size from above down, being small and rounded in the upper, large and flattened in the lower Ribs.

The Anterior Extremities and Tubercles diminish in size from above down, being largest in the first Rib.

The Tubercle consists of an articular and a non-articular portion,

the articular portion in the upper Ribs is oval with the long diameter transverse, and is convex,

„ „ „ lower „ „ „ „ vertical „ flat.

In the eleventh and twelfth Ribs the Tubercle is wanting.

The Intercostal Groove narrows from above down, being indistinguishable from its breadth in the first Rib, and being obliterated in the last Rib.

This table refers only to the general characteristics of the Ribs.

STERNUM.

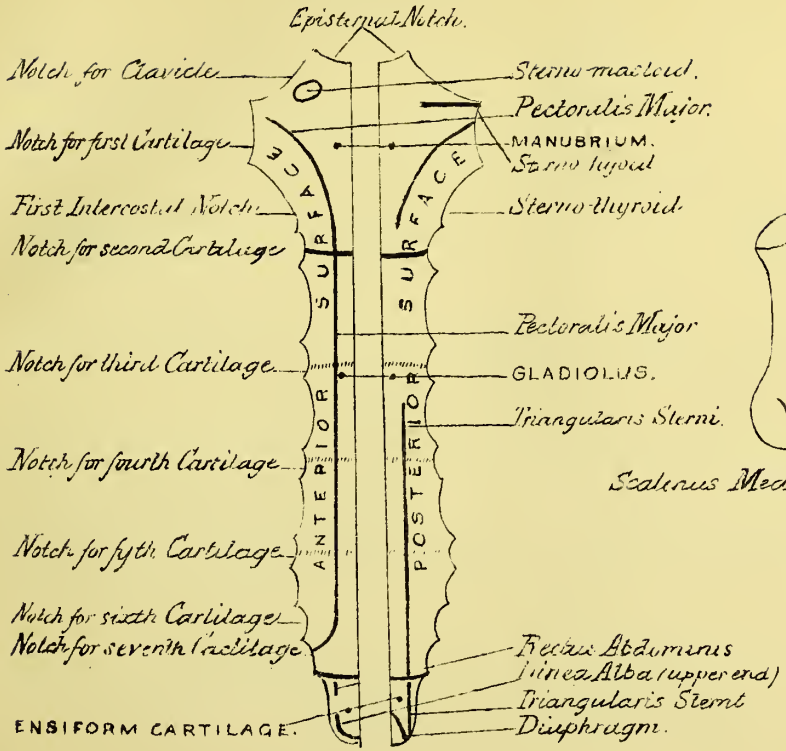

FIRST RIB.

UPPER SURFACE.

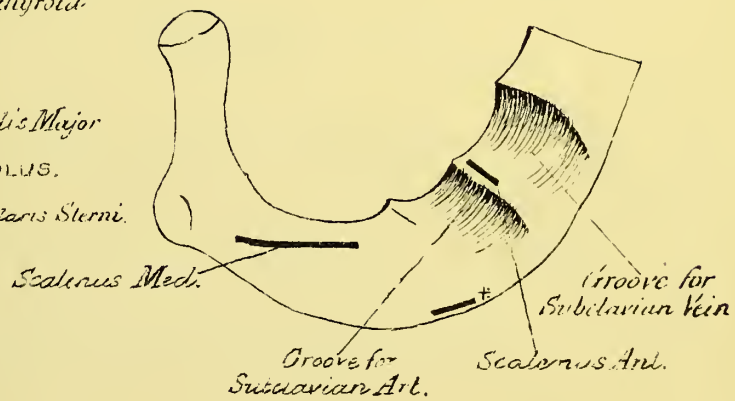

Shaft.

Outer third	flattened, presenting two Surfaces	superior / inferior	and two Borders: anterior. / posterior.
Inner two-thirds	prismatic, „ three „	anterior / posterior / inferior	„ three „: anterior. / posterior. / superior.

The Anterior Border of the outer part is continued into the Anterior Border of the inner, and presents the Deltoid Tubercle.
„ Posterior „ „ „ divides „ Post. and Sup. Borders „ „ , Conoid „

„ Anterior Surface of the inner part is convex, and is continuous with the Superior Surface of the outer part.
„ Posterior „ „ „ flat , „ „ Posterior Border „ „
„ Inferior „ „ „ concave „ „ „ Inferior Surface „ „

Attachment of Muscles, etc.

To outer third of Bone in front, *Muscles*— Trapezius / Deltoid to inner third in front, *Muscles*— Sterno-mastoid / Pectoralis Major to middle third in front— Integuments.

On „ „ „ behind, *Ligament*—Conoid on „ „ behind, *Muscle*— Sterno-hyoid in middle third behind— Nutrient Foramen.

„ „ „ „ below, *Ligament*—Trapezoid „ „ „ below, *Ligament*,— Rhomboid to middle third below— Subclavius.

The Inner Extremity (Sternal) is triangular, with concavo-convex articular facet over lower part, prolonged round lower border.

The Outer Extremity (Acromial) is oval, „ flat „ „ limited to Extremity.

The Inner Extremity looks inwards, the Outer outwards, both look forwards and downwards.

SCAPULA.

Consists of a Body, having two Surfaces, three Borders, three Angles and three Processes.

- **Surfaces**
  - *Anterior* presents — Subscapular Fossa, from posterior two-thirds of which arises the Subscapularis.
  - *Posterior* „ —
    - Supraspinous „ „ „ „ „ „ „ Supraspinatus.
    - Infraspinous „ „ „ „ „ „ „ Infraspinatus.
- **Borders**
  - *Superior* — shortest and thinnest, presenting Scapular Notch, attaching part of Omo-hyoid.
  - *Posterior* — longest, attaching
    - Levator Anguli Scapulæ.
    - Rhomboideus Major and by anterior lip Serratus Magnus.
    - „ Minor.
  - *External* — thickest, „
    - Triceps (long head).
    - Teres Major and by post. lip below, Latissimus Dorsi.
    - „ Minor.
- **Angles** — *Superior, Inferior* and *Anterior,* the last supporting the Glenoid Fossa.
- **Processes**
  - *Spine*, a triangular plate
    - with apex at Posterior Border of Scapula, and base behind Glenoid Fossa.
    - projecting up and back from Posterior Surface of Scapula.
    - attaching
      - by upper surface Supraspinatus, by upper Border Trapezius.
      - „ lower „ Infraspinatus, „ lower „ Deltoid.
    - continued externally into Acromion Process.
  - *Acromion Process*
    - directed from outer end of Spine, first outwards, then upwards and forwards.
    - attaching
      - by inner border Trapezius, by tip Coraco-acromial Ligament.
      - „ outer „ Deltoid, by inner margin Acromio-clavicular „
  - *Coracoid Process*
    - directed from outer end of Sup. Border of Scapula, first upwards, then outwards and forwards.
    - attaching
      - round upper surface
        - three muscles
          - by tip — Coraco-brachialis.
          - „ „ — Biceps (short head).
          - „ ant. border (outer half) — Pectoralis Minor.
        - three ligaments
          - „ „ (inner half) — Trapezoid.
          - „ inner side of root — Conoid.
          - „ posterior border — Coraco-acromial.
      - by root
        - on inner side, Scapular Ligament, with Omo-hyoid in connection with it.
        - „ outer „ Coraco-humeral „ „ Biceps (long head) below it.

CLAVICLE.

ANTERIOR SURFACE.



INFERIOR SURFACE.

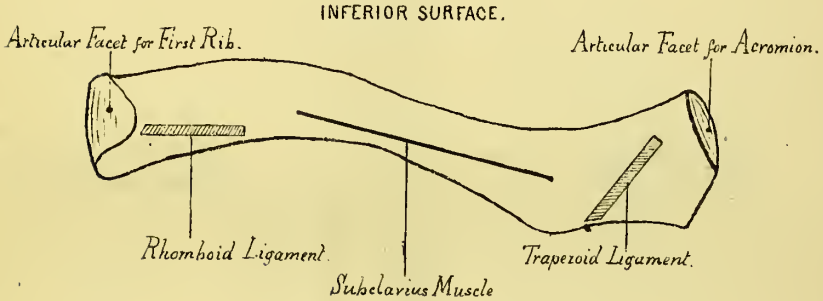

POSTERIOR SURFACE.



HUMERUS

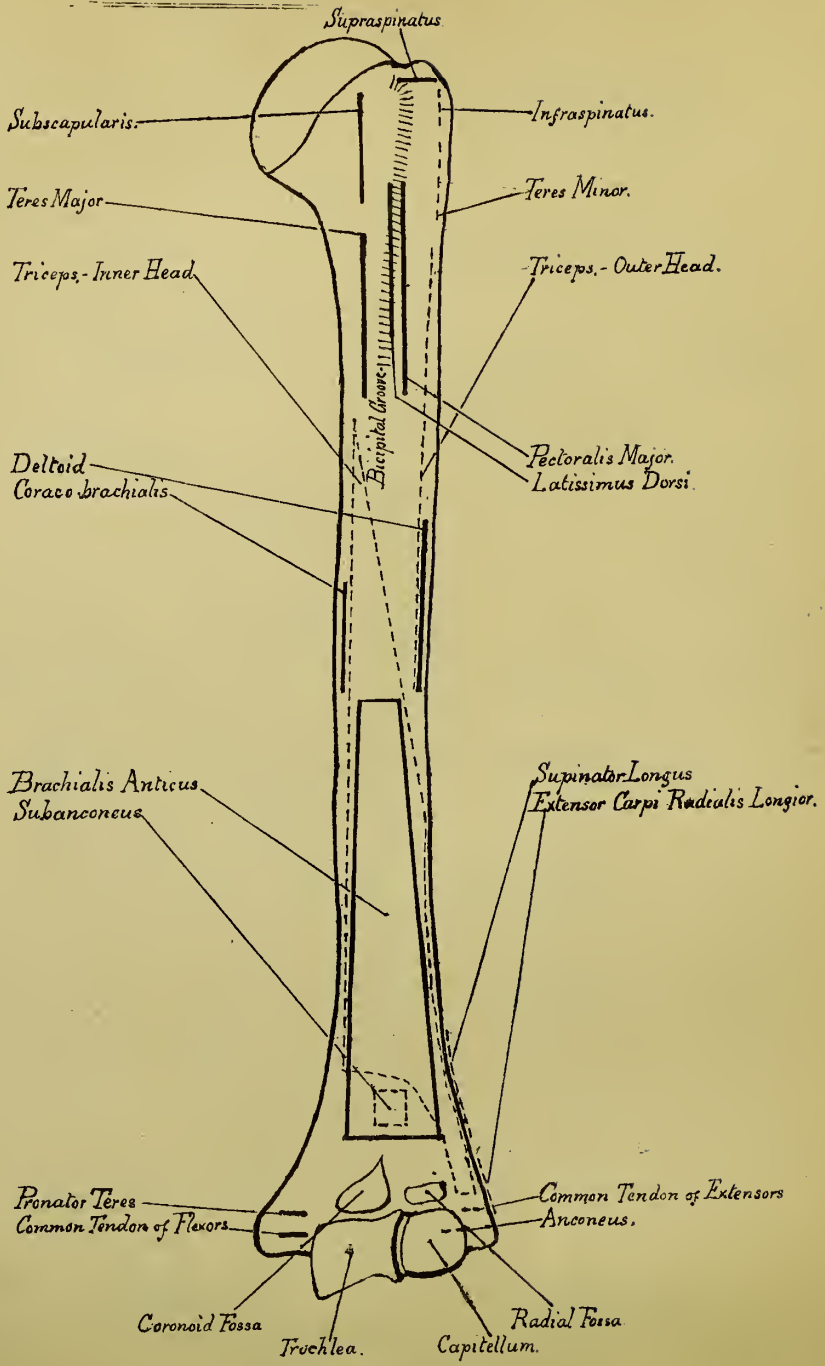

N.B. The dotted lines represent the positions of Muscles which are on the posterior surface of the Bone.

UPPER EXTREMITY.

Head		hemispherical, directed inwards and also upwards and backwards.
Necks,	*Anatomical,*	a groove separating Head and Tuberosities.
	Surgical,	immediately below „ „ „
Tuberosities	*Great*	on outer side of Extremity, square, with 3 facets for Supraspinatus. Infraspinatus. Teres Minor.
	Small	in front ,, ,, pyramidal, „ 1 facet ,, Subscapularis.

LOWER EXTREMITY.

Articular Surfaces	*Capitellum,*	to outer side and in front, convex, looking forwards, for Radius in flexion.
	Trochlea,	,, inner ,, in front and behind, concavo-convex, directed from behind forwards and inwards, for Ulna.
Fossæ	*Coronoid F.,*	in front, above Trochlea, deep, for Coronoid Process in flexion.
	Olecranon F.,	behind, ,, ,, ,, ,, Olecranon „ extension.
	Radial F.,	in front, ,, Capitellum, shallow, ,, Head of Radius in flexion.
Condyles	*Internal,*	prominent, projecting on inner side of Trochlea, attaching Flexors of Forearm and Int. Lat. Ligament.
	External,	flattened, situated behind Capitellum „ Extensors ,, ,, Ext. ,, ,,

SHAFT.

Borders	*Anterior,*	from front of Great Tuberosity to Coronoid Fossa.
	External,	,, back ,, ,, ,, External Condyle.
	Internal,	,, below Small ,, ,, Internal ,,
Surfaces	*External,*	looking outwards above, outwards and forwards below, marked by Bicipital Groove.
	Internal,	,, forwards ,, forwards and inwards ,, ,, Nutrient Foramen.
	Posterior,	,, back and in ,, back and out ,, ,, Musculo-spiral Groove.

MUSCLES ATTACHED.

On posterior Surface	below Musculo-spiral Groove						Triceps, Inner Head.
	above ,, ,, ,,						,, Outer ,,
Above Inner Head of Triceps,	below	Small	Tuberosity	(to inner lip of Bicipital Groove)			Teres Major.
,, Outer ,, ,, ,,		Great	,,	(to lowest facet and bone below)			,, Minor.
,, Teres Major	to	Small	,,	(and bone below)			Subscapularis.
,, ,, Minor	,,	Great	,,	(to middle facet)			Infraspinatus.
Intermediately	,,	,,	,,	(,, highest ,,)			Supraspinatus.
In front of	Humerus, to lower half of Ext. and Int. Surfaces, connected with Anterior Ligament of Elbow						Brachialis Anticus.
Behind	,, at lower end of Posterior Surface			,, ,, Posterior ,, ,, ,,			Subanconeus.
To outer side of	,,	,, middle of	External	,,	over triangular impression		Deltoid.
,, inner ,,	,,	,, ,,	Internal	,,	along linear ,,		Coraco-brachialis.
In front of	,,	to outer lip of	Bicipital Groove				Pectoralis Major.
,,	,,	,, floor of	,,	,,			Latissimus Dorsi.
To External Condyle,	at back,						Anconeus and Extensors of Hand.
,, Internal ,,	in front,						Pronator Teres and Flexors of Hand.
,, External Supracondyloid Ridge	to upper two-thirds,						Supinator Longus.
	to lower third,						Extensor Carpi Radialis Longior.

UPPER EXTREMITY (having two Processes and two Cavities).

- **Olecranon Process**, quadrilateral, with
  - *posterior surface*, triangular and subcutaneous.
  - *anterior* ,, concave, smooth, forming upper part of Great Sigmoid Cavity.
  - *superior* ,, square and flat, for Triceps behind and Bursa in front.
  - *lateral surfaces* flattened, for muscular attachments.
- **Coronoid Process**, wedge-shaped, with
  - *upper surface*, concave, smooth, forming lower part of Great Sigmoid Cavity.
  - *under* ,, ,, rough for muscles, continued into Tubercle.
  - *external* ,, presents Lesser Sigmoid Cavity.
  - *internal* ,, ridged for muscular attachments.

- **Greater Sigmoid Cavity**, concave from above down, divided by
  - vertical ridge into
    - larger inner part, concave.
    - smaller outer part, flat.
  - transverse notch into upper and lower parts.
- **Lesser** ,, ,, ,, ,, before back, narrow and oblong.

Muscles attached

To under surface of	Coronoid Process,	below,	Brachialis Anticus,	Flexor of Forearm.
,, upper ,, ,,	Olecranon ,,	behind	Triceps,	Extensor ,,
,, outer side of	,, ,,		Anconeus,	,, ,,
,, inner ,,	,, ,,		Flexor Profundus Digitorum,	Flexor of Fingers.
,, ridge on inner side of	Coronoid ,,		Pronator Teres,	Rotator in of Forearm.
,, depression on outer side of	,, ,,		Supinator Brevis,	,, out ,,
,, tubercle on inner ,,	,, ,,	above,	Flexor Sublimis Digitorum,	Flexor of Fingers.
,, impression on under surface	,, ,,	below,	Flexor Longus Pollicis,	,, Thumb.

LOWER EXTREMITY (having two Processes and two Depressions).

Head,	rounded, convex, articular, for { Triangular Cartilage below. Sigmoid Cavity of Radius externally.
Styloid Process,	situated at posterior and inner side of Head, attaching Internal Lateral Ligament of Wrist
Depression,	between Head and Styloid Process, for attachment of Triangular Cartilage.
Groove,	on back of Head, ,, tendon ,, Extensor Carpi Ulnaris.

SHAFT convex behind and externally, prismatic above, rounded below, tapering from above down.

Borders

Anterior,	extending from inner angle of Coronoid Process to front of Styloid Process.
Posterior,	,, ,, lower ,, Olecranon ,, back ,, ,,
Ext. (*or Interosseous*)	,, ,, outer side of Coronoid ,, middle of Head.

The *Oblique Line* on posterior surface runs from Lesser Sigmoid Cavity to posterior border of Ulna.
,, *Vertical* ,, ,, ,, ,, down from middle of Oblique Line.

Surfaces

Anterior, concave, attaching	{ Brachialis Anticus (where continued into Coronoid Process). Flexor Profundus Digitorum (to upper three-fourths). Pronator Quadratus (to lower fourth).
Internal, convex, ,, (*with Post. Border*)	{ Flexor Profundus Digitorum (to upper three-fourths and posterior border). ,, Carpi Ulnaris (to upper three-fourths, posterior border only). Extensor ,, ,, (,, ,, ,, ,, ,,). Lower fourth is subcutaneous.
Posterior, flattened ,,	{ Extensor Ossis Metacarpi Pollicis, ,, Secundi Internodii ,, ,, Indicis, } overlapping each other.

ULNA.

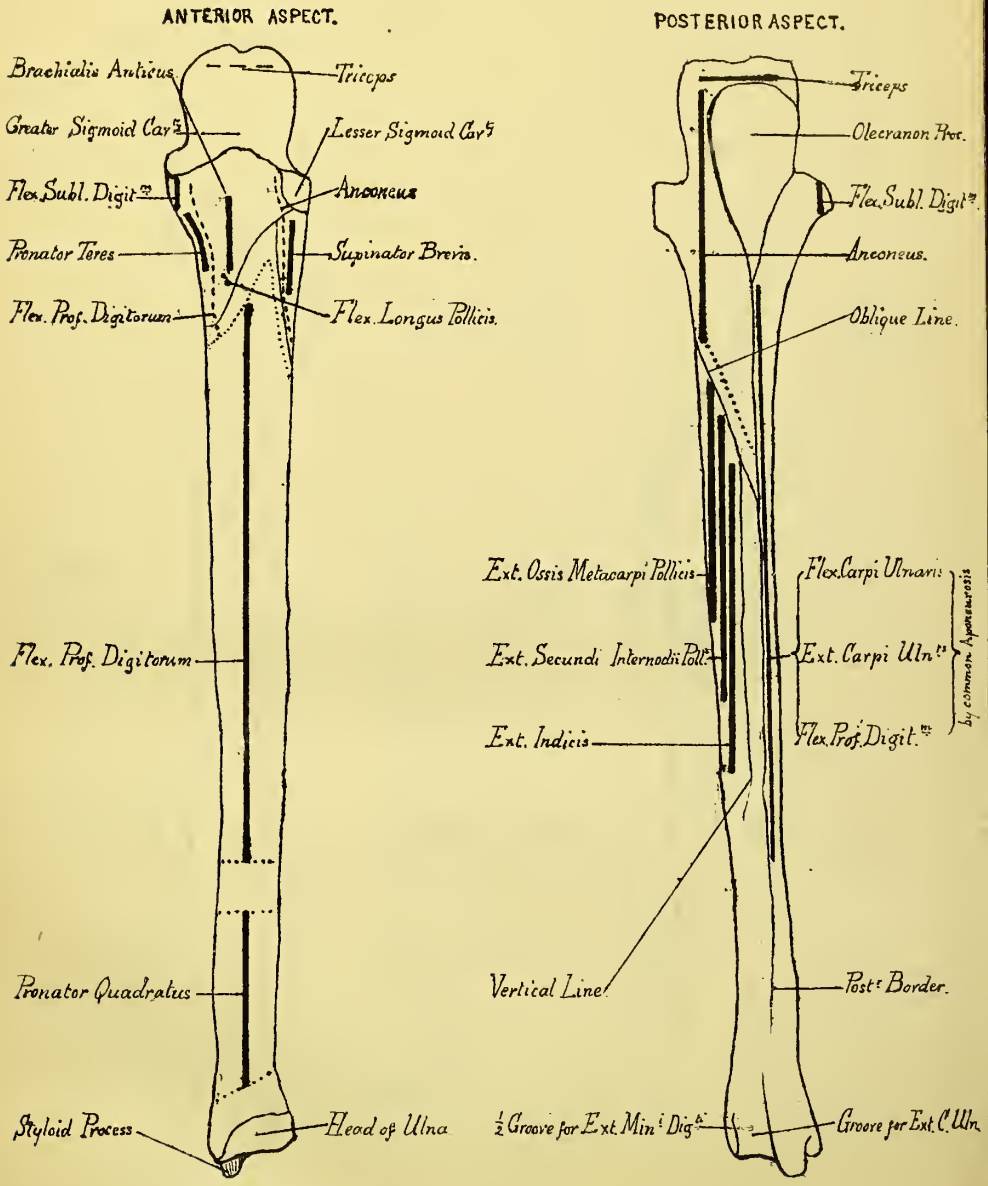
ANTERIOR ASPECT.
Brachialis Anticus
Triceps
Greater Sigmoid Cav.
Lesser Sigmoid Cav.
Flex. Subl. Digit.
Anconeus
Pronator Teres
Supinator Brevis.
Flex. Prof. Digitorum
Flex. Longus Pollicis.
Flex. Prof. Digitorum
Pronator Quadratus
Styloid Process
Head of Ulna
POSTERIOR ASPECT.
Triceps
Olecranon Proc.
Flex. Subl. Digit.
Anconeus.
Oblique Line.
Ext. Ossis Metacarpi Pollicis
Flex. Carpi Ulnaris
Ext. Secundi Internodii Poll.
Ext. Carpi Ulnaris
Ext. Indicis
Flex. Prof. Digit.
by Common Aponeurosis
Vertical Line
Post. Border.
½ Groove for Ext. Min. Dig.
Groove for Ext. C. Uln.

RADIUS.

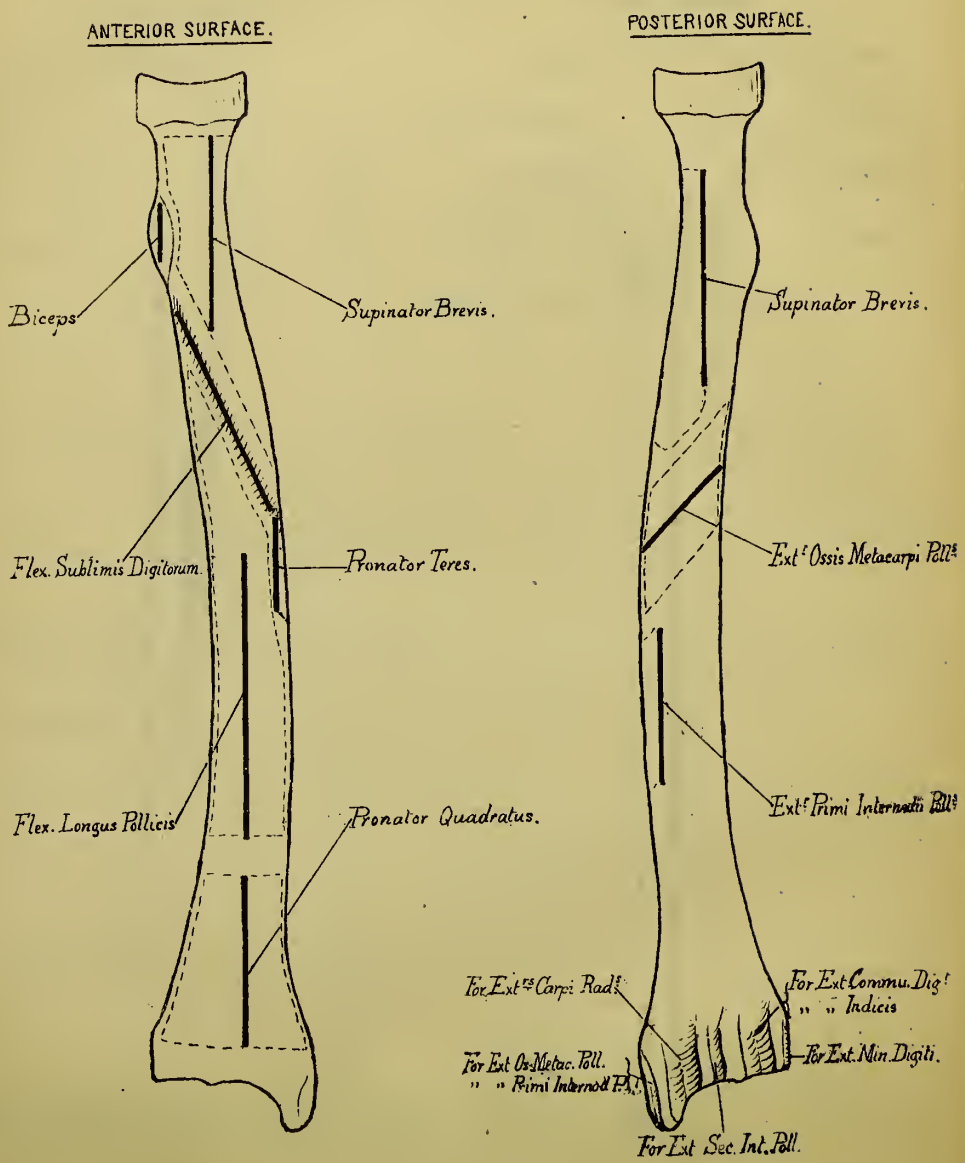
ANTERIOR SURFACE.
POSTERIOR SURFACE.
Biceps
Supinator Brevis.
Flex. Sublimis Digitorum.
Pronator Teres.
Flex. Longus Pollicis
Pronator Quadratus.
Supinator Brevis.
Ext^r Ossis Metacarpi Poll^is
Ext^r Primi Internodii Poll^is
For Ext^rs Carpi Rad^is
For Ext Commu. Dig^t
" " Indicis
For Ext. Min. Digiti.
For Ext Os Metac. Poll.
" " Primi Internod^i P.L.
For Ext Sec. Int. Poll.

UPPER EXTREMITY.

Head,	disc-shaped	concave above, articular for Capitellum. flattened laterally, ,, ,, Lesser Sigmoid Cavity and Orbicular Ligament.
Neck,	cylindrical, constricted and smooth.	
Tuberosity,	below and to inner side of Neck, oval	rough for insertion of Biceps tendon behind. smooth ,, Bursa under ,, ,, in front.

LOWER EXTREMITY.

Surfaces	**Inferior,**	triangular, concave, articular	divided into	outer triangular part for Scaphoid. inner rectangular ,, Semilunar.
			continued	on to Styloid Process (inner aspect) externally. into Sigmoid Cavity (for Ulna) internally.
	Internal,	oval, ,, ,, forming Sigmoid Cavity.		
	External,	grooved for Extensors of Thumb, prolonged down into Styloid Process.		
	Anterior,	rough ,, Anterior Ligament of Wrist.		
	Posterior,	grooved ,, Extensor Tendons, rough for Posterior Ligament of Wrist.		

SHAFT (prismoid, convex outwards, tapering upwards).

Borders	**Anterior,**	(upper half forming Oblique Line) from front of Tuberosity to front of Styloid Process.
	Internal,	(or Interosseous) bifurcating below ,, back ,, ,, extremities of Sigmoid Cavity.
	Posterior,	,, ,, of Neck ,, back of Styloid Process.

Surfaces	**Anterior,** concave, attaching three Flexors and three Rotators	Biceps Supinator Brevis	*above* Oblique Line
		Flexor Sublimis Digitorum Pronator Teres	*to* ,, ,,
		Flexor Longus Pollicis Pronator Quadratus	*below* ,, ,,
	External, convex, ,, three Rotators	Supinator Brevis, Pronator Teres, Supinator Longus,	over *upper third.* in *middle* ,, to *lower* end (root of Styloid Process).
	Posterior, flattened, ,,	Supinator Brevis, Ext. Ossis Metacarpi Pollicis, ,, Primi Internodii ,,	to *upper third.* to *middle* ,, in *lower* ,, (for 1 to 2 inches).

There are **six Grooves** on the Lower Extremities of the Radius and Ulna,
three for muscles of the Thumb and Little Finger, alternating with
three for the other Fingers and Hand.

On Styloid Process,	on outer side, a *double* groove for	Extensor Ossis Metacarpi Pollicis. „ Primi Internodii „
On back of Radius,	on outer side, a „ „ „	„ Carpi Radialis Longior. „ „ „ Brevior.
	at middle, a *single* „ „ „	Secundi Internodii Pollicis.
	on inner side, a *double* „ „	„ Communis Digitorum. „ Indicis.
Between Radius and Ulna,	a *single* „ „ „	Minimi Digiti.
On back of Ulna,	a „ „ „ „	Carpi Ulnaris.

Of the six Grooves
- the *outer two* are double.
- „ *inner* „ „ single.
- „ *middle* „ „ { external, single. / internal, double.

As regards the Radius, Ulna and prismatic portion of the Clavicle, one of the three surfaces in each case is flat, one convex and one concave.

GROOVES ON LOWER ENDS OF RADIUS AND ULNA

(4) Double for { Extensor Communis Digit^m / Extensor Indicis }

(3) Single for Secundi Internodii Poll.

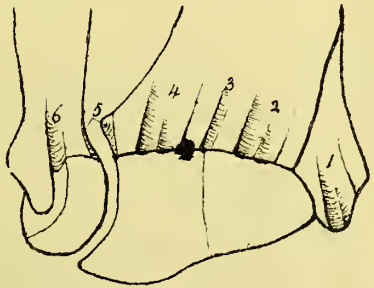

Single for Ext. Minimi Digiti. (5)

" " Ext. Carpi Ulnaris. (6)

(2) Double for { Ext. Carpi Rad. Long. / " " " Brevior }

(1) " " { Ext. Primi Int. Pollicis. / " Ossis Metac. " }

CARPAL BONES .- ARTICULAR SURFACES.

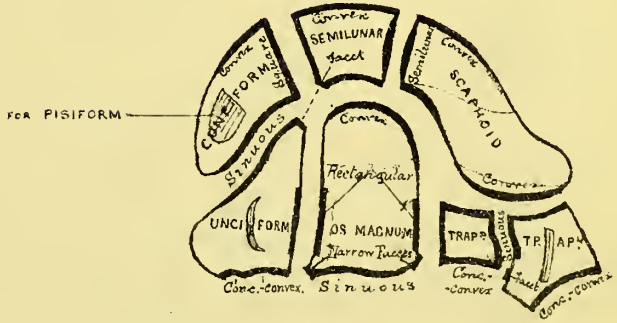

The thick lines show the positions of the articular surfaces.

METACARPAL BONES.

BASES.

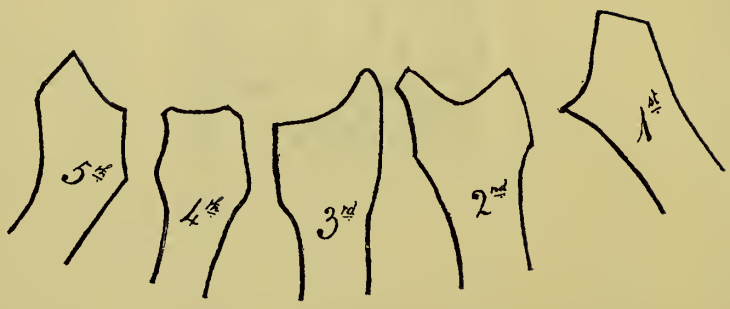

PHALANGES.

1st ROW. 2nd ROW. 3rd ROW.

Composed of *eight* Bones in *two Rows*		in the upper Row		Scaphoid and Semilunar.
				Cuneiform ,, Pisiform.
		in the lower ,,		Trapezium ,, Trapezoid.
				Os Magnum ,, Unciform.
Of **all the Bones** of	**both Rows**		the *posterior surfaces* are	flattened and rough for Ligaments.
			,, *anterior* ,, ,,	tubercular ,, ,, ,,
,, ,, ,,	the **first Row**		,, *posterior* ,, ,,	smaller than the anterior.
,, ,, ,,	,, **second** ,,		,, ,, ,, ,,	larger ,, ,,
,, ,, ,,	,, **first** ,,		,, *superior* ,, ,,	convex, articular for Radius or Ulna.
,, ,, ,,	,, **second** ,,	(except Os Magnum)	,, *inferior* ,, ,,	saddle-shaped, ,, ,, Metacarpus.
,, ,, ,,	,, ,, ,,	of the Trapezium / Trapezoid	,, *superior* ,, ,,	concave, ,, ,, Scaphoid.
		,, Os Magnum	,, ,, ,, ,,	convex, ,, ,, Semilunar.
		,, Unciform	,, ,, ,, ,,	sinuous, ,, ,, Cuneiform.
,, the **terminal Bones** of the **first** ,,		Scaphoid / Cuneiform	,, *posterior* ,, ,,	reduced to rough grooves.
,, ,, ,, ,, **second** ,,		Trapezium / Unciform	,, *anterior* ,, ,,	prolonged into hooked processes.
,, ,, ,, ,, **both Rows**			,, *lateral free* ,, ,,	tubercular.
,, the **Os Magnum**			,, *lateral* ,, carry	square facets ext. below and in front. int. above ,, behind.
			,, *inferior surface* is	sinuous, articular.
,, ,, *two Bones internal* to Os Magnum		Cuneiform / Unciform	,, *contiguous surfaces* are	,, ,,
,, ,, ,, *external* ,, ,,		Trapezoid / Trapezium	,, ,, ,, ,,	,, ,,
,, ,, **Semilunar Bone**			,, *external surface* is	semilunar ,, ,, Scaphoid.
			,, *internal* ,, is	square ,, ,, Cuneiform.

SPECIAL POINTS.

Of the	**Scaphoid,**	the *lower part* of	*inner*	*surface* is	deeply concave for Os Magnum.
,,	**Semilunar**	,, *inner* ,,	*lower*	,,	marked by a narrow facet for Unciform.
,,	**Cuneiform**	,, ,, ,,	*anterior*	,,	,, ,, square ,, Pisiform.
,,	**Trapezium**	,, *lower* ,,	*inner*	,,	,, ,, small ,, Second Metacarpal.
,,	**Trapezoid**	,, *superior, lateral,* and *inferior surfaces* are			articular and continuous with each other.
,,	**Os Magnum**	,, *lateral borders* of *lower surface* are			marked by narrow facets for second and fourth Metacarpals.
,,	**Unciform**	,, *under surface* is			subdivided into two facets for fourth and fifth Metacarpals.
,,	**Pisiform**	,, *outer* ,,			convex,—the *inner* concave.

METACARPAL BONES—distinctive characteristics.

First Bone—short, broad, having no lateral facets on Base and no ridge on Posterior Surface. Head broader from side to side.

Second ,, —longest of all, Base deeply concave from side to side, with	2 Facets	on Carpal Surface	for	Trapezoid. Os Magnum.
	1 Facet	externally	,,	Trapezium.
	1 ,,	internally	,,	3rd Metacarpal.
Third ,, —Base prolonged upwards on radial side only ,,	1 ,,	on Carpal Surface	,,	Os Magnum.
	1 ,,	externally	,,	2nd Metacarpal.
	2 Facets	internally	,,	4th ,,
Fourth ,, —Base small and cuboidal ,,	2 ,,	on Carpal Surface	,,	Os Magnum. Unciform.
	2 ,,	externally	,,	3rd Metacarpal.
	1 Facet	internally	,,	5th ,,
Fifth ,, —Base small, Post. Surface marked by single oblique line ,,	1 ,,	on Carpal Surface	,,	Unciform.
	1 ,,	externally	,,	4th ,,
	Tubercle	internally		non-articular.

PHALANGES.

Of first row,	—*Superior Surface of Base* oval and concave,	—*Distal Extremity* condyloid.
,, second ,, — ,, ,, ,, ,, ,, ,,	subdivided by antero-post. ridge,—	,, ,, ,,
,, third ,, — ,, ,, ,, ,, ,, ,, ,, ,, ,, ,, —		,, ,, rough and pointed.

Notice the arrangement of both the Carpal and the lateral facets on the Metacarpal Bones.

ILIUM.

Surfaces

- **External**
  - *Superior Curved Line* from upper part of Great Sciatic Notch to Crest 2in. from Posterior Superior Spine.
  - *Middle* ,, ,, ,, ,, ,, ,, ,, ,, ,, ,, Anterior.
  - *Inferior* ,, ,, ,, front ,, ,, ,, ,, back of Notch between Anterior Spines.
  - *The Surface behind* the Superior Curved Line is irregular for the { Pyriformis below. Glutæus Maximus above.
  - ,, ,, *between* ,, ,, and Middle Lines ,, concave ,, Glutæus Medius.
  - ,, ,, ,, ,, Middle and Inferior ,, ,, convex ,, Glutæus Minimus.
  - ,, ,, *below* ,, Inferior Line ,, irregular ,, Rectus (reflected head).
- **Internal**
  - *In front* smooth and concave for Iliacus presenting nutrient foramen below.
  - *Behind* rough and irregular ,, Sacro-iliac Ligs. above ,, Auricular Surface for Sacrum below.

Borders

- **Superior** (Crest) to *outer lip* { Tensor Vag. Femoris; Obliquus Externus; Latissimus Dorsi } —to *inner lip* { Transversalis; Quadratus Lumb.—*intermediately*—Obliquus Internus; Erector Spinæ. }
- **Anterior**
  - *above*, Anterior Superior Spine attaching Sartorius
  - *below*, ,, Inferior ,, ,, Rectus (straight head)
  - } with notch between.
- **Posterior**
  - *above*, Posterior Superior ,, ,, Sacro-iliac Lig.
  - *below*, ,, Inferior ,, entering into ,, Joint.
  - } ,, ,, ,,

The Ilium forms rather *less* than $\frac{2}{5}$ of the Acetabulum.

ISCHIUM.

Surfaces

- **External**
  - *above* forms lower and back part of Acetabulum (rather *more* than $\frac{2}{5}$ of cavity).
  - *below* presents groove for Obturator Externus Tendon.
- **Internal**
- **Posterior**
  - are smooth and broad *above*, narrow *below*, the Internal attaching part of Obturator Internus.

Borders

- **Posterior**
  - *about centre*—Spine of Ischium attaching { Gemellus Superior externally. Levator Ani and Coccygæus internally. Small Sacro-sciatic Lig. at tip.
  - *above spine*—Great Sacro-sciatic Notch transmitting Pyriformis with { Glutæal Vessels and Nerve. Sciatic ,, ,, Nerves. Pudic (Int.) ,, ,, Nerve. Nerves to { Obturator Internus. Gemelli and Quadratus. }
  - *below Spine*—Small Sacro-sciatic Notch transmitting Obtur. Int. with { Nerve to Obturator Internus. Internal Pudic Vessels and Nerve. }
- **Inferior** thick, continuous with Tuberosity.
- **Internal** thin, forming posterior margin of Obturator Foramen.

Tuberosity
- on *outer lip*— Adductor Magnus, Quadratus Femoris, on *inner lip* Transversus Perinei, Erector Penis, with Ridge for Great Sacro-sciatic Lig., Groove for Int. Pudic Vessels.
- „ *surface*— to upper and *outer* part — Semi-membranosus.
  - ,, lower „ *inner* ,, — Biceps with Semi-tendinosus.
- „ *upper part*—at junction with Body—Gemellus Inferior.

Ramus,— see Pubes and Diagram.

PUBES.

Extremities
- *outer*, triangular, smooth and concave, entering into Acetabulum, forming $\frac{1}{5}$ of Cavity.
- *inner*, oval, rough ,, flat, ,, ,, Symphysis.

Surfaces

Superior
- the *posterior border* forms Ilio-pectineal Line, continued outwards between Ilium and Ischium.
- on *anterior border*, near Symphysis,—Spine of Pubes, „ inwards to Symphysis as Crest of Pubes.
- near *outer end*, —Ilio-pectineal Eminence.
- at *inner* ,, —Angle of Pubes (between Crest and Symphysis).
- *intermediate surface*, triangular in form, attaches Pectineus.

Inferior
- *externally*, forms Obturator Groove.
- *internally*, enters into Obturator Foramen.

Internal, smooth, forming Anterior wall of Pelvis.
External, rough, for Muscular attachments.

Muscles attached to Body of Pubes, and Rami of Pubes and Ischium.

Externally
- To Crest of Pubes, —Rectus Abdominis, Pyramidalis and Conjoined Tendon.
- „ Spine „ „ and Ilio-pectineal Line, —External Oblique, Internal Oblique and Transversalis.
- „ Body „ ,, below Crest, —Adductor Longus.
- „ Ramus „ ,, — ,, Brevis.
- „ Rami „ ,, and Ischium, —Gracilis (to margin of Pubic Arch).
- „ ,, „ ,, ,, ,, and Tuber Ischii,—Adductor Magnus, on inner side of Obturator Foramen.
- „ Body „ ,, (upper surface), —Pectineus above „ „
- „ Tuber Ischii (outer „), —Quadratus Femoris, below „ „
- „ Edge of Foramen (anterior half), —Obturator Externus, centrally over „ „

Internally
- „ ,, „ ,, (except above and in front) } —Obturator Internus.
- „ Body of Ischium (,, below ,, behind) } —Obturator Internus.
- ,, Rami of Pubes and Ischium, —Compressor Urethræ, Transversus Perinæi and Erector Penis.

PUBES AND ISCHIUM,— EXTERNAL SURFACES.

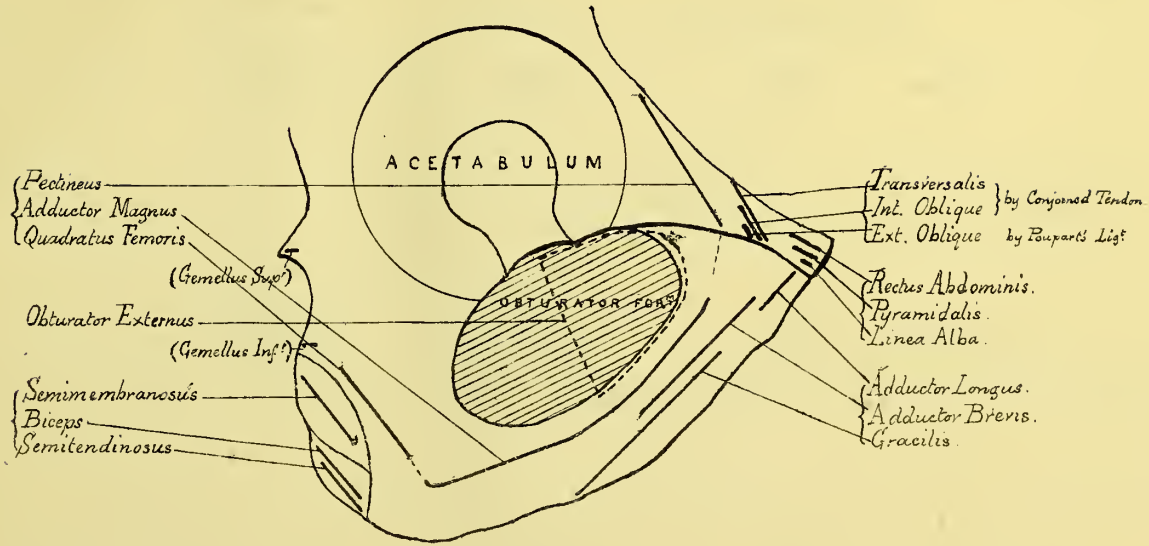

The relative situations of the Muscular Attachments only are shown.

DIAMETERS OF PELVIS.

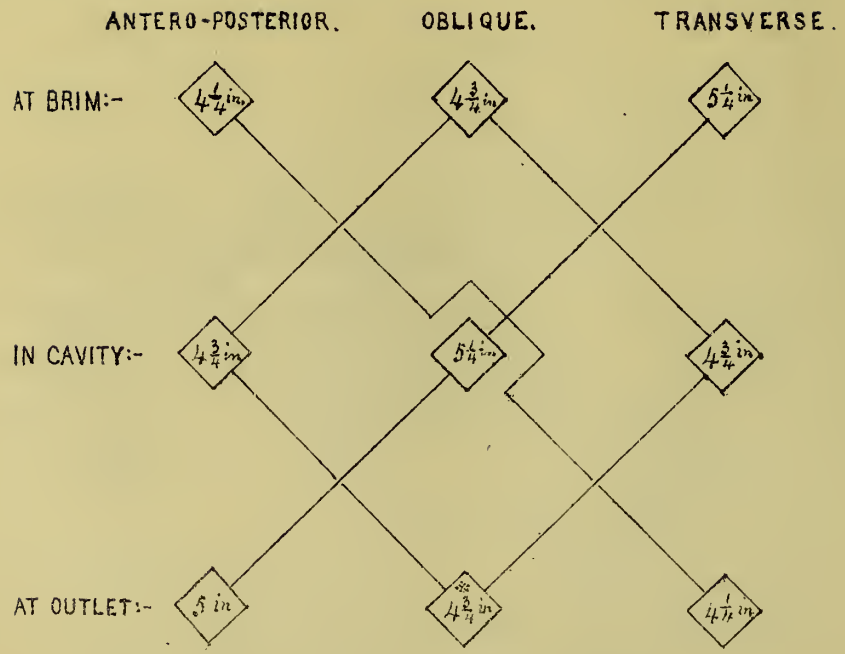

The Oblique Diameter at the Outlet is not usually described.

Base of Sacrum	is situated	opposite a point taken 4 inches above Symphysis Pubis.
Apex of Coccyx,	,, ,,	,, ,, ,, ,, ½ inch below ,, ,,
Axis of Inlet	corresponds	to a line drawn from middle of Coccyx to Umbilicus.
,, ,, **Outlet**	,,	,, ,, ,, ,, Base of Sacrum at right angles to plane of Outlet.

Special Characters

- in *Male*
  - *Bones* thick, strong and well marked.
  - *Sacrum* more curved than in Female, Pubic Arch narrow.
  - *Cavity* narrow and deep. Diameters less than in Female.
  - *Obturator Foramen* large and oval.
- ,, *Female*
  - *Bones* thinner, weaker and less marked than in Male.
  - *Sacrum* less curved, Promontory less projecting, Coccyx more movable, Pubic Arch wider and everted.
  - *Cavity* broader and shallower, Ilia being more apart, and Spines of Ischium less projecting.
  - *Obturator Foramen* smaller and triangular.
- ,, *Infant*
  - *Bones* soft and semi-cartilaginous.
  - *Sacrum* and Pubes narrow.
  - *Cavity* very narrow, sides being almost parallel, Transverse diameter at brim the shortest.
  - *Obturator Foramen* small and rounded.

Diameters,— see Diagram. The Diagram shows the average lengths of the three chief diameters at the Inlet, in the Cavity and at the Outlet in the Female. The lines indicate the diameters which are about equal in length.

UPPER EXTREMITY.

Head,	—directed	forwards as well as upwards and inwards.
Neck,	—less oblique	in childhood, in old age and in the female.

Great Trochanter,—Muscles attached	on *Anterior Border,*	to facet	Glutæus Minimus.
	,, *Posterior* ,,	below (to Linea Quadrati)	Quadratus Femoris.
	,, *Outer Surface,*	to Oblique Line	Glutæus Medius.
	,, *Inner* ,,	,, Digital Fossa	Obturator Externus.
	,, *Upper Border,*	,, two Facets	Obturator Int. with Gemelli in front. Pyriformis behind.
Small Trochanter,— ,, ,,	,, *Summit*		Psoas Magnus.
	to triangular *space below* and in *front*		Iliacus.
	,, linear ,, ,, ,, *behind*		Pectineus.

Anterior Intertrochanteric Line	runs *in front* between Trochanters, marked *above*	by Tubercle of Femur.
Posterior ,, ,,	,, *behind* ,, ,, ,, *at middle* ,,	Quadrate Tubercle.
Spiral Line	,, from *middle* of Ant. Intertroch. Line to Line between Small Troch. and Linea Aspera.	
Quadrate ,,	,, ,, ,, ,, Post. ,, ,,	vertically downwards for two inches.

The Spiral Line above described is commonly called the Anterior Intertrochanteric, and this latter, as indicated above, is unrecognised.

SHAFT.

Borders	**External**	from Great Trochanter to Anterior part of External Condyle.
	Internal	,, Small ,, ,, ,, ,, Internal ,,
	Posterior (Linea Aspera)	begins above by two lines, one from the back of each Trochanter. ends below ,, ,, ,, to ,, ,, ,, Condyle.

The inner root of the Linea Aspera above is by some said to pass into, not the Small Trochanter, but the Spiral Line.
For Muscles attached to Linea Aspera, etc., see Diagram.

Surfaces	**External,** smooth and convex,	attaching Cruræus.
	Internal, ,, ,, ,, ,,	Vastus Internus.
	Anterior, ,, ,, ,, ,,	Cruræus and Subcruræus.

FEMUR.

MUSCLES ON POSTERIOR ASPECT.

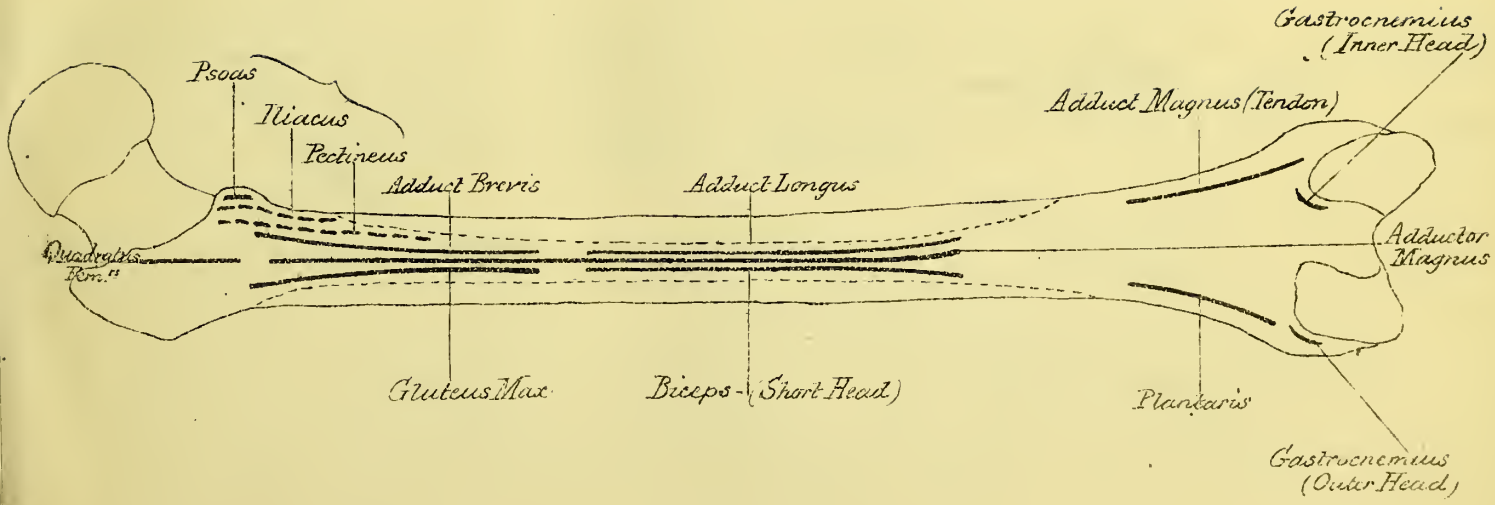

GREAT TROCHANTER.

LINES LEADING FROM IT.

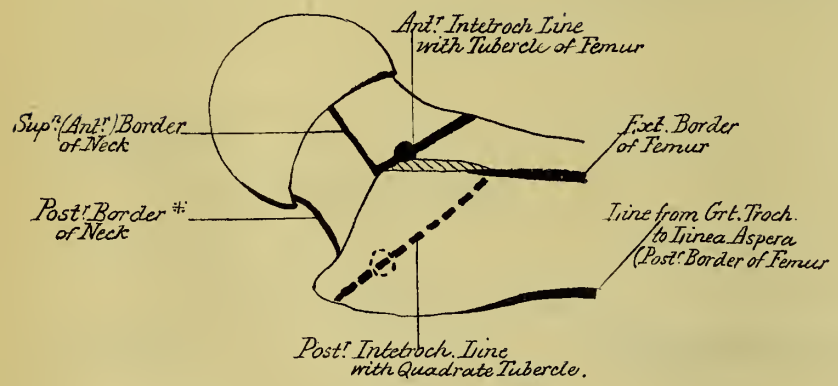

* This Border is not always described.

MUSCLES ATTACHED ROUND IT.

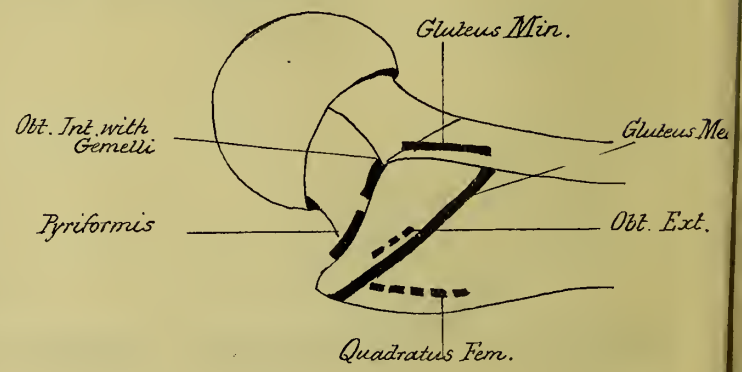

LOWER EXTREMITY.

External Condyle
- is more prominent than the Internal, in front.
- presents *circumferentially* a broad, articular surface, of which the axis runs directly backwards.
- „ *externally*, External Tuberosity and 3 Depressions
  - one above for Gastrocnemius (outer head).
  - ,, in middle „ External Lateral Ligament.
  - ,, below „ Popliteus.

Internal Condyle
- is more prominent than the External both below and internally.
- presents *circumferentially* a narrower articular surface than the External, of which the axis is directed first inwards, then backwards.
- „ *internally*, Internal Tuberosity for Internal Lateral Ligament.
- „ *above and behind*,
  - externally, a depression for the Gastrocnemius (inner head).
  - internally, a tubercle „ Adductor Magnus tendon.

The *articular surfaces* of the Condyles are continuous in *front*, presenting trochlear surface for Patella.
„ „ „ „ „ „ separated *behind* by the Intercondyloid Notch.
„ „ *surface* ,, Internal Condyle presents *below*, on its *outer edge*, a small facet for the Patella in extreme flexion.
„ „ „ ,, External „ is prolonged *in front*, further *upwards* than that of the Internal.
„ *contiguous surfaces* ,, Condyles attach
- Anterior Crucial Ligament (to External Condyle).
- Posterior ,, ,, (,, Internal ,,).

PATELLA.

Anterior Surface
- *edge* bevelled above and on sides for Tendon of Quadriceps Extensor.
- „ ,, below ,, Ligamentum Patellæ.

Posterior Surface
- in *upper three-quarters* presenting oval articular facet
  - subdivided by a vertical ridge into two divisions.
  - marked along lower edge by narrow facet.
  - „ ,, inner „ „ ,, „
- in *lower quarter* „ rough surface attaching Ligamentum Patellæ near tip.

Of the Articular Surface
- the two divisions* are for the Condyles of the Femur in flexion.
- ,, narrow facet below ,, ,, in extreme extension.
- ,, ,, ,, internally ,, Internal Condyle ,, ,, flexion.

* The External is the larger.

UPPER EXTREMITY is expanded laterally into two Tuberosities.

The Tuberosities are
- continuous *in front* forming triangular surface prolonged below into *Tubercle.*
- separated *behind* by *Popliteal Notch.*
- ,, *above* ,, *rough depressions* in front and behind the *Spine.*

The *External* is
- *above* articular for External Condyle of Femur. Surface is nearly circular and flattened.
- *behind* ,, ,, Head of Fibula by small facet. ,, ,, ,, ,, ,,

The *Internal* is
- *above* ,, ,, Internal Condyle of Femur. ,, ,, oval and concave.
- *behind* grooved ,, insertion of Semi-membranosus.

Intermediately above are 7 points from before back
- for attachment of Internal Semilunar Cartilage—anterior end.
- ,, ,, ,, Anterior Crucial Ligament.
- ,, ,, ,, External Semilunar Cartilage— ,, ,,
- Spine of Tibia.
- for attachment ,, ,, ,, ,, —posterior ,,
- ,, ,, ,, Internal ,, ,, ,, ,,
- ,, ,, ,, Posterior Crucial Ligament.

The extremities of the External Cartilage are fixed immediately in front and behind the Spine.
,, ,, ,, Internal ,, alternate with those of the Crucial Ligaments.

SHAFT.

Borders
- *Anterior,*—from Tubercle to anterior border of Internal Malleolus.
- *Internal,*— ,, back of Internal Tuberosity ,, posterior ,, ,, ,, ,,
- *External,*— ,, ,, External ,, ,, borders of surface for Fibula (bifurcating below).

Surfaces
- *External*
  - concave above for origin of Tibialis Anticus.
  - convex below,—crossed by tendons of Extensors.
- *Internal*
  - convex above,—attaching Sartorius, Gracilis and Semitendinosus.
  - ,, below,—subcutaneous.
- *Posterior* flattened
  - presents Oblique Line with
    - Vertical Line running down from it.
    - Medullary Foramen immediately below it.
  - attaches
    - Popliteus above to Oblique Line.
    - Soleus
    - Flex. Longus Digitorum, internal to Vertical ,,
    - Tibialis Posticus external ,,

PATELLA.

ARTICULAR SURFACE.

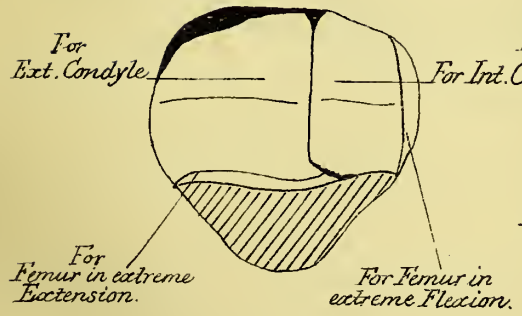

TIBIA.

UPPER SURFACE OF HEAD.

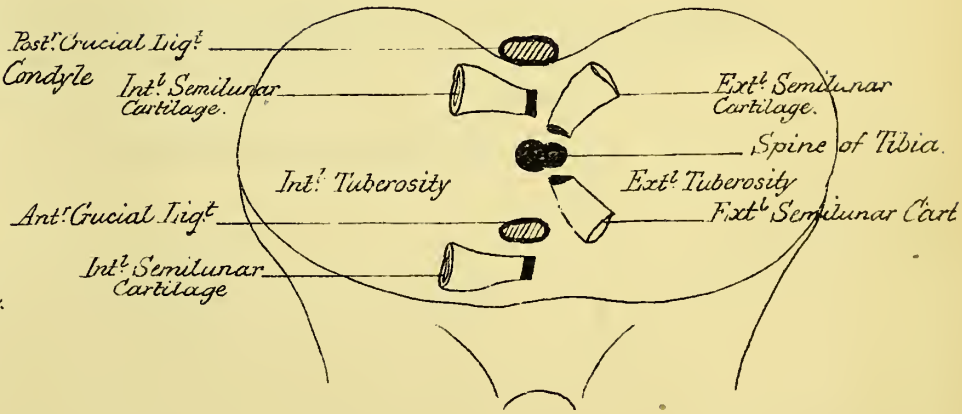

TIBIA AND FIBULA.

MUSCULAR ATTACHMENTS ON POSTERIOR ASPECT.

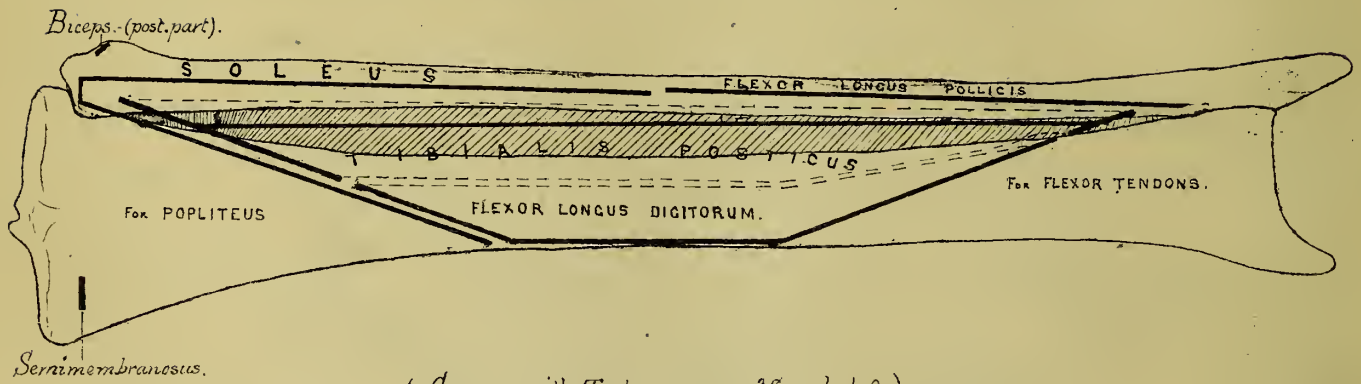

(Compare with Text on pages 38 and 40.)

LOWER EXTREMITY.

Surfaces
- *Anterior*, —crossed by Extensor Tendons, attaching Anterior Ligaments of Ankle.
- *Posterior*,—grooved for Flexor Longus Pollicis Tendon, ,, Posterior ,, ,, ,,
- *External*, —concave and rough for { articulation with Fibula below. / attachment of Interosseous Ligament above.
- *Inferior*, —articular for Astragalus, ridged in mid-line antero-posteriorly.
- *Internal*, —prolonged into Internal Malleolus
  - articular for Astragalus on outer side.
  - subcutaneous ,, inner ,,
  - attaching Interior Lateral Ligament by tip.
  - grooved posteriorly for tendons of { Tibialis Posticus. / Flex. Longus Digitorum.

GROOVES ON LOWER EXTREMITIES OF TIBIA AND FIBULA.

On posterior border of Internal Malleolus,—Groove for { Tibialis Posticus. / Flexor Longus Digitorum.

,, ,, ,, ,, External ,, ,, ,, { Peroneus Longus. / Peroneus Brevis.

On back of Tibia midway between Malleoli, — ,, ,, Flexor Longus Pollicis.

HEAD presents	rough impression	*externally*	for Biceps, and for Long External Lateral Ligament.
	,, ,,	*posteriorly*	,, Soleus and Posterior Tibio-fibular Ligament.
	,, ,,	*anteriorly*	,, Peroneus Longus and Ant.- ,, ,,
	prolonged upwards	*behind*	into Styloid Process for Short External Lateral Ligament.
	articular	*above*	for Tibia,—Facet looks upwards and inwards.

LOWER EXTREMITY	*External Surface*	subcutaneous,	attaching Middle Fasciculus of Ext. Lateral Ligament below.
	Internal ,,	articular in front for Astragalus,	,, Posterior ,, ,, ,, ,, behind.
External Malleolus.	*Anterior Border*	rough	,, Anterior ,, ,, ,, ,,
	Posterior ,,	grooved	for Peroneus Brevis and Peroneus Longus tendons.

SHAFT.

Borders	*Anterior*	from front of head, bifurcating below to enclose outer surface of Malleolus.
	Internal (Interosseous)	,, ,, ,, ,, ,, ,, ,, inner ,, ,, ,,
	Posterior	,, Styloid Process ,, posterior border ,, ,,
	Oblique Line	,, inner side of Head to join Internal Border in its lower half.

Surfaces	*Internal* (in post. part)	in upper	$\frac{1}{2}$	attaches	Soleus.
		,, lower	,,	,,	Flexor Longus Pollicis.
	External	,, upper	$\frac{2}{3}$	,,	Peroneus Longus.
		,, lower	,,	,,	,, Brevis.
	Anterior (in outer part)	,, upper	$\frac{3}{4}$	,,	Extensor Longus Digitorum.
		,, lower	$\frac{1}{4}$	,,	Peroneus Tertius.
	,, (in inner part)	,, middle	$\frac{4}{5}$	,,	Extensor Proprius Pollicis. } on opposite sides of Interosseous Membrane.
	Internal (in anter. part)	,, ,,	,,	,,	Tibialis Posticus.

When the Fibula is held with its anterior surface directed towards the observer, the three borders and the oblique line are all in view (see Diagram).

FIBULA.

TRANSVERSE SECTION. ABOUT MIDDLE.

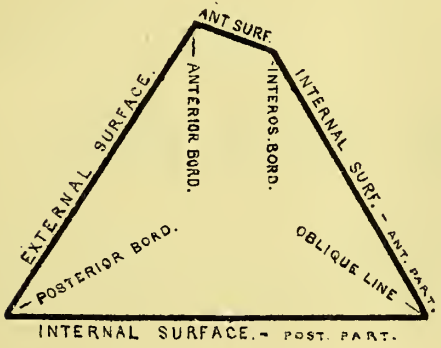

(For Muscles attached see p 40.)

TIBIA AND FIBULA.

GROOVES ON LOWER EXTREMITIES.

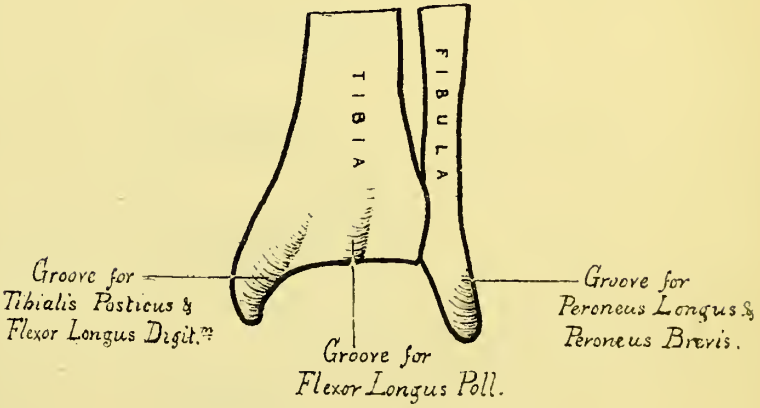

(See page 39.)

TARSUS.

To show correlation of Ant^r and Post^r Surfaces of Bones of Inner portion of Tarsus.

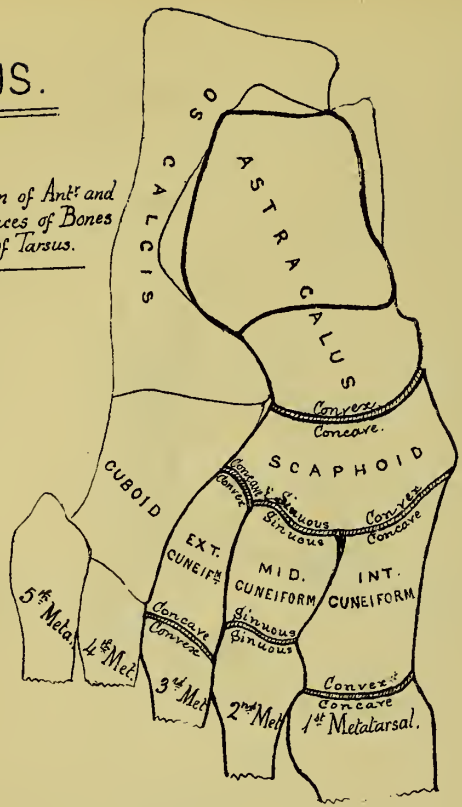

METATARSUS.

To show articular facets on Bases.

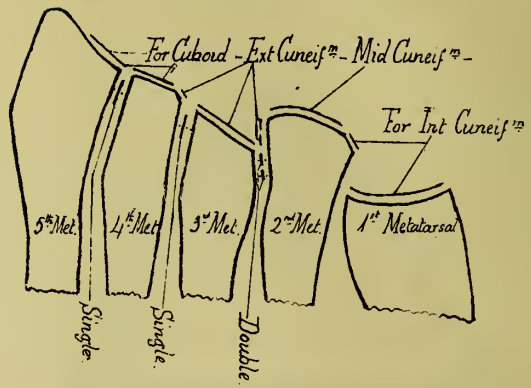

Superior Surface	*posteriorly,*	concave, for fat under Tendo Achillis.	
	in middle,	presenting two facets for Astragalus	external,—large, convex, looking forward and upward. internal,—small, concave (upper surface of Lesser Process). separated by rough groove for Interosseous Ligament.
	anteriorly,	rough for Ligaments, etc. (superior surface of Greater Process).	
Inferior ,,	*posteriorly,*	presenting two Tubercles for origins of	Abductor Pollicis. ,, Minimi Digiti. Flexor Brevis Digitorum.
	intermediately,	rough for	Long Plantar Ligament. Outer head of Accessorius.
	anteriorly,	presenting Tubercle for	Short Plantar Ligament.
External ,,	*above,*	rough for	Calcaneo-astragaloid ,,
	intermediately,	presenting tubercle for	External Lateral ,, (middle part).
	in front of tubercle,	,, two Grooves ,,	Peroneus Brevis ,, Longus } tendons.
Internal ,,	*below,*	smooth and concave for Flexor tendons and vessels,—attaching Accessorius (inner head).	
	above,	presenting Lesser Process (Sustentaculum Tali).	
	beneath Lesser Process,—grooved for		Flexor Longus Pollicis tendon.
Anterior ,,	concavo-convex, smooth, articular for Cuboid. overhung by tubercle at upper and outer part.		
Posterior ,,	convex	rough below for	Tendo Achillis.
		smooth above ,, bursa under	,, ,,

ASTRAGALUS.

Superior Surface	*posteriorly,*	rough for posterior part of External Lateral Ligament.
	intermediately,	smooth, forming trochlear surface for Tibia, wider in front than behind.
	anteriorly,	rough for Anterior Ligament of Ankle.
Inferior ,,	*posteriorly and externally*	presents large, concave facet for Os Calcis.
	anteriorly and internally	,, small, convex ,, ,, ,, ,, and Calcaneo-scaphoid Ligament.
	intermediately	,, groove for Interosseous Ligament.
External ,,	*behind*	,, triangular facet, base upwards for External Malleolus.*
	in front	,, rough impression for External Lateral Ligament (anterior part).
Internal ,,	*above*	,, pear-shaped facet, base forwards for Internal Malleolus.
	below	,, rough impression for Internal Lateral Ligament (middle part).
Posterior ,,	grooved for Flexor Longus Pollicis tendon.	
Anterior ,,	convex, articular for Scaphoid, continuous with smaller facet on Inferior Surface.	

* The facet for the External Malleolus is larger and more posterior than that for the Internal Malleolus.

CUBOID.

Superior Surface	rough for Ligaments.		
External ,,	,, ,, ,,	notched by Peroneal Groove	non-articular.
Inferior ,,	presenting in front groove for Peroneus Longus tendon		non-articular.
	,, behind ridge for Long and Short Plantar Ligaments		non-articular.
Posterior ,,	triangular,	sinuous,	wholly articular for Os Calcis.
Anterior ,,	,,	subdivided by vertical ridge ,, ,, ,,	4th and 5th Metatarsal Bones.
Internal ,,	quadrilateral	above, presenting articular facet for External Cuneiform (and sometimes Scaphoid).	
		below, rough for Interosseous Ligaments.	

Scaphoid	Posterior Surface,	concave and articular for Astragalus.
	Anterior ,,	presenting three facets for the Cuneiform Bones.
Facets on Anterior Surface of Scaphoid—		Internal *convex*, — Middle *sinuous*,— External *concave*.
,, ,, ,, Surfaces ,, Cuneiform Bones,		—On ,, ,, —On ,, ,, —On ,, ,,
,, ,, Posterior ,, ,, ,, ,,		— ,, ,, *concave*,— ,, ,, ,, — ,, ,, *convex*.
,, ,, ,, (Sup.) ,, ,, 1st, 2nd and 3rd Metatarsals,—		,, 1st ,, ,, 2nd ,, ,, 3rd ,,
Internal Surface of Scaphoid		tubercular for insertion of Muscles.
Internal ,, ,, Internal Cuneiform		tubercular for insertion of Muscles.
External ,, ,, ,, ,,	faceted along both superior and posterior border for	2nd Metatarsal in front. Middle Cuneiform behind.
Internal ,, ,, External ,,	,, at superior anterior angle and ,, ,, ,,	2nd Metatarsal in front. Middle Cuneiform behind.
External ,, ,, Middle ,,	correspond to surfaces of Internal and External Cuneiform contiguous to them.	
Internal ,, ,, ,, ,,	correspond to surfaces of Internal and External Cuneiform contiguous to them.	
External ,, ,, External ,,	faceted in front and behind for	4th Metatarsal in front. Cuboid behind.
External ,, ,, Scaphoid	rough for Ligaments.	
Sup. and Inf. Surfaces ,, all the Cuneiform	rough for Ligaments.	

METATARSALS.

First,	—Shortest.	*Base* having concave			tarsal facet, but no lateral facets.			
Second,	—Longest	,, ,,	sinuous	,, ,,	and	*internally, single* facet	for	Internal Cuneiform.
						externally, 2 *double* facets	,,	3rd Metatarsal in front. External Cuneiform behind.
Third,	—	,, ,,	convex	,, ,,	,,	*internally, double* faect	,,	2nd Metatarsal.
						externally, single	,, ,,	4th ,,
Fourth,	—	,, ,,	quadrilateral	,, ,,	,,	*internally, double*	,, ,,	3rd ,, in front. External Cuneiform behind.
						externally, single	,, ,,	5th Metatarsal.
Fifth,	—	,, ,,	triangular	,, ,,	,,	*internally,*	,, ,, ,,	4th ,,
						externally tubercular for insertion of Muscles.		

The **PHALANGES** resemble those of the Hand, but those of the second row are very small and short.

Vertebræ, —each by *nine* Centres.

3 *Primary*	One for right Lamina, ,, ,, left ,, ,, ,, Body,	appearing at 6th to 8th week ,, ,, ,, ,, ,, ,, ,, ,, 8th week	uniting in 1st year	uniting in 3rd year
4 *Secondary*	Two ,, each Transverse Process ,, ,, the Spinous Process	,, ,, 16th to 18th year		uniting in 30th year.
2 *Additional,*	—for Superior and Inferior Surfaces of Body,	,, ,, 20th year		

Atlas, —by *three* Centres.

3 *Primary*	One for right Lateral Mass, ,, ,, left ,, ,, ,, ,, Anterior Arch	appearing before birth ,, ,, ,, ,, in 1st year	uniting in 3rd year	united by 6th year

Axis, —by *six* Centres.

3 *Primary*	One for each Lateral Mass ,, ,, Body	,, early in fœtal life ,, 6th month	uniting in 1st to 2nd year	uniting in 3rd year
3 *Special*	Two ,, Base of Odontoid Process One ,, Apex ,, ,, ,,	,, 6th month ,, ,, ,,	,,	

Seventh Cervical,—centres as in other Vertebræ, with, in addition,
Two *Special* Centres, one for anterior part of each Transverse Process appearing in 6th month and uniting in 6th year.

Lumbar Vertebræ,—centres as in other Vertebræ, with, in addition,
Two *Special* Centres, one for each Mamillary Process.

Sacrum, —by *thirty-five* Centres.

15 *Primary*	One for each Body, ,, ,, ,, Lamina,	appearing at 8th week ,, ,, 6th to 8th month	uniting from 2nd to 6th year	ossification completed from 18th to 30th year.
6 *Secondary,*	— ,, ,, ,, Lateral Mass of each of the first three pieces	,, ,, 6th to 8th month		
14 *Additional*	One for each Sup. and Inf. Surface of Body, Two ,, ,, Lateral Margin of Sacrum,	,, ,, ,, ,, 18th to 20th year		

OSSIFICATION.

In the following Tables the Numbers which are printed in block type in the Text are given apart from their context, in order that their correlation may be the better seen.

	CENTRES.		UNION.	
VERTEBRÆ	6w — 8w 8w 16y — 18y 20y	1y	3y	30y
ATLAS.	1y	3y	6y	
AXIS.	6m	1y	3y	
SACRUM.	8w 8 } m 8 } 18y	2-6y	18y - 20y	

	CENTRES.	UNION.
COCCYX.	1y 5 — 10 y 10 — 15 y 15 — 20 y	—

BONES OF SKULL.

OCCIPITAL.	1 — 2 m 2 — 3 m 3 — 4 m	4y 6y
SPHENOID.	2m 2 — 3 m 3m 4 — 5 m 3y	—

Coccyx, —by *four* Centres.

4 *Primary*
- In first Piece, about birth } unite first
- ,, second ,, from 5th to 10th year } unite first
- ,, third ,, ,, 10th ,, 15th ,, } ,, next
- ,, fourth ,, ,, 15th ,, 20th ,, } ,, next

} unite last of all.

Occipital (*Four* Centres)
- One for Occipital part, formed in membrane, about 1st or 2nd month, unites with Condyloid part about 4th year.
- ,, ,, each Condyloid ,, ,, ,, cartilage, ,, 2nd ,, 3rd ,,
- ,, ,, Basilar ,, ,, ,, ,, ,, 3rd ,, 4th ,, ,, ,, } Occipital and Condyloid parts about 6th year.
- The Occipital ,, ,, Sphenoid from 20th to 25th yr.

Parietal (*One* Centre) ,, ,, membrane ,, 6th week.

Frontal (*Two* Centres) One for each lateral half, ,, ,, ,, ,, uniting shortly after birth.

Temporal (*Four* Centres)
- One for Squamous and Zygomatic Parts, appearing first (about 8th week) } uniting about 1st year.
- ,, ,, Auditory Part ,, next after Squamous } ,, ,, 1st ,,
- ,, ,, Petrous and Mastoid Parts ,, ,, ,, Auditory } ,, ,, 2nd to 3rd ,,
- ,, ,, Styloid Process ,, last

Sphenoid, *Ten* Centres (Five on each side)
- One for Great Wing and External Pterygoid Plate—at 2nd month } uniting about middle of fœtal life.
- ,, ,, Internal Pterygoid Plate —,, 2nd—3rd ,, } ,, shortly after birth.
- ,, ,, Lesser Wing and Body anteriorly —,, 3rd ,, } ,, just before birth.
- ,, ,, Body posteriorly —,, 4th—5th ,,
- ,, ,, Sphenoidal Turbinated Bone —,, 3rd year ,, about 20th year.

Ethmoid (*Three* Centres)
- One for perpendicular plate, appearing about 4th or 5th month (middle of fœtal life).
- ,, ,, each lateral mass ,, ,, 1st year (shortly after birth).

Sup. Maxillary (*Four* Centres)
- One for Nasal and Facial Parts
- ,, ,, Orbital ,, Malar ,,
- ,, ,, Incisive Part
- ,, ,, Palatine Process, less the Incisive Part

} appearing early in fœtal life.

Palate,	By *one* Centre, appearing about 8th week.
Malar,	,, ,, ,, ,, ,, ,, ,,
Lachrymal,	,, ,, ,, ,, ,, ,, ,,
Nasal,	,, ,, ,, ,, ,, ,, ,,
Inferior Turbinated bone	,, ,, ,, ,, ,, middle of fœtal life.
Vomer,	,, *two* lateral centres, separated by a plate of cartilage, appearing about 8th week—uniting after puberty.
Inferior Maxilla,	,, ,, centres, appearing very soon after that for the Clavicle.

Hyoid Bone (*Five* Centres)	One for Body	appearing before birth.	
	,, ,, each Great Cornu	,, ,, ,,	
	,, ,, ,, Small Cornu	,, shortly after birth.	
Sternum (*Six* Centres)	One for 1st piece	appearing about 5th to 6th month.	uniting rarely.
	,, ,, 2nd ,,	,, ,, 6th ,, 7th ,,	,, from 35th to 40th year.
	,, ,, 3rd ,,	,, ,, 7th ,, 8th ,,	,, ,, 20th ,, 25th ,,
	,, ,, 4th ,,	,, ,, 8th ,, 9th ,,	,, soon after puberty.
	,, ,, 5th ,,	,, ,, 1st ,, 2nd year.	remaining cartilaginous.
	,, ,, Xiphoid	,, from 2nd ,, 18th ,,	
Ribs (*Three* Centres)	One for Shaft	appearing at 6th week.	uniting about 25th year.
	,, ,, Tubercle (except in 11th & 12th Ribs)	,, from 16th to 20th year.	
	,, ,, Posterior Extremity ,,		
Clavicle (*Two* Centres)	One for Shaft,	appearing at 5th week	,, at 25th year.
	,, ,, Sternal End,	,, ,, 20th year	

The Clavicle is the earliest bone to ossify.

Scapula (*Seven* Centres)	One for Body	appearing about 8th week	,, about 15th year.
	,, ,, Coracoid Process (Body)	,, ,, 1st year	
	,, ,, ,, ,, (Root)	,, ,, 15th ,,	,, from 22nd to 25th year.
	,, ,, Acromion Process (Base)	,,	
	,, ,, Inferior Angle of Scapula	,, ,, 15th—16th ,,	
	,, ,, Acromion Process (Extremity)	,,	
	,, ,, Base of Scapula	,, ,, 17th ,,	

	CENTRES.	UNION.
STERNUM.	5 — 6 m 6 — 7 m 7 — 8 m 8 — 9 m 1 — 2 y 2 — 18 y	35 — 40 y 25 — 20 y 15 — 20 y
CLAVICLE.	5 w 20 y	25 y.
SCAPULA.	8 w 1 y 15 y 15 — 16 y 17 y	15 y 22 — 25 y

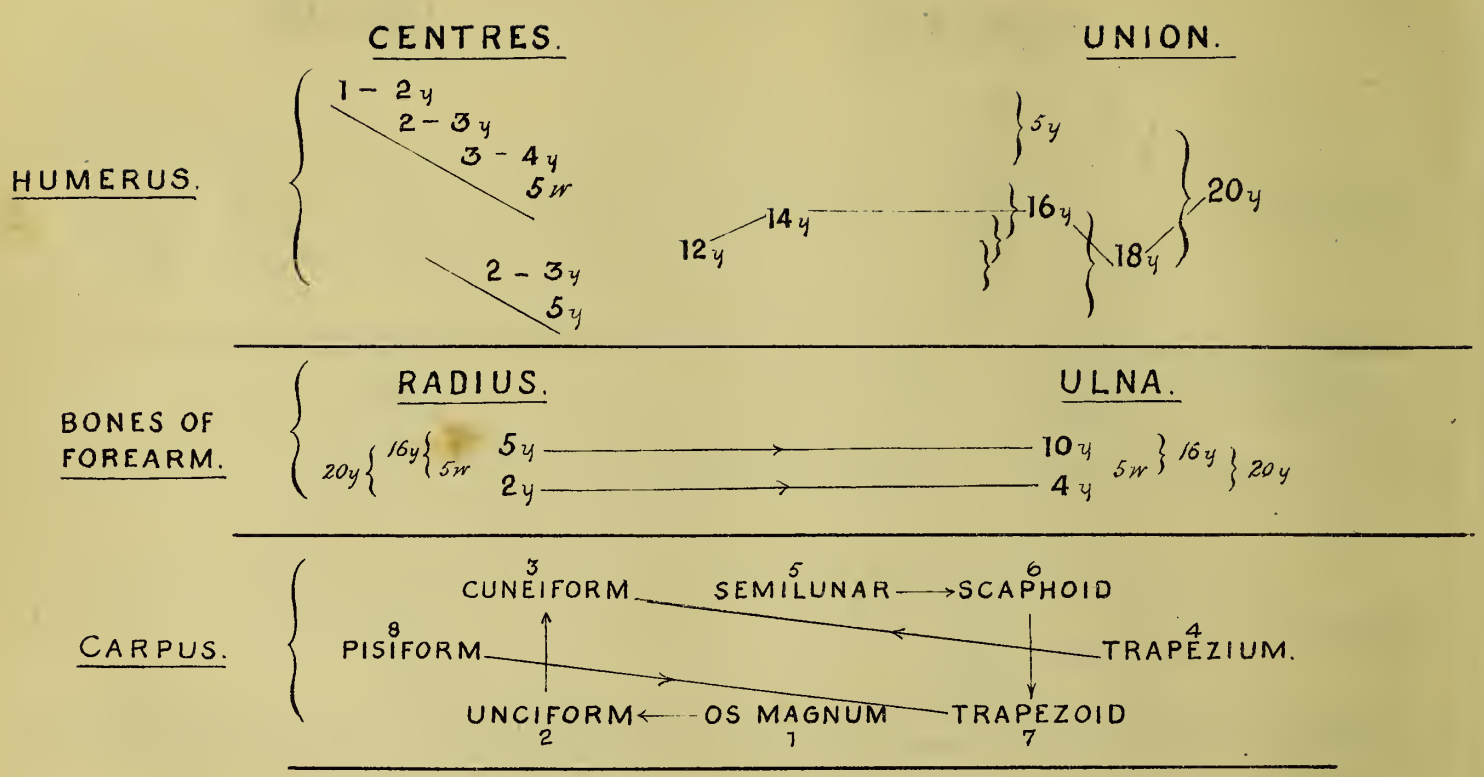
CENTRES.
UNION.
HUMERUS.
1 – 2 y
2 – 3 y
3 – 4 y
5 w
2 – 3 y
5 y
5 y
12 y
14 y
16 y
18 y
20 y
BONES OF FOREARM.
RADIUS.
ULNA.
20 y
16 y
5 w
5 y
2 y
10 y
4 y
5 w
16 y
20 y
CARPUS.
3
CUNEIFORM
5
SEMILUNAR
6
SCAPHOID
8
PISIFORM
4
TRAPEZIUM.
UNCIFORM
2
OS MAGNUM
1
TRAPEZOID
7

Humerus (*Seven* or *Eight* Centres)	Head	appearing 1st—2nd year		uniting at 5th year	uniting at 20th year.
	Great Tuberosity	„ 2nd—3rd year			
	Small „	„ (sometimes) (3rd—4th year)			
	Shaft	„ 5th week	uniting at 16th year	„ at 18th „	
	External Condyle	„ 13th—14th year			
	Trochlea	„ 12th year			
	Capitellum	„ 2nd—3rd year			
	Internal Condyle	„	5th „		

Note that the dates at the upper part and lower part of the table are similar, whilst those intermediately correspond to the even numbers from twelve to twenty.

	Radius.			Ulna.		
Uniting at 16th year	5th year	—	Upper Extremity	—	10th year	uniting at 16th year.
	5th week	—	Shaft	—	5th week	
„ „ 20th year	2nd year	—	Lower Extremity	—	4th year	„ „ 20th year.

Compare the Radius and Ulna with the Tibia and Fibula in regard to Ossification.

Carpus

Os Magnum	in 1st year	—	Cuneiform in 3rd year	—	Trapezium	in 5th year.
Unciform					Semilunar	
Scaphoid	in 6th year	—	Trapezoid in 8th year	—	Pisiform	from 10th to 12th year.

Note that the first bone to ossify is the central bone of the Carpus—the Os Magnum; and that the second is its neighbour, the Unciform—both in the first year; that the third bone to ossify, ossifies in the third year; the fourth and fifth in the fifth, and the sixth in the sixth year. Note also the order as shown in the Diagram, and the sequence of the numbers.

Metacarpus	One Centre for Shaft	appearing	about 6th week	uniting at 20th year.
	„ „ „ Head	„	„ 3rd year	
Phalanges	„ „ „ Shaft	„	„ 1st to 2nd month	„ at 20th year.
	„ „ „ Base	in bones of 1st row,	„ 3rd „ 4th year	
		„ „ „ 2nd and 3rd rows,	„ 4th „ 5th „	

Os Innominatum (*Eight* Centres)

- One for Ilium appearing about 1st or 2nd month
- ,, ,, Ischium ,, ,, 3rd ,,
- ,, ,, Pubes ,, ,, 4th or 5th ,,

} (Rami join at 7th year) } uniting at puberty.

- ,, ,, Crest of Ilium
- ,, ,, Anterior Inferior Spine
- ,, ,, Symphysis Pubes
- ,, ,, Tuber Ischii
- ,, ,, Y-shaped piece in Acetabulum

} appearing at puberty ,, with other parts by 25th year

Femur

Lower Extremity	appearing	just before birth (beginning of 1st year)	uniting at 20th year.
Head	,,	end of 1st year (,, ,, 2nd ,,)	,, ,, 18th ,,
Great Trochanter	,,	4th ,,	,, ,, ,,
Shaft	,,	5th week—ossifying next after Clavicle	,, ,, ,,
Small Trochanter	,,	at puberty	

Patella appearing about 3rd year.

	Tibia.		Fibula.	
Uniting at 25th year	At birth—(1st year)	Upper Extremity	4th year	uniting at 25th year.
,, ,, 20th year	5th week	Shaft	5th week	,, ,, 20th ,,
	2nd year	Lower Extremity	2nd year	

Tarsus

Astragalus	6th month.	External Cuneiform	1st year.
Calcaneum	7th ,,	Internal ,,	(2) 3rd ,,
Cuboid	(8) 9th ,,	Middle ,,	4th ,,
Scaphoid	4th to 5th year.		
Tubercle on Os Calcis	10th ,,		

Compare with the Carpus, and see Diagram.

Metatarsus and Phalanges.

These Bones ossify similarly to, but a little later than the corresponding Bones in the Hand, the first Metatarsal is like a Phalanx in development.

N.B.—*The numbers printed in Block Type have in each case some relation to one another.*

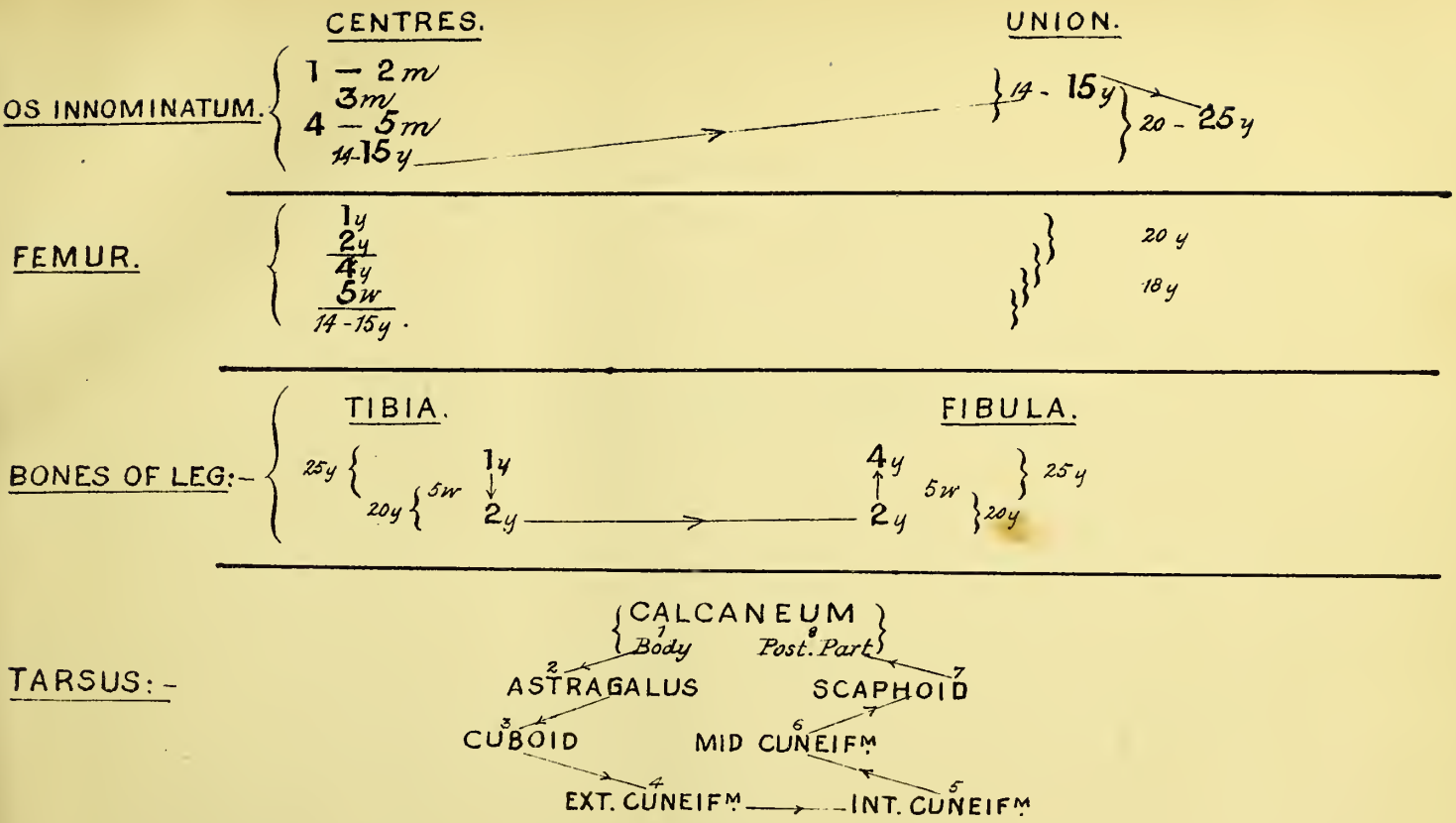

In the Table on p.48 the Astragalus and Calcaneum have been transposed. The centre for the Calcaneum appears in the 6th month, and that for the Astragalus in the 7th.—

LIGAMENTS.

There are *three* groups, each sub-divisible into *three*.

COMMON LIGAMENTS Three,—each *single*

- **Supraspinous** (a)—over Spinous Processes, attached to *apices*, from Sacrum to 2nd Cerv.
- **Post. Common** (b)— „ Bodies posteriorly „ „ *margins* of Bodies and Intervertebral Discs „ „ „ Occipital.
- **Ant. Common** (c)— „ „ anteriorly „ „ ditto „ Sacrum to 2nd Cerv.
- (a)—broader *below* than above; (b)— „ *above* „ below; (c)— „ *below* „ above — consisting of *superficial* fibres joining several Vertebræ; *intermediate* „ „ two or three „; *deep* „ „ contiguous „

INTERVERTEBRAL Three { one *single* Lig. „ *pair* of Ligs.

- **Intervertebral Disc** (a)—between contiguous Bodies *increasing* in thickness from above downwards. of *uniform* depth in the Dorsal Region. *deeper* in front than behind in the other Regions.
- **Two Ligamenta Subflava** (b)— „ „ Laminæ, *increasing* in strength from above downwards.
- (a)—adherent to surrounding Ligaments —consisting of *circumferential* concentric fibrous laminæ; *central* globular elastic pulp.
- (b)—attached to { upper *edge* of Lamina below; inner *surface* „ „ above } „ „ elastic tissue with fibres vertical.

LIGAMENTS OF PROCESSES Three *pairs*

- **Interspinous**, rudimentary in the Cervical Region, narrow in the Dorsal, broad and strong in the Lumbar.
- **Intertransverse**, „ „ „ „ band-like „ „ membranous „ „
- **Capsular**, long and loose „ „ „ shorter and firmer in the Dorsal and Lumbar.

Movements

- *Flexion* is most free in the lower Lumbar Region, less so in the Cervical, nearly impossible in the Dorsal.
- *Extension* / *Lateral movement* „ „ „ „ upper Cervical „ „ „ „ Lumbar, „ „ „ „
- *Rotation* „ „ „ „ „ Dorsal „ „ „ „ Cervical, „ „ Lumbar.

OCCIPITO-ATLOID AND ATLO-AXOID LIGAMENTS.

- **Anterior Occipito-atloid**, —from Anterior Arch of Atlas to Anterior Margin of For. Magnum
- **Anterior Atlo-axoid**, — „ „ „ „ „ „ „ „ Body of Axis } each double { cord-like in mid-line. membranous laterally.
- **Posterior Occipito-atloid**,— „ Posterior „ „ „ Posterior „ „ For. Magnum*
- **Posterior Atlo-axoid**, — „ „ „ „ „ Superior „ „ Arch of Axis† } each membranous.
- **2 Capsular (Occip.-atloid)** / „ „ **(Atlo-axoid)** } surrounding each pair of Articular Processes, thin, loose, and strong externally.
- **2 Lateral Occipito-atloid**,—cord-like, from root of Transverse Process of Atlas to Jugular Process of Occipital Bone.

Movements

- *Rotation* of the Head is produced by movement of the Atlas on the Axis.
- *Nodding* „ „ „ „ „ „ „ Occipital Bone „ Atlas.
- *Lateral Movement* „ „ „ „ „ „ „ Cervical Vertebræ.

* Vertebral Artery and Sub-occipital Nerve pass beneath it. † Second Cervical Nerve passes beneath it.

OCCIPITO-AXOID LIGAMENTS.

Four in number, lying superposed in the Spinal Canal, over the posterior surface of the Odontoid Process.

Post. Common,	—broad, attached	*below*	to Body of Axis	(lower border of posterior surface).
Occipito-axoid,	—cord-like ,,	,, ,, ,, ,,	,,	(upper part ,, ,, ,,).
Transverse,	—cruciform ,,	laterally ,, *below* ,,	Atlas Odontoid Process	(to Tubercles on Lateral Masses), by transverse part. (,, root), ,, vertical ,,
Odontoid,	—triple ,,	,, ,, ,, ,,	,,	(,, apex), ,, central fasciculus. (,, sides of apex), ,, 2 lateral fasciculi.

Above all four are attached to the Basilar Process and the margin of the Foramen Magnum, the lateral Odontoid bands being fixed to special depressions on the sides of the Foramen.

The Transverse Ligament is separated from the facet on the posterior surface of the Odontoid Process by a synovial membrane. It also aids in uniting the Atlas and Axis.

VERTEBRO-COSTAL LIGAMENTS.

A Rib articulates { by its Head with the Bodies of two contiguous Dorsal Vertebræ and the intermediate Intervertebral Disc.
{ ,, ,, Tubercle ,, ,, extremity of the Transverse Process of the lower of the two Vertebræ.

In each joint it is retained by *three* Ligaments.

LIGAMENTS UNITING HEADS OF RIBS AND VERTEBRÆ.

Stellate,*	—triple, attached exter. to front of Head of Rib, and inter. to Intervertebral Disc and Bodies of contiguous Vertebræ.
Interarticular,*	—short ,, ,, ,, ridge on ,, ,, ,, ,, ,, ,, ,,
Capsular,	—thin and loose, surrounding joint.

LIGAMENTS UNITING RIBS AND TRANSVERSE PROCESSES OF VERTEBRÆ.

Ant. Costo-transverse	—broad, strong, attached to upper border	of Neck	of Rib, and to lower border	of Transverse Process above.	
Middle ,,	—short ,, ,, ,, posterior surface	,, ,,	,, ,, ,, anterior surface	,, ,,	,, adjacent.
Posterior ,,	— ,, ,, ,, ,, non-articular part	,, Tubercle	,, ,, ,, apex	,, ,,	,, ,,

The Anterior Ligament	is deficient in the case of the	1st Rib.
The Middle and Posterior Ligaments	are ,, ,, ,, ,,	11th ,,
All three Ligaments	,, ,, ,, ,, ,,	12th ,,

A *Capsular* Ligament is also described as surrounding the Joint.

* In the case of those Joints in which the Rib articulates with one Vertebra only, the *Stellate Ligament* consists of but two parts (one connected with the articulating Vertebra, the other with the Vertebra above), and the *Interarticular Ligament* is absent.

LIGAMENTS OF VERTEBRÆ.



Intervertebral Lig.ts

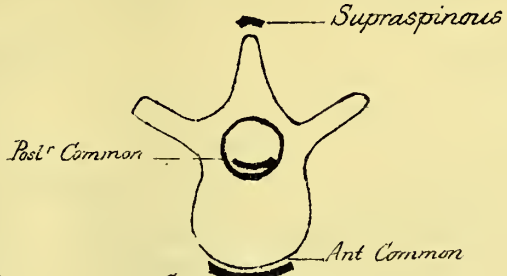

Common Lig.ts

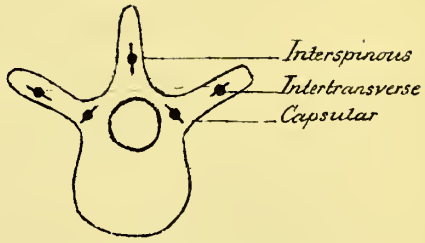

Lig.ts of Processes

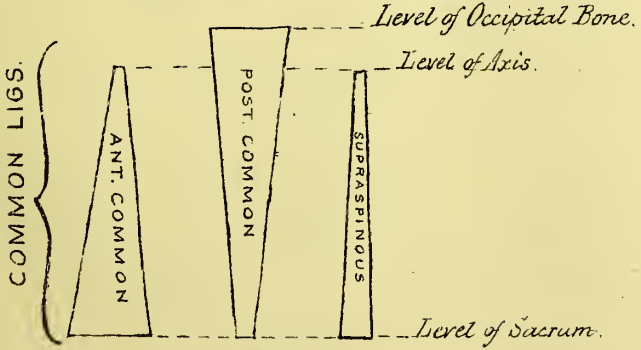

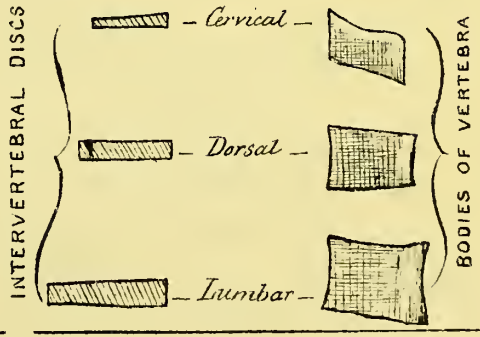

ATLO-AXOID LIGAMENTS.

ATLAS.—*Under Surface.*

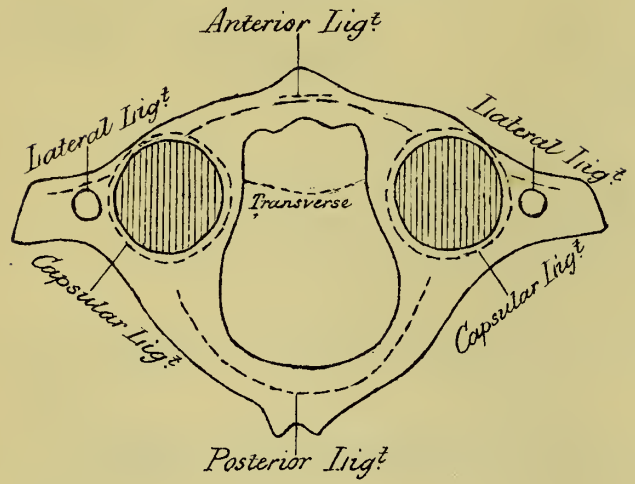

Anterior

Lateral Capsular *Lateral Capsular*

Posterior

OCCIPITO-ATLOID LIGAMENTS.

ATLAS.—*Upper Surface.*

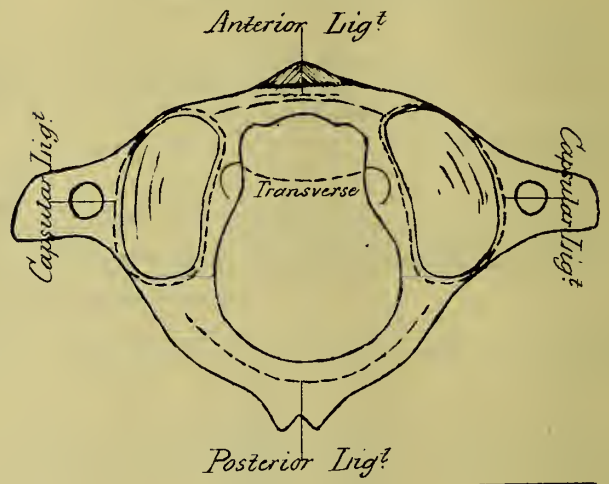

Anterior

Capsular *Capsular*

Posterior

Anterior, —like Stellate, radiating over Sternum from front of Cartilage.

Posterior, — ,, ,, ,, ,, back ,, ,,

Capsular, —very thin, surrounding the Joint.

Synovial Cavities —

The 1st Cartilage	is continuous with the Sternum	*without* intervening Cavity.	
,, 2nd ,,	articulates ,, ,, ,,	by a *double* Joint, with Interarticular Cartilage.	
,, Cartilages from the 3rd to the 7th	articulate ,, ,, ,,	,, *single* Joints, without	,, ,,

The 3rd Articulation is sometimes double.
In old age the Synovial cavities disappear.

The **Costo-xiphoid** Ligament unites the 7th Costal Cartilage with the Xiphoid Cartilage anteriorly.

INTERCHONDRAL AND STERNAL LIGAMENTS.

The Cartilages of the last true Rib (the 7th) and of the Ribs on either side of it (the 6th and 8th) articulate with each other by small synovial joints midway between their extremities.

The Ribs and Cartilages are directly continuous with each other.

The Sternum ,, Xiphoid Cartilage ,, ,, ,, ,, ,, ,,

The 2nd piece of the Sternum is usually united with the 1st by a fixed Joint.

STERNO-CLAVICULAR LIGAMENTS.

Anterior,	—broad,	attached	to contiguous anterior surfaces of Sternum and Clavicle.
Posterior,	— ,,	,,	,, ,, posterior ,, ,, ,, ,, ,,
Interartic. Fibro-cart.	—a flat disc	,,	*above* to upper part of articular surface of Clavicle. *below* ,, junction of Cart. of 1st Rib and Sternum. *in front and behind* ,, Ligaments of Joint.

ACROMIO-CLAVICULAR LIGAMENTS.

Interartic. Fibro-cart.,	—a flat disc,	attached	by circumference to Ligaments of Joint only, often imperfect.
Superior,	—broad	,,	to contiguous upper surfaces of Acromion and Clavicle.
Inferior,	— ,,	,,	,, ,, lower ,, ,, ,, ,, ,,

Compare Acromio- and Sterno-clavicular Ligaments.

INTERCLAVICULAR LIGAMENT.

Interclavicular,	—a strong band,	attached	*at extremities* to non-articular surfaces of Sternal Ends of Clavicles. *intermediately* ,, upper edge of Manubrium Sterni.

COSTO-CLAVICULAR LIGAMENT.

Rhomboid,	—short and strong,	attached	*below* to Cartilage of 1st Rib. *above* ,, Rhomboid Depression on Clavicle.

CORACO-CLAVICULAR LIGAMENTS.

Trapezoid,	—quadrilateral, horizontal,	attached	*below* to inner half of anterior border of Coracoid Process. *above* ,, oblique line on under surface of Clavicle externally.
Conoid,	—conical, vertical	,,	*below* by apex, to inner side of base of Coracoid Process. *above* to Conoid Tubercle and contiguous border of Clavicle.

CORACO-ACROMIAL LIGAMENT.

Coraco-acromial,	—triangular, with thick edges,	attached	*by apex* to summit of Acromion Process. ,, *base* ,, posterior border of Coracoid ,,

LIGAMENTS OF CLAVICLE.

CORACO-ACROMIAL	ACROMIO-CLAVIC	CORACO-CLAVIC	COSTO-CLAVIC	STERNO-CLAVIC	INTERCLAVIC.
Coraco-acromial	Superior Interartic. Cart. Inferior	Trapezoid & Conoid	Rhomboid	Anterior Interartic. Cart. Posterior	Interclavicular.

FIBRO-CARTILAGES.

Of Acromial Joint.

Acromion — Clavicle

Interart. Fibro. Cart

Of Sternal Joint.

Interart. Fibro-Cart.



ATTACHMENT OF LIGAMENTS ETC:

round CORACOID PROCESS.

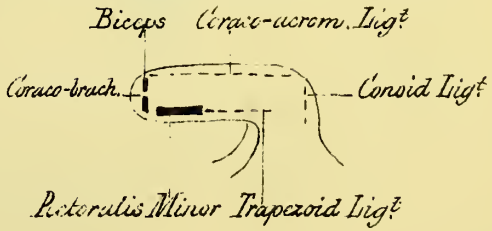

SHOULDER-JOINT

RELATION OF LIGAMENTS ETC.

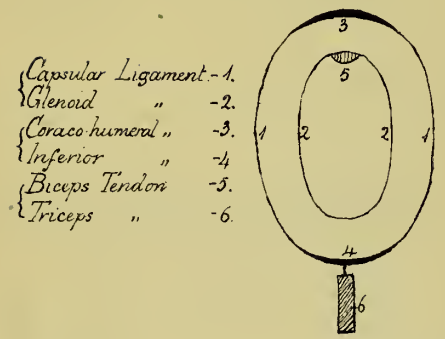

RELATION OF BURSÆ.

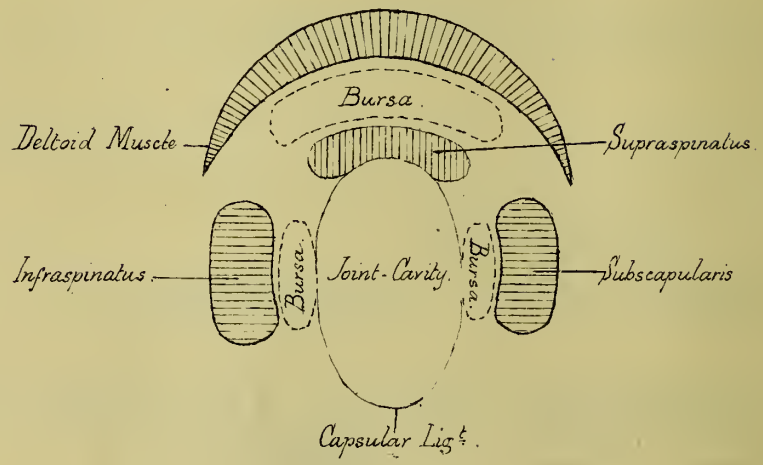

Capsular, —cylindrical, loose, thin, attached { *above* to margin of Glenoid Cavity external to Glenoid Ligament. *below* ,, Anatomical Neck of Humerus.

Coraco-humeral, —a thickened band in Capsule *above*, lying over long head of Biceps, attached to { outer side of root of Coracoid Process. upper edge ,, Gt. Tuberosity of Humerus.

Inferior, — ,, ,, ,, *below*, united with ,, ,, Triceps.

Glenoid, —a cartilaginous ring within ,, ,, ,, ,, ,, Biceps, attached to margin of Glenoid Cavity.

Bursæ (three), { One *in front*, under Subscapularis Tendon, *always* communicating with Joint. ,, *behind*, ,, Infraspinatus ,, *sometimes* ,, ,, ,, ,, *above*, ,, Deltoid Muscle, *never* ,, ,, ,, separated by Supraspinatus.

There is also an opening in the Capsule for the Tendon of the Biceps, which latter is surrounded by a reflection of Synovial Membrane.

Movements, —in every direction, supplemented by movements of the Scapula, regulated chiefly by Muscles (which see).

LIGAMENTS OF ELBOW JOINT.

Anterior, —thin, attached { *above* to margin of Coronoid Fossa and Internal Condyle *below* ,, ,, ,, Process and Orbicular Ligament } the *superficial* fibres are oblique. ,, *intermediate* ,, ,, transverse. ,, *deep* ,, ,, vertical.

Posterior, — ,, loose ,, { *above* ,, upper part of Olecranon Fossa *below* ,, margin ,, ,, Process } ,, ,, ,, ,, ,, ,, *superficial* ,, ,, transverse.

Internal Lateral,—triangular ,, { *above* ,, Internal Condyle of Humerus *below*, ant. to Coronoid Proc., post. to Olecranon Proc., intermediately to fibrous band between them.

External Lateral,— ,, narrow ,, { *above* to External Condyle of Humerus. *below* ,, Orbicular Ligament and outer margin of Ulna.

The Synovial Membrane is prolonged into Radio-ulnar Joint.

SUPERIOR ARTICULATION.

Orbicular,	—a flat band	attached by ends to extremities of Lesser Sigmoid Cavity. encircling Head of Radius—more tightly below than above—lined by Synovial Membr. of Elbow-joint.

MIDDLE ARTICULATION

Round Ligament	—cord-like	passing from Tubercle of Ulna *down and out* to Radius just below Tuberosity, having Tendon of Biceps *above* it, and Posterior Interosseous Vessels *below* it.
Interosseous Membrane	fibrous	passing from the bone more supported below (Radius) *down and in* to the bone less supported below (Ulna).* united by margins to Interosseous Borders of Radius and Ulna. The Anterior Interosseous Artery perforates it *below*. „ Posterior „ „ passes backwards *above* between its upper border and the Round Lig.

INFERIOR ARTICULATION.

Anterior,	—narrow,	passing from *anterior* margin of Sigmoid Cavity of Radius to anterior surface of Head of Ulna.
Posterior,	— „	„ „ *posterior* „ „ „ „ „ posterior „ „ „
Triangular Cartilage	attached	*by apex* to depression in front of Styloid Process of Ulna. „ *base* „ ridge between Ulnar and Carpal articular surfaces of Radius.

The Synovial Membrane (Membrana Sacciformis) is distinct from (sometimes continuous with) that of Wrist Joint.

LIGAMENTS OF WRIST JOINT.

Anterior Posterior	membranous, passing from Radius and Fibro-cartilage *down and in* to Bones of 1st Row of Carpus.
External Lateral	—short, strong „ „ Styloid Process of Radius to Scaphoid and Trapezoid and to Anterior Annular Ligament.
Internal Lateral	— „ „ „ „ „ „ „ Ulna „ Cuneiform „ Pisiform „ „ „ „

The Synovial Membrane is single, and sometimes continuous with Membrana Sacciformis.

The chief fibres of the Anterior Ligament of the Elbow Joint and those of the Round Ligament are directed down and *out*, whereas those of the Interosseous Membrane and the Anterior and Posterior Ligs. of Wrist „ „ „ „ *in*.

* As in lower Extremity.

RADIO-ULNAR JOINTS ETC.

Direction of Fibres of Ligts

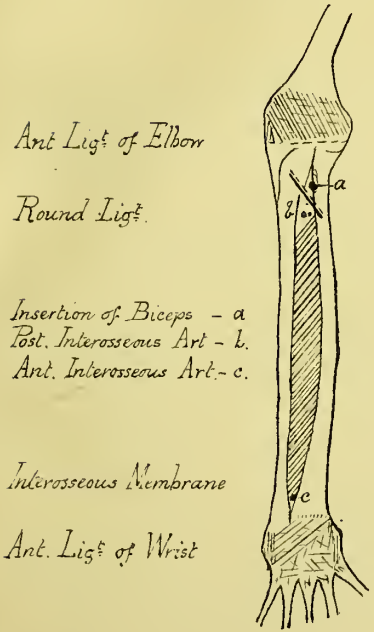

CARPO-METACARPAL LIGTs.

Direction of Fibres.



PALMAR LIGTS:



DORSAL LIGTS:

LIGAMENTS OF EACH ROW.

Palmar
Dorsal } short bands passing between contiguous bones.

Interosseous
- 2 in 1st Row, one on each side of the Semilunar Bone, passing to Scaphoid and Cuneiform.
- 2 „ 2nd „ „ „ „ Os Magnum „ „ Trapezoid „ Unciform.

The Pisiform Bone is united to the Cuneiform by a Capsule lined by synovial membrane.

LIGAMENTS BETWEEN THE TWO ROWS.

Palmar
Dorsal } short bands, passing between contiguous bones.

Lateral
- External, the stronger „ „ Scaphoid and Trapezium.
- Internal, „ weaker „ „ Cuneiform „ Unciform.

The Common Synovial Membrane, between the 1st and 2nd Rows, sends prolongations between the contiguous bones in each Row, and is prolonged below into the four inner Carpo-metacarpal Joints.

LIGAMENTS OF CARPO-METACARPAL JOINTS.

The First Joint (that of the Thumb), is a Special Joint with its own Capsule and Synovial Membrane.

In the other Carpo-metacarpal Joints, the Ligaments are as follow :—

Dorsal
- The 2nd and 4th Metacarpal Bones each receive two fasciculi
  - the 2nd from Trapezium. Trapezoid.
  - „ 4th „ Os Magnum. Unciform.
- The other Bones each receive one fasciculus, the 3rd from Os Magnum, the 5th from Unciform.

Palmar, —as in Dorsal, except that the 3rd has two extra bands, one from Trapezium, the other from Unciform.

Interosseous
- single, between contiguous inferior margins of Os Magnum and Unciform, and Ulnar side of Base of 3rd Metacarpal.
- This Ligament sometimes isolates the cavity of the Joint between Unciform and 4th and 5th Metacarpals from the Common Synovial Cavity.

LIGAMENTS OF INTERMETACARPAL JOINTS.

The Bases are united by **Dorsal, Palmar** and **Interosseous Ligaments.**

,, Digital Extremities ,, ,, by the **Transverse Ligament,** which is connected with ant. surfaces of Metacarpo-phalangeal Joints

LIGAMENTS OF METACARPO-PHALANGEAL AND INTERPHALANGEAL JOINTS.

Anterior { Fibro-cartilaginous, connected with Base of Bone *below,* free over head of Bone *above.*
{ grooved *in front* for Flexor tendons, united *laterally* with Lateral Ligaments.

Posterior, —deficient, its place being taken by Extensor Tendon.

Lateral, —strong, cord-like, between lateral surfaces of contiguous bones

In the Hand, the smaller Member, there are 5, sometimes 6 **Synovial Cavities.**
,, Foot ,, larger ,, ,, 6 ,, 7 ,, ,,

LIGAMENTS OF THE SACRO-ILIAC JOINT.

Anterior, —thin, irregular, connecting contiguous anterior surfaces of Sacrum and Ilium.

Posterior, —strong „ „ surface of Ilium above Auricular Facet with the 1st, 2nd and 3rd Posterior Transverse Processes of Sacrum.

A special band from the Post. Sup. Spine of Ilium to the 3rd Post. Transverse Process of Sacrum is called the Oblique Sacro-iliac Ligament. There is no joint cavity, the apposed surfaces being united by fibro-cartilage.

Lumbo-sacral, —horizontal, triangular, between Transverse Proc. of 3rd Lumbar Vertebra to Ant. Sacro-iliac Lig. and side of Sacrum.

Ilio-lumbar, —oblique, „ „ „ „ „ „ „ „ „ „ „ contiguous part of Crest of Ilium.

Great Sacro-sciatic—triangular { attached *in front* by *apex* to Tuber Ischii (inner margin).
„ *behind* „ *base* „ margins of 4th & 5th Pieces of Sacrum and Coccyx, & Post. Inf. Iliac Spine.

Small „ „ — „ { „ *in front* „ *apex* „ Spine of Ischium.
„ *behind* „ *base* with Great Sacro-sciatic Ligament.

LIGAMENTS OF SACRO-COCCYGEAL JOINT.

Anterior and Posterior } with interposed **Fibro-cartilage.**

LIGAMENTS OF SYMPHYSIS PUBIS.

Anterior
Posterior
Superior } Irregular, passing between corresponding surfaces of Pubic Bones, united with Cartilage of Joint. The Anterior ligament is strong, blended with the Aponeuroses of the Oblique Muscles; the others are weak, with scattered fibres.

Sub-pubic, —thick, triangular, yellowish, attached *laterally* to margins of Pubic Arch, and *above* to Fibro-cartilage.

Fibro-cartilage { lies between apposed surfaces of Symphysis Pubis; composed of two layers, separated *below and in front* by fibrous tissue, *above and behind* by a rudimentary Synovial Cavity.

LIGAMENTS OF HIP-JOINT.

CAPSULAR, —attached { *superiorly*, round Acetabulum, to margin *below* and ¼ inch beyond margin *above*.
inferiorly, to Ant. Intertrochanteric Line *in front* „ to middle of Neck of Femur *behind*.

- **Ilio-trochanteric**—very strong, connected with reflected head of Rectus int., and tendon of Gluteus Minimus and Gt. Trochanter ext.
- **Ilio-femoral,** —Y-shaped { attached to the Anterior Inferior Spine *above*, and to the Anterior Intertrochanteric line *below*.
the upper edge being blended with the Ilio-trochant. Lig., and the lower edge with the Pubo-femoral Lig.
- **Pubo-femoral,** —narrow, attached to Pubes in front of Ilio-pectineal Eminence *above*, and to Femur in front of Small Troch. *below*.
- **Ischio-capsular,** —semicircular { ¼ inch wide, in lower edge of Capsule posteriorly.
united by *extremities* with the Pubo-femoral band below, and the Ilio-trochanteric above.
„ „ *lower border* loosely with mid-line of Neck of Femur behind.
„ „ *upper* „ with Capsule and Ischium.

COTYLOID, —fibro-cartilaginous, attached round margin of Acetabulum within Capsule.

Transverse, —crossing Cotyloid Notch, being a continuation of Cotyloid Ligament, supported by ligamentous fibres.

LIGAMENTUM TERES { Y-shaped, attached by *apex* to Notch on Head of Femur, by *base* to opposite sides of the Fossa in the floor of the Acetabulum.

The **Synovial Membrane** covers the internal surface of the Capsule and the Neck of Femur as far as the attachment of Capsule, and is reflected over both surfaces of the Cotyloid Ligament, the Ligamentum Teres and the Gland of Havers.

MOVEMENTS

Extension	is limited by Ilio-femoral Ligament.
Abduction	„ „ „ Pubo-femoral „
Adduction	„ „ „ Ilio-trochanteric „
Flexion	is not limited, except by meeting of soft parts.
Rotation out	is limited by front of Capsule.
„ **in**	„ „ „ back „ „

HIP - JOINT.

ACCESSORY LIGAMENTS OF CAPSULE:-A. *In front* B. *Behind.*

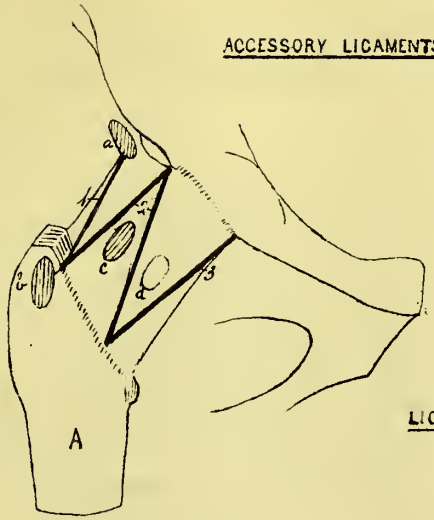

1.-Ilio-trochanteric Lig^t
2.-Ilio-femoral "
3.-Pubio-femoral "
4.-Ischio-capsular "

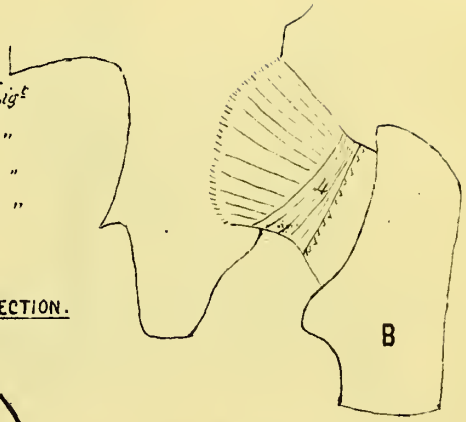

LIG^TS ON TRANSVERSE SECTION.

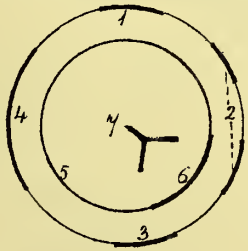

a.-Rectus (Reflected Head).
b.-Gluteus Minimus. (Insertion).
c.-Iliacus (Fibres from Capsule).
d.-Bursa under Psoas.

1, 2, 3 & 4 as above.
5.-Cotyloid Lig^t.
6.-Transverse " .
7.-Ligamentum Teres.

KNEE-JOINT.

POSTERIOR LIGT, ETC.

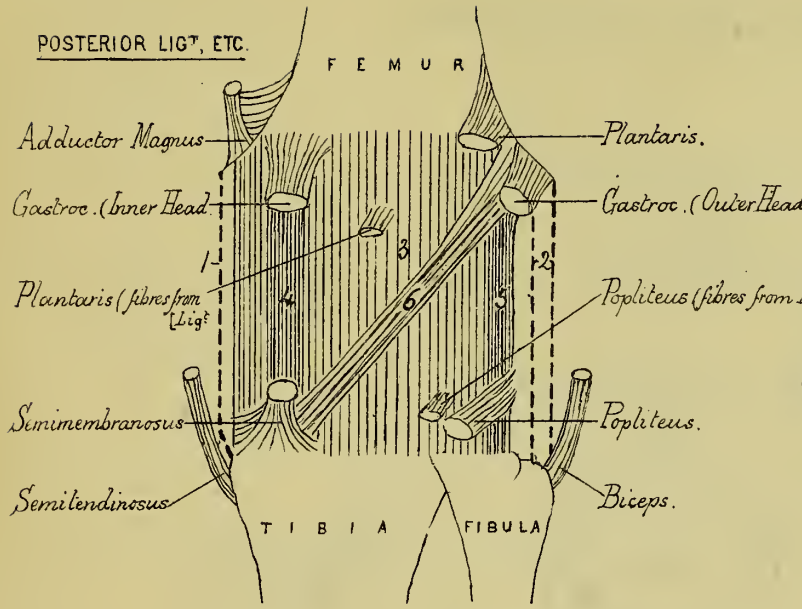

CAPSULAR LIGAMENT, ETC.

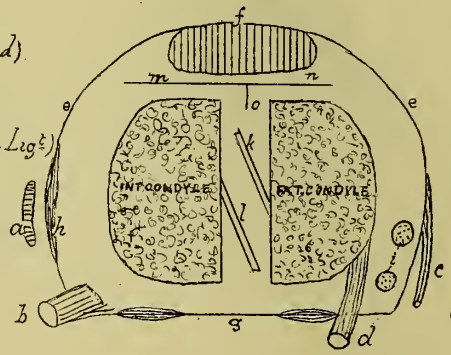

a.-Semitendinosus
b.-Semimembran.s
c.-Biceps.
d.-Popliteus.

1.-Internal Lat. Ligts
2.-External " Ligts
3.-Posterior Ligament.
4.-Offset from Gastroc. (Inner Head).
5.-" " (Outer ").
6.-" Semimembranosus.

e.-Capsular Ligament.
f.-Anterior " .
g.-Posterior "
h.-Int. Lat. "
i.-Ext " Ligaments.
k.-Ant. Crucial Ligts
l.-Post. " "
m.-Int. Alar "
n.-Ext. " "
o.-Mucous "

EXTERNAL LIGAMENTS.

Internal Lateral, —a flat band, attached { above to Internal Tuberosity of Femur.
below ,, ,, ,, ,, Tibia, and to contiguous part of Bone.

External Lateral, —a round cord ,, { above ,, External ,, ,, Femur.
below ,, ,, side of Head of Fibula.

Short Ext. Lateral,—(posterior to Long Ext. Lat.) ,, { above ,, Outer Head of Gastrocnemius.
below ,, Styloid Process of Fibula.

Under the Internal Lateral Ligament are the Tendon of the Semi-membranosus and the Int. Inf. Articular Artery.
,, ,, External ,, ,, ,, ,, ,, Popliteus ,, ,, Ext. ,, ,, ,,
Over ,, Internal ,, ,, ,, Tendons ,, Sartorius, Gracilis and Semitendinosus.
In front and behind the attachment of the Long Ext. Lateral Ligament is inserted the Tendon of the Biceps.

Anterior (Ligamentum Patellæ or Tendon of Quadriceps Extensor) attached *above* to Apex of Patella and contiguous part of Posterior Surface.
,, *below* ,, lower part of Tubercle of Tibia.

Posterior, —triple { 2 lateral parts, vertical ,, *above* ,, Heads of Gastrocnemius, *below* to Tuberosities of Tibia posteriorly.
1 central part, oblique ,, ,, ,, outer head of ,, ,, ,, Tendon of Semi-membranosus.

The intervals between the parts are closed by irregular fibres.
To the Posterior Ligament are attached the Plantaris and Popliteus Muscles.

Capsular { Fills intervals between the other External Ligaments, and is strengthened by reflections from Fascia Lata and surrounding Tendons.
continuous with anterior border of Internal Lateral Ligament.
closely connected with anterior surface of Anterior ,,
passing free over outer ,, ,, External Lateral Ligament,
and continued into ,, border ,, Posterior Ligament.

The Capsule with the Posterior Ligament thus makes one turn of a spiral.
Between the inner border of Posterior Lig., and the posterior border of Int., Lateral Lig the tendon of Semi-membranosus is inserted.

INTERNAL LIGAMENTS.

Anterior Crucial, —oblique, attached *below* to surface in front of Spine of Tibia, *above* to inner surface of Outer Condyle of Femur.
Posterior Crucial, —vertical ,, ,, ,, Popliteal Notch of Tibia ,, ,, outer ,, ,, Inner ,, ,, ,,

Semilunar Cartilages

External, —nearly circular
- attached on opposite sides of Spine of Tibia.
- connected *anteriorly* with Internal Semilunar Cartilage by Transverse Ligament.
- ,, *posteriorly* ,, Posterior Crucial Ligament by a single or double band.

Internal, —semicircular
- attached *anteriorly* to Tibia in front of origin of Anterior Crucial Ligament.
- ,, *posteriorly* ,, ,, ,, ,, ,, ,, Posterior ,, ,,

Both Cartilages are connected laterally with the margins of Head of Tibia by **Coronary Ligaments.**

THE FAT round the Patella is divided into
- **Suprapatellar** Pad under Extensor Tendon.
- **Infrapatellar** ,, ,, Patellar Ligament, prolonged beyond margins of Patella, chiefly on inner side.

SYNOVIAL MEMBRANE
- *lines* Capsule and subjacent Fat and is prolonged into *six* pouches.
- beneath Tendon of Quadriceps Extensor *above and in front.*
- ,, Aponeuroses of Vasti *laterally.*
- ,, Heads of Gastrocnemius *above and behind.*
- ,, Tendon of Popliteus *below and externally.*
- *invests* also Semilunar Cartilages and Crucial Ligaments.

Ligamentum Mucosum
- A fold of synovial membrane reflected from over Infrapatellar Pad, round a small vessel to the front of the Intercondyloid Notch.

Alar Ligaments (3)
- Folds of synovial membrane extending transversely, one inwards and one outwards, over the Infrapatellar Pad beyond margins of Patella. The Internal is the larger.

MOVEMENTS
- **Flexion** and **Extension** are the chief movements.
- Towards the end of Extension there is **Rotation out,** in consequence of the Curve of the Articular surf. of Int. Condyle.
- In Semiflexion, **Rotation in and out** are allowed in consequence of relaxation of Ligaments.
- The **Patella,** during *Flexion,* is sunk in the Intercondyloid Notch, on the lower and outer part of the Joint; during *Extension* it moves upwards and inwards, becoming prominent above the articular surface of Femur.
- The **Crucial Ligaments** limit flexion and extension, and prevent displacement forwards and backwards.
- The Anterior Crucial Ligament limits Rotation in.
- The **Internal Lateral** ,, ,, ,, out.
- **All the Ligaments,** except the Anterior, are made tense in Extension.
- The **Semilunar Cartilages** follow the Tibia, moving forwards in Extension, backwards in Flexion.

KNEE-JOINT.

PATELLAR BURSÆ.

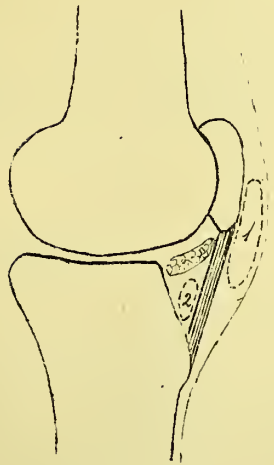

1.-Suprapatellar Bursa (Bursa Patellæ)
2.-Infrapatellar Bursa.

SEMILUNAR CARTILAGES, ETC.

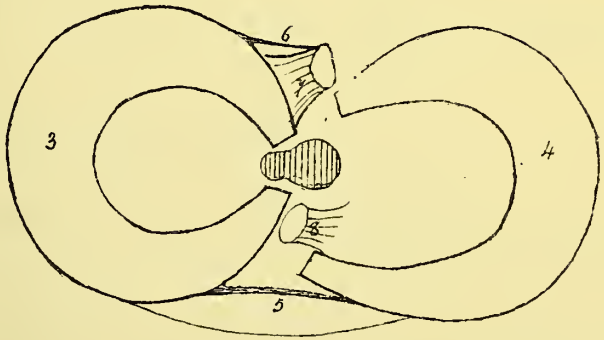

3.- External Semilunar Cartilage
4.- Internal " "
5.- Transverse Ligament.
6.- Special Band to Post. Crucial.
7.- Post. Crucial Lig.t
8.- Ant. " "

TIBIO-FIBULAR LIG^TS ETC.



1. Post. Inf Tibio-fibular Lig^t
2. Post Lig^t of Ankle-joint.
3. Post. Fasciculus of Ext. Lat. Lig^t

TARSO-METATARSAL LIG^TS.

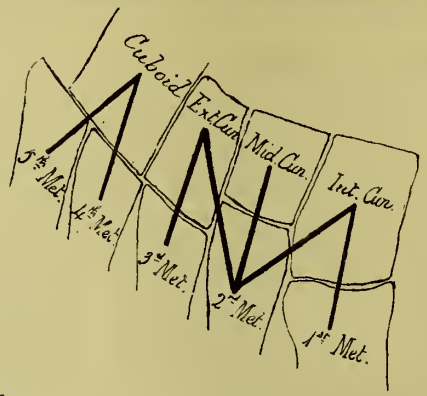

DORSAL.



PLANTAR.

BURSÆ (6 or 7)

- **Bursa Patellæ,** superficial, over lower half of Patella and upper half of Ligamentum Patellæ.
- **Infrapatellar Bursa,** deep, between Ligamentum Patellæ and upper part of Tubercle of Tibia, separated from Joint by Infrapatellar Pad of Fat.
- **Bursa over Internal Lateral Lig.,** between it and the Tendons of Sartorius, Semitendinosus and Gracilis.
- ,, **under External** ,, ,, ,, ,, ,, Tendon of the Popliteus, communicating with Joint.
- **A Bursa** *anteriorly,* under Tendon of Quadriceps, frequently communicating with Joint.*
- **Two Bursæ** *posteriorly* ,, Heads of Gastrocnemius, generally ,, ,, ,,

* This Bursa often blends with the Pouch of Synovial Membrane prolonged upwards from the Joint. The number of Bursæ corresponds to the number of Synovial Pouches.

In each of the pairs of structures connected with the Knee-joint the inner structure is the larger, except in the case of the pair most superficial (the lateral parts of the Capsule or the Retinacula) and the pair most deep (the articular surfaces of the Condyles of the Femur).

LIGAMENTS OF TIBIA AND FIBULA.

UPPER ARTICULATION.

Anterior and **Posterior,** —broad bands between corresponding surfaces of upper ends of Tibia and Fibula.

A single **Synovial Membrane** lines the Joint, which is often continuous with that of Knee-Joint.

MIDDLE ARTICULATION.

Interosseous Membrane
- between Interosseous Borders of Tibia and Fibula.
- Fibres pass *down and out* from Tibia, the bone most supported below.
- Perforated *above* for Anterior Tibial Artery, *below* for Anterior Peroneal Artery

(Compare with Interosseous Membrane of Forearm.)

INFERIOR ARTICULATION.

Anterior and **Posterior,** —between corresponding surfaces of lower ends of Tibia and Fibula.

Inferior, —transverse— ,, pit on inner side of External Malleolus and lower margin of Tibia posteriorly.

Interosseous,
- ,, apposed rough surfaces of lower ends of Tibia and Fibula,
- continuous with Interosseous Membrane.

Anterior, —membranous, between lower edge of Tibia and upper surface of neck of Astragalus.
Posterior, —transverse, Y-shaped, from pit on inner side of External Malleolus to posterior margins of Tibia and Astragalus.
Internal Lateral,—(Deltoid), from border of Internal Malleolus to Scaphoid, Os Calcis (Lesser Process) and Astragalus.

Deeper fibres pass from the apex of the Malleolus to the inner surface of the Astragalus.

External Lateral—triple
- Anterior Fasciculus, *shortest*, from anterior margin of Ext. Malleolus to Astragalus in front of ext. Facet.
- Middle ,, *longest* ,, apex ,, ,, ,, ,, Os Calcis, about middle of ext. surface.
- Posterior ,, *strongest* ,, pit on int. surf. ,, ,, ,, ,, Astragalus (posterior border).

Four bands cross the back of the Joint
- *above*, Posterior Inferior Tibia-fibular Ligament.
- *below* ,, Fasciculus of External Lateral ,,
- *intermediately*, the two bands of Posterior Ligament of Ankle.

The **Synovial Membrane** is single, and is prolonged slightly between the apposed surfaces of Tibia and Fibula.

TARSAL LIGAMENTS, Etc.

CALCANEO-ASTRAGALOID LIGAMENTS.
External and **Posterior,**—connecting the contiguous surfaces of Bones.
Interosseous, —very strong, attached to the groove on each Bone between the articular surfaces.

LIGAMENTS between CUBOID, SCAPHOID and CUNEIFORM BONES.
Dorsal, Plantar and **Interosseous** passing between the contiguous surfaces of the Bones.

CALCANEO-CUBOID and CALCANEO-SCAPHOID LIGAMENTS. [Metatarsals.
- Inferior Calcaneo-Cuboid (Long Plantar) passes from Os Calcis (under surface) to Cuboid (ridge) and to bases of 2nd, 3rd and 4th
- ,, ,, ,, (Short Plantar) ,, ,, ,, (depression in front of Ant. Tubercle) to Cuboid (depression behind ridge).
- Superior ,, ,, ,, between the contiguous surfaces of the Bones.
- Internal ,, ,, (Interosseous) ,, from Cuboid (inner side) } to Os Calcis (upper surf. of Greater Process) together forming a Y-shaped Ligament.
- Superior ,, Scaphoid ,, ,, Scaphoid (outer side) }
- Inferior ,, ,, ,, ,, ,, (under surf.) to Os Calcis (Lesser Proc.) and supports Head of Astragalus.

LIGAMENTS OF TARSO-METATARSAL JOINTS.
Dorsal, Plantar and **Interosseous,**—see Diagram for attachments, etc.

Ligaments of Intermetatarsal, Metatarso-Phalangeal and **Interphalangeal Joints.**
These are arranged in the same manner as in the Hand.

In the Foot, the larger Member, there are 6 sometimes 7 **Synovial Membranes**
,, ,, Hand ,, smaller ,, ,, ,, 5 ,, 6 ,, ,,

MUSCLES.

OCCIPITO-FRONTALIS.

Occipitalis, —strong, *arising from* outer ⅔rds of Sup. Curved Line of Occipital Bone, and sometimes Mastoid Process.
Frontalis, —weak ,, ,, Internal Angular Process of Frontal ,, ,, ,, Ext. Ang. ,,

Both parts are *inserted into* the Epicranial Aponeurosis. The Frontalis at its origin is blended with the Muscles above Orbit.

Epicranial Aponeurosis
- connected *behind* with Occipitales, and with Superior Curved Lines between them.
- ,, *in front* ,, Frontales, filling up the angular space between them.
- ,, *laterally* ,, Zygoma, extending over Temporal Fascia.
- ,, *superficially* ,, the Skin, by dense fibro-cellular tissue.
- ,, *deeply* ,, Pericranium ,, loose ,, ,, ,,

MUSCLES OF FACE.

- *Three* Muscles are connected with the Orbit.
- *Six* ,, ,, ,, ,, ,, Nose.
- *Nine* ,, converge towards ,, Mouth, around the orifice of which there is an additional circular muscle.

MUSCLES AROUND ORBIT.

Orbicularis Palpebrarum, consisting of three parts :—

- *Orbital,* composed of coarse, red fibres which form complete ellipses, attached to
  - Internal Angular Process.
  - Tendo Oculi.
  - Margin of Orbit internally.
- *Palpebral* ,, ,, fine, pale ,, ,, ,, half ,, ,, ,, ,,
  - Tendon Oculi ,,
  - Ext. Tarsal Ligament externally.
- *Ciliary* ,, ,, a small bundle of ,, ,, ,, complete ,, unattached to Bone, encircling Margins of Eyelids.

Corrugator Supercilii
- attached to inner end of Superciliary Ridge of Frontal Bone *internally.*
- blended with Orbicularis Palpebrarum opposite middle of Orbital Arch *externally.*

Tensor Tarsi
- attached to Crest and contiguous surface of Lachrymal Bone *internally.*
- blended with Orbicularis Palpebrarum in each lid opposite Punctum Lachrymale *externally.*

MUSCLES OF THE NOSE.

- **Pyramidalis,** —(the only Face Muscle unattached to Bone) blended with Occipito-frontalis *above* and Compressor Naris *below.*
- **Compressor Naris,** —triangular, attached by apex to Canine Fossa *externally,* and by base to opposite Muscle *internally.*
- **Depressor Alæ Nasi,**—quadrilateral ,, ,, Incisive ,, *below,* ,, to Septum and Ala of Nose *above.*

Dilatator Naris Anterior / ,, ,, **Posterior** } attached to Sesamoid Cartilages and Cartilage of Ala *above,* and to Skin of Ala *below.*

Levator Labii Sup. Alæque Nasi (see Muscles of Mouth).

MUSCLES OF MOUTH.

Orbicularis Oris, —consisting of two parts :—

- **Labial,** —composed of fine, pale fibres, forming ellipses round the aperture, unattached to Bone.
- **Facial,** — ,, ,, coarse, red ,, blending with Muscles ,, ,, ,, attached ,, ,, as under.
  - in Upper Lip by *two* slips on each side, one from the Canine Eminence, the other from the Nasal Septum.
  - ,, Lower ,, ,, *one* slip ,, ,, ,, ,, ,, ,, only.

Of the other 9 Muscles
- three pass from *above* to blend with the Orbicularis in the Upper Lip.
- ,, ,, ,, *below* ,, ,, ,, ,, Lower ,,
- ,, ,, *obliquely* ,, ,, ,, at the Angle of the Mouth.

All, with the exception of the Levator Menti, blend more or less at their insertion with the Orbicularis.

Muscles of the Upper Lip.

- **Levator Alæque Nasi,** —arising from Nasal Process of Superior Maxilla, giving off two slips
  - one *outwards* to Levator Labii Superioris.
  - ,, *inwards* ,, Ala of Nose.
- ,, **Labii Superioris,**— ,, ,, lower Margin of Orbit, connected by slips
  - *above* with Orbicularis Palpebrarum.
  - *internally* ,, Levator Alæque Nasi.
  - *externally* ,, Zygomaticus Minor.
  - *below* ,, Orbicularis Oris.
- ,, **Anguli Oris,** — ,, ,, Canine Fossa, continued below into Depressor Anguli Oris partly.

MUSCLES OF FACE.

1.-Corrugator Supercilii.
2.-Orbicularis Palpebrarum
3.-Tensor Tarsi
4.-Pyramidalis Nasi
5.-Compressor Naris
6.-Depressor Alæ Nasi
7.-Dilatator Naris Ant.
8.- " " Post.
9.-Lev. Labii Sup. Alæque Nasi.
10.-Lev. Labii Superioris
11.-Lev. Anguli Oris

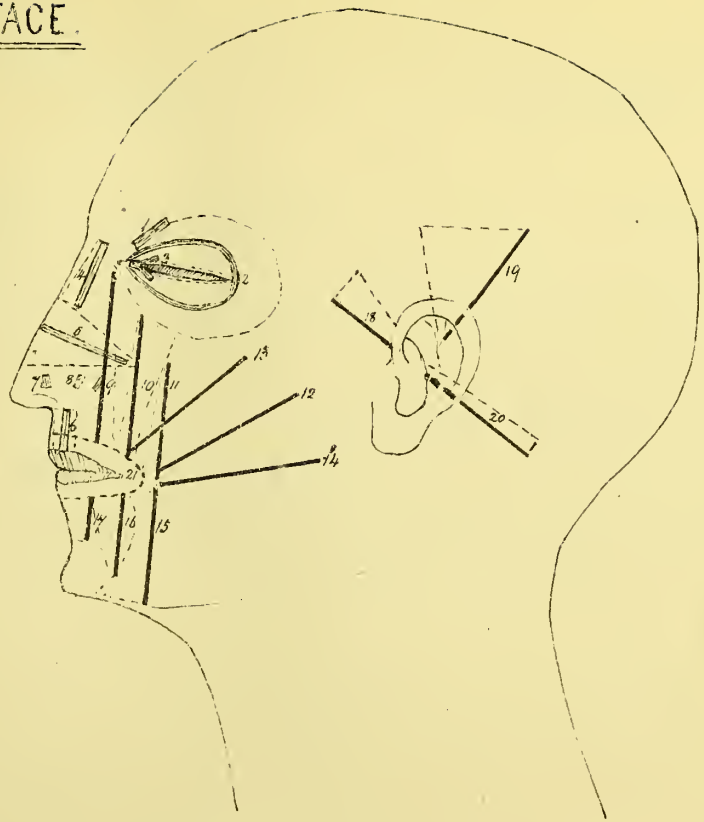

12.-Zygomaticus Major.
13.-Zygomaticus Minor.
14.-Risorius.
15.-Depressor Ang. Oris
16.-Depressor Labii Inf.
17.-Levator Menti
18.-Attrahens (to Fossa of Helix)
19.-Attollens (" " Antihel)
20.-Retrahens (" Concha)
21.-Orbicularis Oris.

Muscles of the Angle of the Mouth.

Zygomaticus Minor,	—*arising* from anterior part of Malar Bone	—*inserted* with	Levator Labii Superioris.
,, **Major,**	— ,, ,, posterior ,, ,, ,,	— ,, ,,	Orbicularis Oris. Depressor Anguli Oris.
Risorius,	— ,, ,, Masseteric Fascia	— ,, ,,	,, ,, ,,

Muscles of the Lower Lip.

Levator Menti,	—conical, *arising* from Incisive Fossa	*inserted into* Integuments of Chin.	
Depressor Labii Inf.,	—quadrilateral ,, ,, Ext. Oblique Line below Mental Foramen,	blending with Orbicularis Oris & Platysma.	
,, **Anguli Oris,**	—triangular ,, ,, ,, ,, ,, ext. to ,, ,,	,, ,, Muscles of Angle of Mouth. overlapping Depressor Labii Inferioris.	

Under the Depressor Anguli Oris are the Labial Branches of the Inferior Dental Vessels and Nerve.
Over ,, Levator ,, ,, ,, Facial ,, ,, Infraorbital ,, ,, ,,

Actions

Orbicularis Palpebrarum
- The *Orbital* Part acts in forcible contraction, rolling up the Skin round the Orbit.
- ,, *Palpebral* ,, ,, ,, ordinary winking, closing and drawing in the Eyelids.
- ,, *Ciliary* ,, ,, by slightly elevating the Eyelashes.

Tensor Tarsi draws the Puncta Lachrymalia inwards and backwards, and compresses the Lachrymal Sac.

Orbicularis Oris
- The *Facial* Part protrudes the edges of the Lips.
- ,, *Labial* ,, turns in ,, ,, ,, ,, and diminishes the aperture between them.

The Actions of the *other Muscles* may be understood from their names or positions.

Superior Rectus,	—narrowest,	*arising* from	*upper*	part of Optic Foramen and Sheath of Optic N. by common tendon.
Internal ,,	—broadest,	,, ,,	*inner*	,, ,, ,, ,, ,, ,, ,, ,, ,, ,,
Inferior ,,	—	,, ,,	*lower*	,, ,, ,, ,, ,, ,, ,, ,, ,, ,,
External ,,	by Upper Head	,, ,,	*upper and outer*	,, ,, ,, ,, ,, ,, ,, ,, ,, ,,
	,, Lower ,,		*lower* ,, ,, ,, ,, ,, ,, ,, ,, ,, ,, ,,	
			spine on outer margin of Sphenoidal Fissure.	
			fibrous band between points of origin from bone.	

The Recti are *inserted* into the Sclerotic at equidistant points, ¼ in. from the Cornea.

Superior Oblique,—*arising* from Roof of Orbit above and internal to Common Tendon, *inserted* into upper, back and outer part of Sclerotic.
Inferior ,, — ,, ,, Floor ,, ,, at inner side, ant. to Lachrymal Groove ,, close to Superior Oblique.

The Oblique Muscles cross *below* the corresponding Recti.
,, Superior Oblique passes between the Superior Rectus and the Eyeball.
,, Inferior ,, ,, ,, ,, Inferior ,, ,, ,, Floor of the Orbit.
(,, ,, ,, ,, also ,, ,, External ,, ,, ,, Eyeball).

Levator Palpebræ Superioris,—*arising* from Roof of Orbit in front of Optic Foramen, *inserted* into anterior surface of Tarsal Cartilage

Actions
- The External and Internal Recti turn the Eyeball in corresponding directions.
- ,, Superior ,, Inferior ,, ,, ,, ,, ,, ,, ,, and also inwards.
- ,, ,, Oblique turns ,, ,, down and out, acting with Inferior Rectus.
- ,, Inferior ,, ,, ,, ,, up ,, ,, ,, ,, Superior ,,

EYELIDS.

In the Upper Lid there are *seven* layers from before back as follows :—

1. *Skin.*
2. Orbicularis Palpebrarum (Palpebral portion) *Muscle.*
3. Tarsal *Ligament.*
4. Levator Palpebræ Superioris *Tendon.*
5. Tarsal *Cartilage.*
6. Layer of Meibomian *Glands.*
7. Conjunctiva (*Mucous Membrane*).

Each of these layers is different in nature from the others. The Tendon forming the Central Layer is absent in the Lower Lid, otherwise the layers in that Lid are the same as in the Upper Lid.

ORIGINS OF RECTI FROM WALL OF ORBIT.

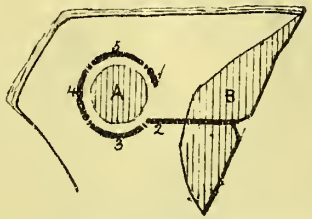

A.- *Optic Foramen.* B. *Sphenoidal Fissure.*

1.- *Ext. Rectus* - (*Upper Head*).
2.- " " - (*Lower* ").
3.- *Inf.* "
4.- *Int.* "
5.- *Sup.* "

RELATION OF MUSCLES TO AXES OF ORBIT AND EYEBALL.

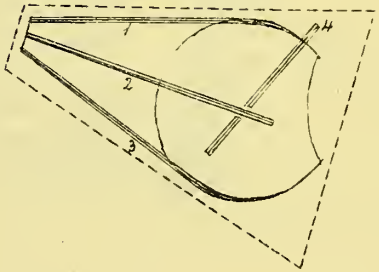

1.- *Internal Rectus.*
2.- *Superior* " .
3.- *External* " .
4.- *Superior Oblique.*

LAYERS IN UPPER EYELID.

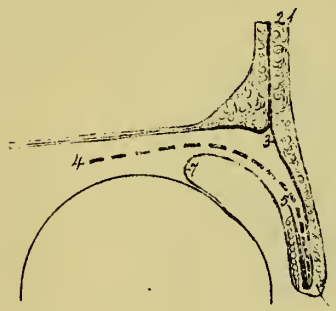

1.-Skin
2.-Orbicularis Palp.
3.-Palpebral Lig^{t}.
4.-Lev. Palp. Sup. Tendon.
5.-Tarsal Cartilage.
6.-Meibomian Glands.
7.-Conjunctiva.

RELATION OF OBLIQUI TO RECTI.

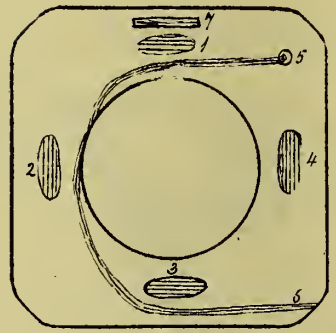

1.-Rectus Superior.
2.- " Externus.
3.- " Inferior.
4.- " Internus.
5.- Obliquus Superior
6.- " Inferior.
7.-Lev. Palp. Sup.

The **Relations** of the chief structures in and near the Region are as follows :—

Internal to Ramus of Inferior Maxilla.

- Internal Maxillary *Artery* and Branches.
- External Pterygoid Muscle
- Inferior Maxillary *Nerve* and Branches.
- Internal Pterygoid Muscle
- *Arteries* of Pharynx (see Arteries.)
- Pharynx (Superior Constrictor Muscle chiefly).

Posterior to Ramus of Inferior Maxilla.

- Parotid Gland
  - containing
    - *External* Carotid Artery.
    - ,, Jugular Vein.
    - Facia Nerve.
- Styloid Process
  - overlying
    - *Internal* Carotid Artery.
    - ,, Jugular Vein.
    - Deep Nerves of Neck.
- Pharynx (Superior Constrictor chiefly).

The most *superficial* of the Muscles, viz., the Masseter, is inserted into the outer surface of the Ramus,
and the *deepest* ,, ,, ,, ,, ,, Internal Pterygoid ,, ,, ,, ,, inner ,, ,, ,, ,,
They are both four-sided, and parallel in direction, and they act by *elevating* the Jaw.

Of the two *intermediate* Muscles :—
The Temporal triangular, is inserted into the Coronoid Proc. chiefly, and acts by *elevating* the Jaw, and *retracting* it.
,, External Pterygoid ,, ,, ,, ,, ,, Condyloid ,, ,, ,, ,, *projecting* ,, ,,

The Temporal aids in elevating the Jaw, and is itself assisted by the deeper fibres of the Masseter in retracting it.
,, External Pterygoid is aided in projecting the Jaw by the Internal Pterygoid and by the superficial fibres of the Masseter.

The *fifth* Muscle, the Buccinator, anterior to the others, forms the lateral wall of the Mouth, and aids in mastication by helping to keep the food between the teeth.

Origins of the Muscles.

Temporal, from the { Temporal Fossa (except the posterior surface of the Malar Bone).
,, Fascia.

Masseter ,, ,, { Malar Process of Superior Maxilla, and anterior $\frac{2}{3}$ of lower edge of Zygomatic Arch by superficial part.
Inner surface of Zygomatic Arch ,, posterior $\frac{1}{3}$,, ,, ,, ,, ,, ,, ,, deep ,,

Ext. Pterygoid ,, ,, { Great Wing of Sphenoid (under surface)
External Pterygoid Plate (outer ,,) } by two Heads, between which passes the Int. Maxillary Art.

Int. Pterygoid, from the { External Pterygoid Plate (inner surface).
Tuberosities of Palate Bone and Superior Maxilla.

Buccinator ,, ,, { outer edge of the Alveolar Process of both Jaws opposite the Molar Teeth.
Pterygo-maxillary Ligament.

Insertions of the Muscles.

Temporal,	—into the Coronoid Process,	and Anterior Border of the Ramus of the Jaw.
External Pterygoid,	— ,, ,, Condyloid ,, (neck)	,, Interarticular Fibro-cartilage ,, ,, Joint.
Masseter,	— ,, ,, outer surface of the Ramus.	
Internal Pterygoid,	— ,, ,, inner ,, ,, ,, ,,	(below Dental Foramen).
Buccinator,	— ,, ,, Muscles at Angle of Mouth, some of its fibres from above decussating with some from below.	

There are *five* muscular attachments to the Lower Jaw, of which the limit is marked by the Last Molar Tooth.

On *Outer* Surface { Masseter,
Buccinator,

On *Inner* Surface { Superior Constrictor.
Mylo-hyoid.

Intermediately,—Temporal (on anterior margin of Ramus).

Relation of External Pterygoid to Nerves

Appearing *above*	its upper border	{ Deep Temporal Nerves. Masseteric Nerve
,, *below*	,, lower ,,	{ Inferior Dental ,, Gustatory ,,
,, *in front*,	between Heads of Origin,	Buccal Nerve (which usually supplies it).
,, *behind*,	posterior to tendon of Insertion,	Auriculo-Temporal Nerve.

MUSCLES OF PTERYGO-MAXILLARY SPACE.

LINES OF ACTION.

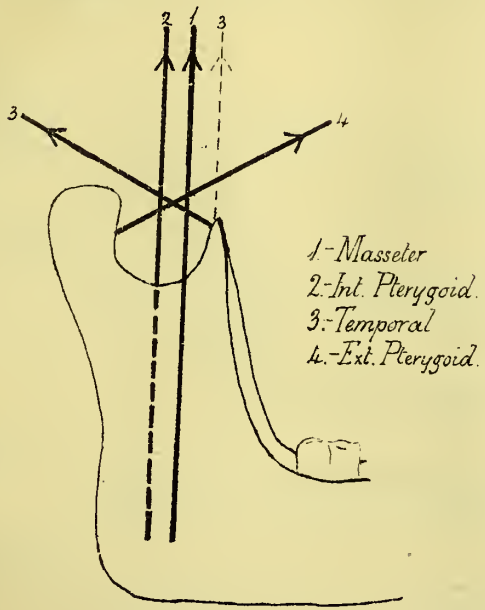

EXTERNAL PTERYGOID MUSCLE.

RELATION TO NERVES.

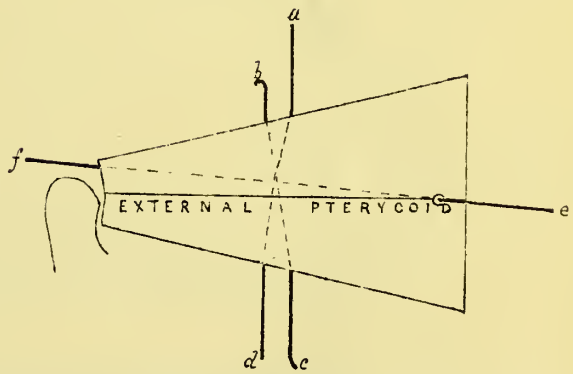

a.-Deep Temporal N. (Post). d.- Inf. Dental N
b.-Masseteric " e.- Buccal "
c.-Gustatory " f.- Auriculo-temporal N.

LONGUS COLLI.

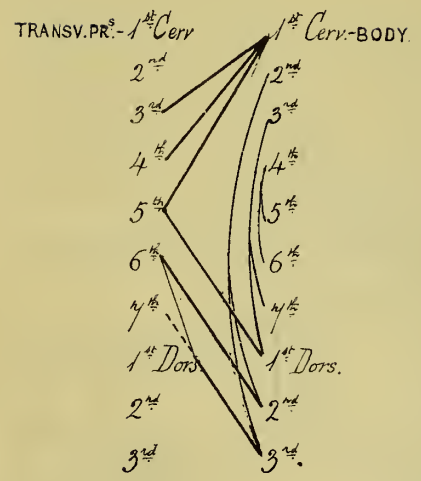

MUSCLES OF POST. TRIANGLE.



The Flexors of the Neck are the Three Scalenes, the Three Recti, and the Longus Colli.

Longus Colli, attached by	*upper oblique* portion	to Tubercle on Anterior Arch of Atlas. ,, Transverse Processes of Middle three Cervical Vertebræ (3rd, 4th and 5th).	
	lower ,, ,,	,, ,, ,, ,, lower ,, ,, ,, (except 7th). ,, Bodies of upper three Dorsal Vertebræ.	
	median vertical ,,	,, ,, ,, ,, ,, ,, and lower three Cervical Vertebræ. ,, ,, ,, three Cervical Vertebræ next below the 1st (2nd, 3rd and 4th).	

Recti—Origins.

R. Anticus Major,—from middle three Cervical Vertebræ (3rd, 4th, 5th) and also the 6th—(anterior Transverse Processes).
R. ,, Minor,— ,, Atlas—(anterior margin of Lateral Mass and root of Transverse Process).
R. Lateralis, — ,, ,, —(upper surface of Transverse Process).

Recti—Insertions.

In the order of insertion before back on the Occipital Bone in the case of the Recti Antici and Postici the Major Muscle comes first, the Rectus Lateralis being intermediate between the two sets. Thus :—

The Rectus Anticus Major is inserted close by the mid-line on the Basilar Process,
,, ,, ,, Minor ,, ,, behind and external to it,
,, ,, Lateralis ,, ,, on the under surface of the Jugular Process,
,, ,, Posticus Major ,, ,, ,, ,, outer part of the Inferior Curved Line,
,, ,, ,, Minor ,, ,, close by the mid-line behind (the Occipital Crest).

See Diagram of the Occipital Bone.

Scaleni—Origins.

S. Anticus, —from First Rib near *anterior* end (from Tubercle on Inner Border, between Subclavian Groove).
S. Medius, — ,, ,, ,, ,, *posterior* ,, (along a line from the Tubercle to Groove for Subclavian Artery).
S. Posticus, — ,, Second ,, ,, ,, ,, (between attachments of Serratus Magnus and Serratus Post. Sup.).

Scaleni—Insertions.

S. Anticus, — to middle *three* Cervical Vertebræ and also to the 6th —(Anterior Tubercles of Transverse Processes).
S. Medius, — ,, lower *six* ,, ,, (exc. last sometimes)—(Posterior ,, ,, ,, ,,).
S. Posticus, — , ,, *three* ,, ,, —(,, ,, ,, ,, ,,).

The Longus Colli and Recti Antici enter into the floor of the Anterior Triangle.
,, Scalene Muscles ,, ,, ,, ,, ,, ,, Posterior ,,

Relations of Rectus Lateralis
- *in front* the Internal Jugular Vein.
- *behind* ,, Vertebral Artery.
- *to outer side* ,, Occipital ,,
- ,, *inner* ,, ,, Anterior Division of 1st Cervical Nerve.

The four muscles entering into the floor of the Posterior Triangle, viz.: Splenius, Levator Anguli Scapulæ, Scalenus Medius and Scalenus Anticus, overlap each other near the Vertebræ, but diverge as they pass outwards, so as to clear one another below.

The uppermost,	the Splenius,	is fixed by	its *highest* point of attachment to the	*Skull.*	
,, next	,, Levator Anguli Scapulæ	,, ,, ,, ,, ,,	,, ,, ,, ,, ,,	1st	Cervical Vertebræ.
,, ,,	,, Scalenus Medius	,, ,, ,, ,, ,,	,, ,, ,, ,, ,,	2nd	,, ,,
,, lowest	,, ,, Anticus	,, ,, ,, ,, ,,	,, ,, ,, ,, ,,	3rd	,, ,,

The first two	Splenius Levator Anguli Scapulæ	are ,, ,, their *lowest*	,, ,, ,, ,, ,,	3rd	,, ,,
,, other ,,	Scalenus Medius ,, Anticus	,, ,, , ,, ,,	,, ,, ,, ,, ,,	6th	,, ,,

STERNO-CLEIDO-MASTOID.

Origin
- by *inner Head*, round and tendinous, from upper and outer part of anterior surface of Manubrium.
- „ *outer* „ flat „ muscular „ inner half or third „ „ „ „ Clavicle.

Insertion
- „ aponeurosis, on outer „ „ „ „ Superior Curved Line of Occipital Bone.
- „ tendon „ „ Surface of Mastoid Process.

Relations
- by *superficial* surface, with Integuments, External Jugular Vein, and Superficial Branches of Cervical Plexus.
- „ deep „ „
  - Muscles
    - *below*, —Sterno-hyoid, Sterno-thyroid and Omo-hyoid.
    - *above*, —Splenius, Digastric „ Trachelo-mastoid.
    - *intermediately*, —Lev. Ang. Scap., Scalenus Ant. „ Scalenus Medius.
  - Arteries
    - *above*, —Occipital, with its Sterno-mastoid Branch.
    - *below*, —Suprascapular and Transverse Cervical.
    - *intermediately*, —Asc. Cerv. from Inf. Thyroid „ Sterno-mastoid from Sup. Thyroid.
  - Veins
    - *above*, —Occipital.
    - *below*, —Anterior Jugular.
    - *intermediately*, —Ascending Cervical.
  - along *inner* edge, —Sheath of Carotid Vessels.
  - across *lower* part, —Subclavian Vessels (the Artery being crossed by Scalenus Ant.).
  - Nerves
    - *above*, —deep part of Cervical Plex.; *below*,—upper part of Brachial Plex.
    - *intermediately*, —Descendens Noni and Communicans Noni.
    - *piercing* the Muscle,—Spinal Accessory „ Branch of 2nd Cervical.
  - Glands, etc.
    - *above*, —Process of Parotid Gland.
    - *below*, —Thoracic Duct on left side, and Right Lymphatic Duct on right.
    - *intermediately*, —Glandulæ Concatenatæ.

These are divisible into *three* Groups, each consisting of *three* Muscles.

THREE VERTICAL DEPRESSORS.

Sterno-hyoid	*origin*	—Posterior Surfaces of Manubrium, Cartilage of 1st Rib and Clavicle (inner end).
	insertion	—Hyoid Bone—*lower edge of Body.*
Thyro-Hyoid with **Sterno-thyroid**	*origin*	—Thyroid Cartilage (Oblique Line), some fibres being continued from Sterno-thyroid.
	insertion	—Hyoid Bone—*lower edge of Great Cornu.*
	origin	—Posterior Surfaces of Manubrium and Cartilage of 1st Rib, below and behind Sterno-hyoid.
	insertion	—Thyroid Cartilage (Oblique Line), some fibres being continued into Thyro-hyoid.
Omo-hyoid	*origin*	—Transverse Ligament of Scapula and contiguous part of Superior Border of Scapula.
	insertion	—Hyoid Bone—*lower edge of Body at junction with Great Cornu.*

THREE VERTICAL ELEVATORS.

Mylo-hyoid,	—arising from	Int. Oblique Line of Inf. Maxilla	forming raphé in mid-line with opposite muscle. inserted into Hyoid Bone (into Body below Genio-hyoid).
Genio-hyoid,	— ,, ,,	Genio-hyoid Tubercle,, ,, ,,	,, ,, ,, (,, Centre of Body).
Genio-hyo-glossus,	— ,, ,,	Genio-hyo-glossus ,, ,, ,,	,, ,, ,, (,, upper edge of Body). ,, ,, Tongue (under surface close to mid-line).

THREE OBLIQUE ELEVATORS.

Stylo-hyoid,	—arising from	Styloid Process (outer side of base)		split near insertion by tendon of Digastric. inserted into Hyoid Bone (at junction of Body & Great Cornu).
Digastric,	— ,, ,,	Temporal Bone (Digastric Groove) Inferior Maxilla (,, Fossa)		connected with ,, ,, by Supra-hyoid Aponeurosis.
Hyo-glossus,	— ,, ,,	Side of Tongue between	Stylo-glossus & Lingualis	inserted into ,, ,, chiefly into Great Cornu. by special slips into Small Cornu. Body of Hyoid Bone.

As regards the attachment of the Muscles to the Hyoid Bone :—

The *Vertical* Elevators are all fixed one above another to the Body of the Bone,

The *Depressors* are attached side by side—one to the Body, one near the junction of the Body and Great Cornu, and one to the Great Cornu,

The *Oblique* Muscles are attached, two near the junction of the Body and Great Cornu, and one to the Great Cornu.

See Diagram of the Hyoid Bone.

HYOID MUSCLES.

LINES OF ACTION ETC.

1.- Sterno-hyoid.
2.- Omo-hyoid.
3.- Thyro-hyoid.
4.- Mylo-hyoid.
5.- Genio-hyoid.
6.- Genio-hyo-glossus
7.- Digastric
8.- Stylo-hyoid.
9.- Hyo-glossus.

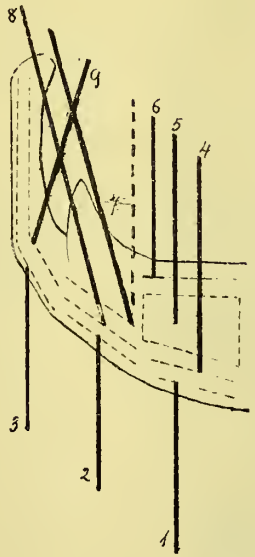

SUBMAXILLARY REGION.

VERTICAL SECTION.*

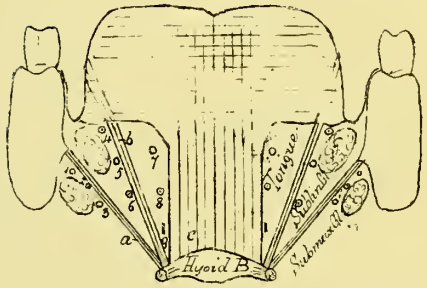

1.-Mylo hyoid Art.
2.-Mylo-hyoid Nº
3.-Submental Art.
4.-Gustatory Nerve.
5.- Wharton's Duct.
6.-Hypoglossal N.
7.-Lingual Art
8.-Glosso-pharyngeal N.
9.-Stylo-hyoid Ligt.

a.-Mylo-hyoid Muscle.
b.- Hyo-glossus "
c.-Genio hyo-glossus "

Diagram to show merely relative situations of parts.

CONSTRICTORS OF PHARYNX.

A.- Sup. Constrictor.
B.- Mid. Constrictor.
C.- Inf. Constrictor.
1. - Levator Palati
2.- Tensor Palati.
3. - Stylo-pharyngeus.
4. - Glosso-pharyngeal N.
e.- Crico-thyroid M

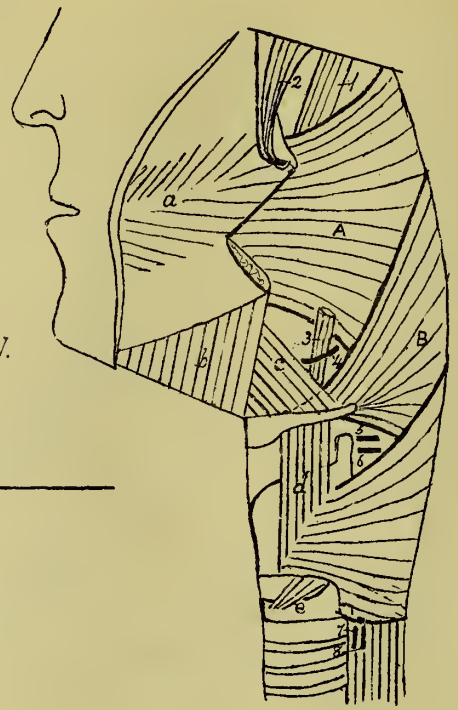

5-Sup. Laryngeal N.
6.- " " Art.
7.- Inf. " N.
8.- " " Art.
a.- Buccinator M
b.- Mylo-hyoid "
c.- Hyo-glossus "
d.- Thyro-hyoid "

SUBMAXILLARY REGION.

Relations of Parts.

On Inner Side of Space,
from before backwards.

- Digastric Muscle (anterior belly)
- Mylo-hyoid ,, (inner part)
- Genio-hyoid ,, (whole length)
- Genio-hyo-glossus ,, (inferior border)

In Outer Part of Space,
from before backwards.

- Submaxillary Gland (below Jaw).
  - Mylo-hyoid Muscle.
- Sublingual Gland (below Mucous Membrane).
  - Hyo-glossus Muscle.
- Tongue.

Crossing over the Mylo-hyoid Muscle are *Two* Arteries* and *One* Nerve
- Mylo-hyoid Artery, from Inferior Dental.
- ,, ,, Nerve ,, ,, ,,
- Submental Artery ,, Facial.

,, under the Mylo-hyoid / over ,, Hyo-glossus ,, *Two* Nerves and *One* Duct
- Gustatory Nerve, above (with Submaxillary Ganglion).
- Hypo-glossal ,, below, giving branches.
- Wharton's Duct (with deep part of Submaxillary Gland).

,, ,, ,, Hyo-glossus ,, *One* Artery, *One* Nerve and *One* Ligament
- Lingual Artery.
- Glosso-pharyngeal Nerve.
- Stylo-hyoid Ligament.

* The Facial Artery rests on the Submaxillary Gland.

Superior Constrictor, *origin* linear, from 6 points		Internal Pterygoid Plate—lower ⅓ of Posterior Border (bone), Tendon of Tensor Palati Pterygo-maxillary Ligament } (soft structures). Alveolar Process of Lower Jaw, opposite last Molar Tooth internally (bone) Mucous Membrane of Mouth Side of Tongue } (soft structures).
Middle Constrictor	,, pointed ,, 3 ,,	Hyoid Bone (upper border of Great Cornu). ,, ,, (posterior ,, ,, Small ,,). Stylo-hyoid Ligament (lower end).
Inferior Constrictor	,, linear ,, 3 ,,	Thyroid Cartilage (surface behind Oblique Line). ,, ,, (Inferior Cornu). Cricoid ,, (lateral surface).

Each Muscle unites with its fellow in a raphé at the mid-line behind.

The lower fibres of the Inferior Constrictor are *directed* transversely, and united with the fibres of the Œsophagus.

,, ,, ,, ,, Superior and Middle ,, ,, ,, obliquely down, and are overlapped by the Muscle below.

,, upper ,, ,, Superior ,, ,, ,, ,, up ,, ,, united* to Petrous Bone. Pharyngeal Spine or Basilar Pr.

* By Aponeurosis of Pharynx, which, becoming thinner below, invests the inner surfaces of the Muscles.

Crossing upper border of Superior Constrictor are	Levator Palati Muscle, entering Pharynx, over upper border of Constrictor. Tensor ,, ,, ,, ,, round ant. ,, ,, ,,
Entering between origins of Sup. and Middle Constrictors are	Stylo pharyngeus Muscle. Glosso-pharyngeal Nerve.
,, ,, ,, Middle and Inf. ,, ,,	Superior Laryngeal Artery from Superior Thyroid. ,, ,, Nerve ,, Vagus.
,, under the lower border of Inferior Constrictor ,,	Inferior ,, Artery ,, Inferior Thyroid. ,, ,, Nerve ,, Vagus (Recurrent).

There are thus two Palatine structures entering above Superior Constrictor, two Pharyngeal between Superior and Middle Constrictors, two Superior Laryngeal between Middle and Inferior Constrictors, and two Inferior Laryngeal below Inferior Constrictor.

Palato-pharyngeus —see Muscles of Palate.

Salpingo-pharyngeus { arising *above* from Cartilage of Eustachian Tube.
blending *below* with Palato-pharyngeus.

Stylo-pharyngeus { arising *above* from inner surface of Base of Styloid Process of Temporal Bone.
inserted *below* with posterior border of Thyroid Cartilage, blending with Palato-pharyngeus.

All three Muscles are more or less united below, as indicated.

Of the **Muscles** connected with the **Styloid Process** :—

The Stylo-hyoid arises from the outer side of the Base, and crosses over the External Carotid Artery.

The Stylo-pharyngeus „ „ „ inner „ „ „ „ „ { under „ „ „ „
over „ Internal „ „

The Stylo-glossus „ „ „ Apex, and from the Stylo-maxillary Ligament, and is not in relation with either vessel.

Of the **Ligaments** connected with the **Styloid Process** :—

The Stylo-maxillary gives origin to the Stylo-glossus Muscle by its upper end.
The Stylo-hyoid „ „ „ Middle Constrictor „ „ lower „

MUSCLES OF THE SOFT PALATE.

Of the *five* muscles of the Soft Palate :—
two, the Levator and Tensor Palati, *descend* from above;
two, the Palato-glossus and Palato-pharyngeus, *ascend* from below;
and *one*, the Azygos, lies *horizontally* in the Palate itself.

Attachments of the muscles externally to the Soft Palate :—

Levator Palati, —to Apex of Petrous Part of Temporal Bone, and to inner and back part of Eustachian Tube.
Tensor „ —„ Scaphoid Fossa and Spine of Sphenoid „ „ outer „ fore „ „ „
Azygos, —„ Posterior Nasal Spine and contiguous Aponeurosis.
Palato-glossus, —„ Tongue (lateral surface and dorsum) in union with Stylo-glossus.
Palato-pharyngeus, —„ Thyroid Cartilage (posterior border) and contiguous portion of Pharynx.

Connection of the Muscles with the Soft Palate :—

Palato-pharyngeus enters the Palate in two fasciculi { one lying next the mucous membrane on *upper* surface of Palate.
the other „ *intermediately* between the Levator and Tensor Palati.
Palato-glossus „ „ „ „ one fasciculus „ next the mucous membrane on *under* surface of Palate.

Azygos, —lying next to mid-line of Palate, is connected laterally with the Levator Palati.

Levator Palati,	—entering Pharynx above	Sup. Constrictor,	lies in the Palate between the fasciculi of	Palato-pharyngeus.	
Tensor Palati	— „ „	in front of „ „	is inserted into	Aponeurosis of Soft Palate. posterior border of Hard „	

Each Muscle blends at the mid-line with its fellow of the opposite side.

There are thus *seven* layers in the Soft Palate, viz., from above down :—

1. Mucous Membrane, continuous with that of Nose, covered by columnar ciliated epithelium,
2. Posterior or upper fasciculus of Palato-pharyngeus,
3. Levator Palati and Azygos,
4. Anterior or lower fasciculus of Palato-pharyngeus,
5. Tensor Palati and Aponeurosis,
6. Palato-glossus,
7. Mucous Membrane, continuous with that of Mouth, covered by squamous stratified epithelium.

EXTRINSIC MUSCLES OF THE TONGUE.

Three are connected with the side of the Tongue and *one* with the under surface.

Of the three lateral Muscles	the Palato-glossus passes	*down*	from above,
	the Hyo-glossus „	*up*	„ below,
	the Stylo-glossus „	*forwards*	„ behind.

On reaching the Tongue these three muscles blend to form a muscular expansion which covers the *anterior two-thirds* of the organ beneath the Superficial Lingualis.

The part of the Hyo-glossus known as the Chondro-glossus continues the expansion backwards over the *posterior third* of the organ.

Some fibres of both the Stylo-glossi decussate beneath *the Tip* of the Tongue in front of the Hyo-glossi.

The Muscle on the under surface,—the Genio-hyo-glossus,—enters the Tongue in separate fasciculi, which pass through vertically by the side of the *Septum,* to end in the submucous tissue of the Dorsum. The most posterior fibres are connected with the Hyo-glossal Ligament and the Hyoid Bone.

The other attachments of the Muscles have been noted previously.

SOFT PALATE AND TONGUE.

RELATIVE POSITIONS OF MUSCLES. ETC.

SOFT PALATE - POST^LY.

1.-Levator Palati
2-Tensor Palati
3.-Azygos Uvulæ.
4.-Palato-glossus
5.-Palato-pharyngeus
a.-Eustachian Tube
b.-Tonsil.

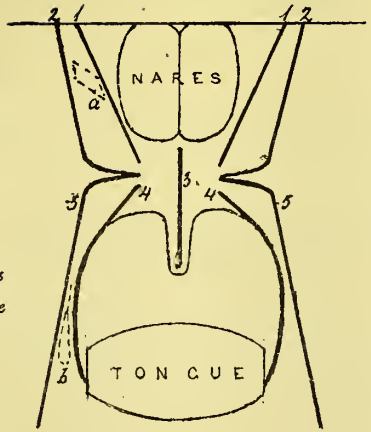

TONGUE.- LATERALLY

1.-Palato-glossus
2.-Stylo-glossus
3.-Hyo-glossus
4.-Genio-hyo-glossus.

To indicate lines of action

1.-Mucous Membrane.
7.- " "
2.-Palato-phar.-(Upper Fasc.)
4.- " " -(main part).

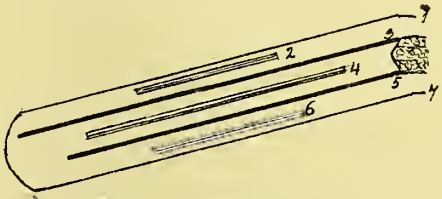

SOFT PALATE.- VERT. LONG. SECT.

3.-Ler. Palati and Azygos.
5.- Tens. " " Aponeurosis.
6.- Palato-glossus.

The Muscles of the Back form *four Groups*—three consisting each of three pairs of muscles or sets of muscles, and one of three double muscles.

In addition there are the four single muscles of the Suboccipital Triangle, viz. { the two Recti Antici. the two Obliqui.

The muscles of each Group are more or less related to each other in position and function.
" " " pair " " " " " " " and attachments.

The **FIRST GROUP**—Muscles of Upper Extremity and Thorax—consists of *three pairs* of muscles, which pass more or less *transversely outwards*.

The muscles of the first pair connect one the Head and Spine the other the Pelvis and Spine with the *Upper Extremity*.
" " " second " " the Spine with the *Scapula* (posterior border).
" " " third " " " " " *Ribs* external to the Angles.

Trapezius, *Origin* { inner ½ or ⅓ of Superior *Curved Line* of Occipital Bone; By Lig. Nuchæ (*Aponeurosis*) from Cervical Spines,—*Insertion* { the outer ⅓ of the ant. surf. of the Clavicle. " inner edge of Acromion Process. " upper border & Tubercle of Spine of Scapula.; Spines of all the Dorsal *Vertebræ* (with the 7th Cervical)

Latissimus Dorsi " { posterior ½ or ⅓ of *Crest* of Ilium. By *Aponeurosis* of Erector Spinæ. from Lumbar and Sacral Spines,—*Insertion*—the floor of the Bicipital Groove. Spines of the six lower Dorsal *Vertebræ*—and by special slips from Lower two or three Ribs, and Inferior Angle of Scapula.

Both muscles are flat and triangular, having their fibres converging towards the Shoulder, and they cover between them all the deeper parts of the Back, except a small portion of the Rhomboideus Major Muscle. Compare Origins and see 'Muscles of Shoulder.'

Lev. Anguli Scapulæ, —*Origin*—first three Cerv. Post. Transv. Proc. —*Insertion*—Post. Border of Scapula above Spine.
Rhomboideus Major with **Rhomboideus Minor** " —7th Cerv. and upper five Dorsal Spines — " — " " " { below and opp. to } " Spine.

The Lev. Anguli Scapulæ is attached to about the upper *three* Cervical Vertebræ.
" Rhomboidei together are " " " " " *six* Dorsal "

Serratus Posticus Sup.,—*Origin*— { Ligamentum Nuchæ; Last Cerv. and upper 3 Dorsal Spines } —*Insertion*—Upper 4 Ribs ext. to Angles (exc. 1st).

Serratus Posticus Inf. " { " (or last 2) Dorsal " " " Lumbar " ; Interspinous Ligaments } " —Lower " " " "

The **SECOND GROUP** (Extensors of the Back) consists of *three pairs* of Muscles, which pass *vertically upwards*, the whole series forming a somewhat cylindrical column occupying the groove between the Spines and Laminæ.

The Muscles of the *first* pair connect the Pelvis with the Dorsal Vertebræ and Ribs.
" " " *second* " " " Dorsal Vertebræ and Ribs with the Cervical Vertebræ.
" " " *third* " " " Cervical " with the Head.

The two Muscles of each pair lie side by side, one externally, the other internally, and the pairs succeed each other in a zigzag fashion (see Diagram).

The lowest pair spring opposite the last Rib from the Erector Spinæ by subdivision of its fibres.

Erector Spinæ, —*Origin*
- *externally* —Post $\frac{1}{5}$ of Iliac Crest—exc. opp. Posterior Superior Spine.
- *internally* —Spines of Lumbar and Sacral Vertebræ by Aponeurosis.
- *by deep surf.* { Posterior Surface of Sacrum (upper part). " " Lumbar Transverse Processes.
- " *superf.* " —Aponeurosis strengthened by posterior reflection of Fascia Lumbar.

} It is thus attached on all its sides.

Longissimus Dorsi —arising from Erector Spinæ, is inserted into { *all* the Dorsal Transverse Processes (apices). " " Ribs close to the Tubercles (*except first two*).
Ilio-costalis — " " " " " " " the lower six Ribs (at their angles).

The slips of insertion of the Ilio-costalis
with " " " origin and insertion " Accessorius
and " " " origin " Cervicalis Ascendens
} are connected { by slips of insertion with *all* the Ribs at the Angles.
" " origin " " " int. to " (*except first two*).

Thus the attachments of the Longissimus Dorsi are symmetrical with those of the Ilio-costalis combined with the Accessorius and the origin of the Cervicalis Ascendens.

The Accessorius is described as arising from the lower six Ribs internal to the Angles,
and inserted into " upper " " at the Angles.

The Longissimus Dorsi and Ilio-costalis muscles lie parallel to each other.

Cervicalis Ascendens —arising from the *Ribs* from the 3rd to 6th int. to the Angles, is inserted from the 4th to the 6th Cerv. Transv. Proc.
Transversalis Colli — " " " upper six Dorsal *Transverse* Processes " " " 2nd " 6th " " "

These muscles converge above.

Trachelo-mastoid —arising from { upper six Dorsal *Transverse* Processes, is inserted into the Mastoid Process posteriorly.
lower three Cervical *Articular* "

Complexus — " " { upper six Dorsal *Transverse* Processes.
from 3rd to 7th Cervical *Articular* " " " " Occipital Bone, between curved lines [internally.
lower three (often 1 or 2) Cervical *Spines*.

These muscles diverge above.

LONGISSIMUS DORSI, ETC.

1.- Erector Spinæ.
2.- Ilio-costalis.
3.- Accessorius
4.- Cervicalis Asc.
5.- Longiss. Dorsi.
6.- Transversalis.
7.- Trachelo-mastoid.

The dotted lines indicate the true direction of the muscles







MUSCULAR ATTACHMENTS AT BACK OF NECK.

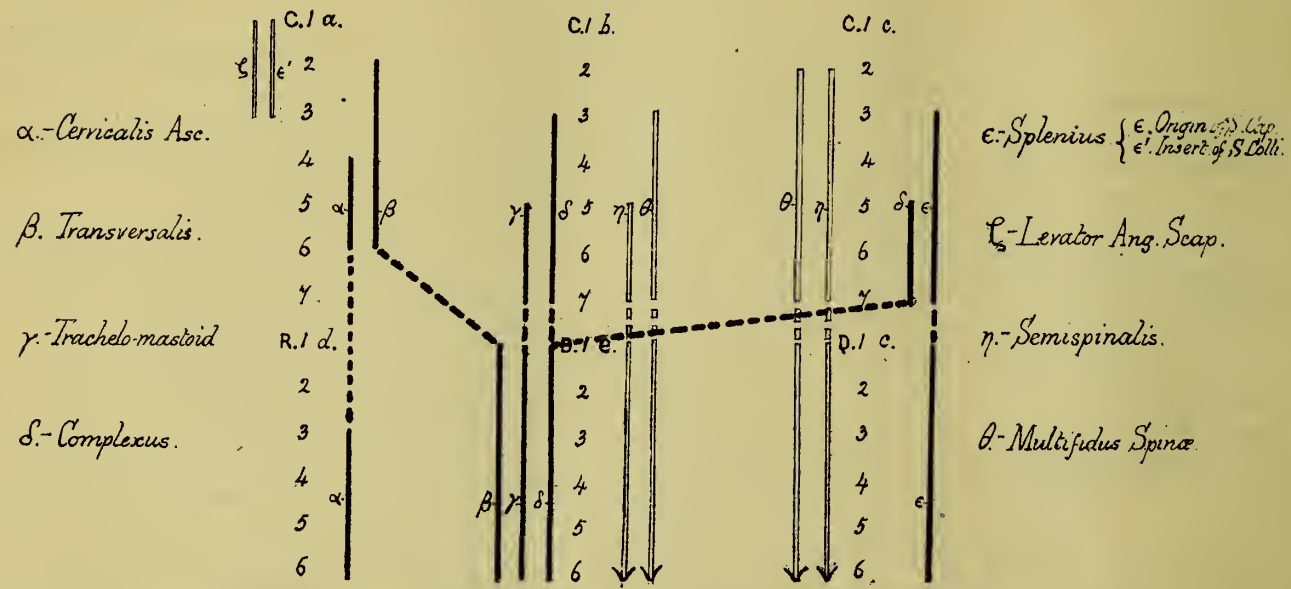

C.1 a. downwards to γ.-Cerv. Transv. Proc^ss. R.1. d. downwards to 6.-Angles of Ribs.
C.1.b. " " - " Artic. " D.1.e. " " Dors. Transv. Proc^ss
C.1.c. " " - " Spinous " D.1.c. " " " Spinous " .

The **THIRD GROUP** (Rotators) consists of *three double* Muscles.

Splenius Capitis **Splenius Colli**	*Origin*	upper six Dorsal Spines Lig. Nuchæ as high as 3rd Cervical Spine	*Insertion*	S. Cap. S. Colli, upper three Cerv. Post. Trans. Proc.	Mastoid process. Sup. curved line of Occipital Bone.
Spinalis Colli	— ,,	—last two Cervical and first two Dorsal Spines	,,	Spine of Axis.	
Spinalis Dorsi	— ,,	— ,, ,, Dorsal ,, ,, ,, Lumbar ,,	,,	upper eight Dorsal Spines.	
Semispinalis Colli	— ,,	lower three Cervical Articular Processes upper six Dorsal Transverse ,,	,,	from second to fifth Cervical Spines.	
Semispinalis Dorsi	— ,,	—from sixth to tenth Dorsal Transverse Processes	,,	upper four Dorsal and lower two Cervical Spines.	

The Semispinalis Dorsi is connected with four Transverse Processes and six Spines, the Semispinalis Colli with six Transverse Processes and four Spines.

Of these three Muscles,—the Splenius passes *over* the column of Extensors from Transverse Processes to Spines.
,, Spinalis ,, *parallel to* ,, ,, ,, ,, ,, Spines to Spines.
,, Semispinalis ,, *beneath* ,, ,, ,, ,, ,, ,, ,, Transverse Processes.

The **FOURTH GROUP** (Intervertebral Muscles)—consists of *six* muscles or sets of muscles, of which the fibres pass between contiguous Vertebræ.

Multifidus Spinæ	—*Origin*	Post. Surf. of Sacrum, as low as 4th Vert. ,, Sup. Spine of Ilium. ,, Sacro-iliac Ligaments, and Aponeurosis of Erector Spinæ, All the Lumbar Articular Processes, ,, ,, Dorsal Transverse ,, Lower five Cervical Articular ,,	—*Insertion*	Spines and Neural Arches of all the Vertebræ from the 2nd Cervical to the 3rd Sacral.
Rotators Dorsi (11)	— ,,	—Lower 11 Dorsal Trans. Proc., one from each	,,	Upper 11 Dorsal Laminæ, one to each.

Supraspinales —rudimentary, found upon Cervical Spinous Processes.
Interspinales — ,, in Dorsal Region, thin and flat in Lumbar Region, double in Cervical Region.
Intertransversales— ,, ,, ,, ,, ,, ,, ,, ,, ,, ,, ,,

Extensor Coccygis—passing from last piece of Sacrum over back of Coccyx (often absent).

If the attachments of the muscles situated in the upper part of the Dorsal Region and at the back of the Neck be examined in relation to each other as indicated in the Diagram, the following points may be noticed :—

The Spines of the Cervical Vertebræ are seen to be in the same line with the Spines of the Dorsal Vertebræ.
„ Articular Processes „ „ „ „ „ „ „ „ „ Transverse Processes „ „ „
„ Transverse „ „ „ „ „ „ „ „ „ Angles of the Ribs.

To each set of Processes in the Neck 4 Muscles or parts of Muscles of the Back are attached, excluding the more superficial muscles (those of the First Group) which are attached to the Spines; thus :—

To the Transverse Processes	Cervicalis Ascendens	(Insertion)	To the Articular Processes	Trachelo-mastoid	(Origin)	To the Spines	Splenius (Cap.) (Origin)
	Transversalis	(„)		Complexus	(„)		Complexus („)
	Splenius (Colli)	(„)		Semispinalis (Colli)	(„)		Semispinalis Colli (Insertion)
	Lev. Anguli Scapulæ	(Origin)		Multifidus Spinæ	(„)		Multifidus Spinæ („)

Of these muscles, two of those attached to the Transverse Processes (Splenius and Levator Anguli Scapulæ) and two of those attached to the Spines (Semispinalis and Multifidus Spinæ) are not symmetrical with the rest.

The remaining muscles are attached to *three* and *five* Vertebræ alternately.

Of these remaining muscles
the outermost, Cervicalis Ascendens, is attached below as low as the 6th Rib.
„ innermost, Splenius, „ „ „ „ „ Dorsal Spine.
„ rest, Complexus, Trachelo-mastoid and Transversalis, are „ „ „ „ „ Transverse Process.

The Transversalis is attached to Transverse Processes only.
„ Trachelo-mastoid „ „ „ „ and Articular Processes.
„ Complexus „ „ „ „ Articular and Spinous Processes.

The Origins of the Semispinalis Colli and Multifidus Spinæ in the Neck are similar to those of the Trachelo-mastoid and Complexus in the Neck respectively.

Besides the *four Groups* of Muscles above described, there are *four single* Muscles—special Extensors and Rotators of the Head—situated immediately below the Occiput.

Rectus Posticus Minor,—*Origin,* Tubercle on Posterior Arch of Atlas ; *Insertion,* Inferior Curved Line of Occipital Bone internally.
Rectus Posticus Major,— „ Spine of Axis „ „ „ „ „ externally.
Obliquus Inferior, — „ „ „ „ „ Transverse Process of Atlas.
Obliquus Superior, — „ Transverse Process of Atlas „ Interval between Curved Lines externally.

Six Muscles on each side enter into the formation of the Wall of the Abdomen :—

Three broad, transverse Muscles,—External Oblique, Internal Oblique, and Transversalis,—laterally.
Two narrow, vertical ,, —Rectus and Pyramidalis, —in front.
One ,, ,, Muscle, —Quadratus Lumborum, —behind.

The fibres of the *Ext. Oblique* run down and in, parallel to those of the Ext. Intercostal, hence its *origin* is said to be *above.*
,, ,, ,, *Int.* ,, ,, up ,, ,, ,, ,, ,, ,, Int. ,, ,, ,, ,, *below.*
,, ,, ,, *Transversalis* ,, transversely in, ,, ,, ,, *behind.*

The following Table gives the *attachments* of these Muscles :—

Common Points of Attachment.	**External Oblique.**	**Internal Oblique.**	**Transversalis.**
Ribs.	Lower *eight* (ext. surfaces) interdigitating with { Serratus Magnum. Latiss. Dorsi.	Lower *four* (edges of Cartilages) continuous with lowest two Internal Intercostals.	Lower *six* (under surfaces of Cartilages) interdigitating with Diaphragm.
Crest of Ilium.	Anterior $\frac{1}{2}$ of outer Lip.	Anterior $\frac{2}{3}$ of space between Lips.	Anterior $\frac{3}{4}$ of inner Lip.
Poupart's Ligament.	Whole length.	Outer half.	Outer third.
Spine of Pubes and Ilio-pectineal Line.	Spine only.	$\frac{1}{2}$ inch of Ilio-pectineal Line.	1 inch of Ilio-pectineal Line.
Front of Symphysis Pubes. Linea Alba.	Both.	Both.	Both.
Special Points of Attachment.	Pectoralis Major above.	Fascia Lumborum behind.	Fascia Lumborum behind.

On reference to the Diagram it will be seen, as regards the attachments of the Muscles to the Iliac Crest, to Poupart's Ligament and to the Ilio-pectineal Line, that in each case the Transversalis is attached most *externally*, the External Oblique most *internally*, and the Internal Oblique *intermediately.*

Anteriorly each Muscle becomes aponeurotic, and the Aponeuroses, crossing in front and behind the Rectus, join those of the opposite side to form the Linea Alba.

The **Aponeurosis** of the External Oblique is broader *below* than above.
,, ,, ,, Internal ,, ,, ,, *above* ,, below.
,, ,, ,, Transversalis ,, ,, *below* ,, above.
,, Linea Alba itself ,, ,, *above* ,, below.

As regards the relation of the Aponeuroses to the Rectus :—

For the upper ¾ths of the Rectus { the External Oblique Aponeuroses passes in front of it.
,, Transversalis ,, ,, behind it.
,, Internal Oblique ,, splits, half passing in front, half behind it.

For the lower ¼th ,, ,, —all three Aponeuroses pass in front of it.

Posteriorly, the posterior border of the External Oblique is usually free.
,, ,, ,, ,, Internal ,, and Transversalis are continued into the Fascia Lumborum.

Fascia Lumborum is attached { by *central* portion (lying between { Quadratus Lumborum and Erector Spinæ }) to Lumbar Transverse Processes (apices).
,, *ant.* reflection (covering ant. surf. of Quadratus Lumborum) ,, ,, ,, ,, (ant. surfaces
,, *post.* ,, (,, post. ,, ,, Erector Spinæ) ,, ,, Spines (apices).

For Abdominal Rings, Cremaster, etc., see 'Hernia.'

Rectus Abdominis { *Origin*, by two Heads { one from Symphysis Pubes (anterior surface).
,, ,, Crest of ,,
Insertion ,, ,, parts { ,, into Ensiform Cartilage.
,, ,, Cartilages of lower three true Ribs.

Lineæ Transversæ,—three { one opposite the Umbilicus.
,, ,, ,, Ensiform Cartilage.
,, intermediately between the other two.

Pyramidalis, —*Origin*, Front of Symphysis Pubes; *Insertion*, Linea Alba, half way between Pubes and Umbilicus.

All five of the above-described muscles are more or less attached to the front of the Symphysis Pubis.
As regards the attachment to the Ribs—note that the External Oblique is fixed to *eight*,
the Internal Oblique is fixed to half of that number, ,, *four*,
the Transversalis ,, ,, ,, the sum of the preceding ,, *six*,
and the Rectus ,, ,, ,, of that number, ,, *three*.

Quadratus Lumborum—*Origin* { Ilio-lumbar Ligament,
Crest of Ilium for 1 inch external to Ligament —*Insertion* { Lumbar Transverse Processes (Apices).
Last Rib, inner half of lower border.

An *Accessory Part* is sometimes found on the anterior surface of the Quadratus, connected above with the last Rib, and below with the apices of the lower two or three Lumbar Transverse Processes.

MUSCLES OF ABDOMINAL WALL AND OF THORACICIC WALL.

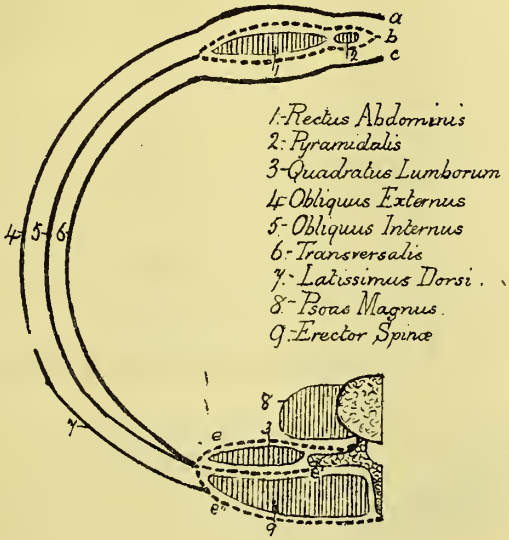

1.-Rectus Abdominis
2.-Pyramidalis
3.-Quadratus Lumborum
4.-Obliquus Externus
5.-Obliquus Internus
6.-Transversalis
7.-Latissimus Dorsi.
8.-Psoas Magnus.
9.-Erector Spinæ

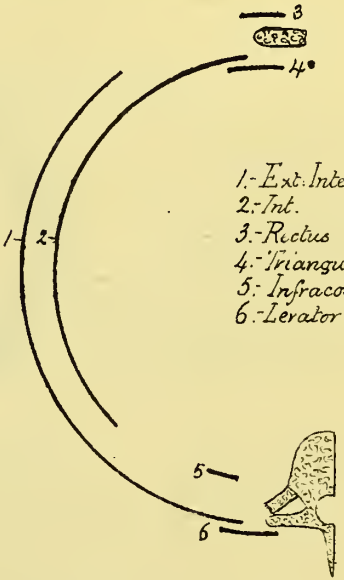

1.-Ext. Intercostal
2.-Int. "
3.-Rectus Sternalis
4.-Triangularis Sterni
5.-Infracostalis
6.-Levator Costæ.

a.-Aponeurosis of Ext. Oblique
b.- " Int. "
c " Transversalis.
} opposite upper three-fourths of Rectus.

e, e', e''.-Fascia Lumborum

PELVIC ATTACHMENTS OF LATERAL MUSCLES OF ABDOMEN.

T.- *Transversalis.*

I.- *Internal Oblique.*

E- *External Oblique.*

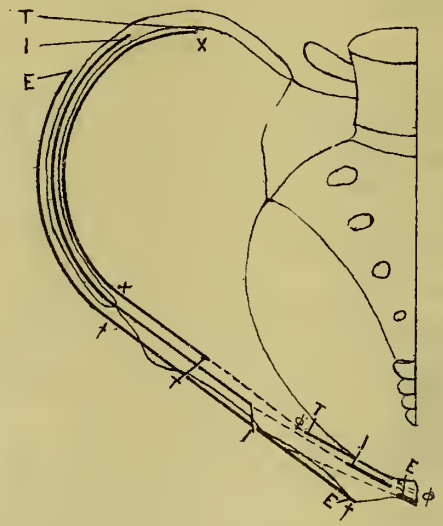

X – X.- *Attachments to Crest of Ilium.*

† – † - *Attachments to Poupart's Lig^t*

ϕ – ϕ - *Attachments to Ilio-pectineal Line etc.*

Six Muscles or sets of Muscles enter into the formation of the Thoracic Wall.

- *Two lateral* sets between Ribs, —External and Internal Intercostals.
- *Two posterior* ,, superficial to ,, —Levatores Costarum.
  - beneath ,, —Infracostales.
- *Two anterior* Muscles in front of Sternum,—Rectus Sternalis (rudimentary).
  - behind ,, —Triangularis Sterni.

Ext. Intercostals (11)
- *attached to* contiguous margins of the Ribs, from Tubercles to *Anterior* Angles.
- *extending* further forwards below than above, reaching to end of Cartilages in *lower two* Spaces.
- fibres are *directed* downwards and forwards.

Int. Intercostals (11)
- *attached to* contiguous margins of Ribs and Cartilages, from ant. extremities of Cartilages to *Post.* Angles of Ribs.
- *extending* further backwards above and below than intermediately.
- fibres are *directed* downwards and backwards. (In *lower two* spaces continuous with Internal Oblique).

Levatores Costarum (12)
- *arising*, the first from the Transverse Process of 7th Cerv. Vert., the others one from each Dorsal Transverse Proc.
- *inserted*, one into the upper border of each Rib, between the Tubercle and Posterior Angle.
- fibres *directed* parallel to those of *External* Intercostals—longer in *lower* than in upper spaces.

Infracostales (10 or less)
- *attached to* inner surfaces of contiguous Ribs between Tubercles and Posterior Angles.
- fibres *directed* parallel to those of *Internal* Intercostals—stronger in *lower* than in upper spaces.

Rectus Sternalis
- *lying* along lateral portion of anterior surface of Sternum.
- *united* above with Sterno-mastoid, below with Rectus Abdominis.

Triangularis Sterni
- *arising*
  - from under surface of Ensiform Cartilage and Cartilages of lower three true Ribs.
  - ,, side of Sternum as high as 3rd Cartilage.
- *inserted* into all the true Ribs (except the last two and the first) at the Costo-chondral Joints.

Those portions of the Muscles which are *external* (viz., the External Intercostals, Levatores Costarum and the parts of the Internal Intercostals between the Cartilages), are Muscles of Inspiration.

Those portions of the Muscles which are *internal* (viz., the Infracostales, the parts of the Internal Intercostals between the Ribs and the Triangularis Sterni), are Muscles of Expiration.

DIAPHRAGM—*attached*

- by special fasciculus to the posterior surface of the Ensiform Cartilage.
- ,, six fasciculi ,, under ,, ,, six lower Costal Cartilages on each side.
- to the Ligamenta Arcuata—Internum and Externum on each side between Ribs and Vertebræ.
- by the right Crus (the larger) to Bodies of 1st, 2nd, and 3rd Lumbar Vertebræ.
- ,, ,, left ,, (the smaller) ,, ,, 1st and 2nd ,, ,,

Of the **Central Tendon,** —the *right* leaflet is the largest, the *left* is the smallest, and the *middle* one is of medium size.

,, ,, **Ligamenta Arcuata**

- the *External*, overlying the Quadratus Lumborum, is attached to the last Rib & the 1st or 2nd Lumbar Trans. Proc.
- ,, *Internal* ,, ,, Psoas ,, ,, ,, Crus of Diaph. ,, ,, ,, ,, ,,

The Ligamenta Arcuata are formed by a thickening of the upper part of the anterior layer of the Fascia Lumborum.

Of the **Crura**

- the *outer* fibres in each case pass into the corresponding side of the Diaphragm.
- ,, *inner* ,, ,, ,, decussate with those of the opposite side, and curve round the opposite side of the Œsophageal opening.

Openings

- For Vena Cava, quadrilateral
  - *situated* in front and to right side of Aortic opening, between right and middle leaflets of Tendon.
  - *transmitting* the Vena Cava only. (*One* Vessel.)
- For Œsophagus, oval
  - *situated* in front and to left side of Aortic opening, between fibres of Crura after decussation.
  - *transmitting* Œsophagus and Pneumogastric Nerves. (*One* Tube and *one* pair of Nerves.)
- For Aorta
  - *situated* in front of the Vertebræ, between Crura before decussation.
  - *transmitting* Aorta, Vena Azygos Major and Thoracic Duct. (*One* Artery, *one* Vein and *one* Duct.)

The right and left Splanchnic Nerves and the Vena Azygos Minor pass through the corresponding Crus.
The right and left Sympathetic Cords pass under the Ligamenta Arcuata Interna, but the right cord sometimes perforates the right Crus.

IN MALE

Of posterior part.—*Three.*	**Sphincter Ani Ext.**	—Attachments	*behind*, tip of Coccyx and Superficial Fascia on each side. *in front*, Central Point of Perinæum ,, ,, ,, ,, ,, *intermediately* its fibres split to enclose the Anus.
	Levator Ani	Origin	*in front*, Body of Pubes near Symphysis (lower part of inner surface). *behind*, Spine of Ischium (,, ,, ,, ,,). *intermediately*, Pelvic Fascia immediately below White Line. Some of the most anterior fibres are connected with the Triangular Ligament.
		Insertion	*behind*, side of last piece of Coccyx. *in front*, Central Point of Perinæum. *intermediately*, lower part of Rectum. Between the fixed points of insertion it forms a raphé with its fellow.
	Coccygeus	Origin	—Spine of Ischium and Small Sacro-sciatic Ligament.
		Insertion	—Side of Coccyx and lower part of Sacrum.
Of Anterior part.—*Six.*	**Ischio-cavernosus*** **(Erector Penis)**	Origin	Inner surface of Tuber Ischii behind attachment of the Crus. ,, ,, Pubic Arch on each side ,, ,,
		Insertion	—by Aponeurosis into inner and outer surfaces ,, ,,
	Bulbo-cavernosus* **(Ejaculator Urinæ)**	Origin	—Central Point of Perinæum and median raphé.
		Insertion	by *posterior* fibres to Triangular Ligament. ,, *anterior* ,, ,, Corpus Cavernosum in front of Ischio-cavernosus. ,, *middle* ,, with its fellow in the median raphé on dorsum of Corpus Spongiosum.
	Transversalis Perinæi*	Origin	—Inner surface of Pubic Arch near Ischial Tuberosity.
		Insertion	—Central Point of Perinæum.
	Deep Transverse M.†	—Origin	—Pubic Arch close to Transversalis —Insertion, Central Point of Perinæum.
	Constrictor Urethræ†	—Origin	— ,, ,, above the Deep Transverse Muscle united with its fellow around Urethra.
	Circular Fibres†	—surrounding Urethra within the Constrictor, continuous behind with the circular fibres of the Prostate.	

* Superficial to Triangular Ligament.
† Between layers of ,, ,,

IN FEMALE,—the Muscles are arranged as in the Male, except in the points indicated below :—

Levator Ani invests the Vagina as in the Male it invests the Prostate.

Erector Clitoridis is smaller than the Erector Penis.

Sphincter Vaginæ (representing the Bulbo-cavernosus) { *behind* is connected with the Central Point of the Perinæum,
in front is reflected round the Corpora Cavernosa of the Clitoris,
intermediately surrounds orifice of Vagina and invests Bulb of Vestibule.

MUSCLES OF THE UPPER EXTREMITY.

MUSCLES OF THE SHOULDER.

Three pairs of Muscles (**A**) are specially concerned in the movements of the Shoulder-joint, and these are supplemented by *three other pairs* (**B**) which act upon the Shoulder-girdle (the Scapula and Clavicle). Lastly there is a third group of *three single Muscles* (**C**) whose chief function it is to retain the Head of the Humerus firmly against the Glenoid Fossa.

The Muscles of each pair present many analogies in origin, course of fibres, insertion and action.

The attachments, etc., as given on succeeding pages should be compared line by line.

A.—The muscles acting specially on the Shoulder-joint move the Humerus in *six* chief directions (see Diagram) thus :—

Pectoralis Major	moves the	Humerus	*downwards,*	*forwards*	and	*inwards*	across	front of Thorax.		
Latissimus Dorsi	,,	,,	,,	,,	*backwards*	,,	,,	,,	back	,, ,,
Coraco-brachialis	,,	,,	,,	*upwards,*	*forwards*	,,	,,	towards the Face.		
Deltoid (post. fibres)*	,,	,,	,,	,,	*backwards*	,,	,,	,,	,,	Occiput.
Teres Major	rotates	,,	,,	*inwards*	round its longitudinal axis.					
Teres Minor	,,	,,	,,	*outwards*	,,	,,	,,	,,		

* The other portions of the Deltoid draw the Humerus directly upwards.

	Pectoralis Major.	Latissimus Dorsi.
Origin	Inner ½ or ⅔ of Clavicle (anterior surface). Aponeurosis of External Oblique. Cartilages of lower six true Ribs, and side of Sternum.	Posterior ½ or ⅔ of Iliac Crest (outer lip). Aponeurosis of Multifidus Spinæ. Spines of lower six Dorsal Vertebræ, and Supraspinous Ligament.
Insertion	Outer lip of Bicipital Groove. sending three reflections { one to Capsule of Shoulder, ,, over Bicipital Groove, ,, to Fascia of Arm.	Floor of Bicipital Groove (next Pectoralis Major). { united below to lower edge of Teres Major. { separated above from Teres Major by a bursa, { ,, from long Head of Biceps by a synovial pouch.
Course of Fibres.	The Sternal portion is twisted on itself, so that its lowest fibres become highest at insertion. Edge forms anterior fold of Axilla.	The whole muscle is twisted on itself round Teres Major, so that the lowest fibres become highest at insertion. Edge forms posterior fold of Axilla.
	Beneath is found Accessory Muscle—the **Pectoralis Minor,**	*Beneath* are found Accessory Fibres,
Attachments	*below* to middle three true Ribs, *above* ,, Coracoid Proc. of Scapula (outer ½ of ant. border), *In action* giving increased security to the Joint by causing the Scapula to follow the movement of the Humerus produced by the Pectoralis Major.	*below* from lowest three Ribs, *above* ,, Inferior Angle of Scapula. *In action* giving security to the movement by steadying and retaining the Inferior Angle of the Scapula under cover of the Latissimus Dorsi. (Those from Inf. Angle only so act.)
	Coraco-brachialis.	**Deltoid.**
Origin	—*Coracoid* Process (tip).	*Acromion* Process (Outer edge). Clavicle (outer ½ of anterior surface). Spine of Scapula (lower border).
Insertion	On Inner Surface of Humerus about middle to a linear impression. Aponeurotic slip is reflected upwards to Capsule of Shoulder-joint.	On Outer Surface of Humerus about middle to a triangular impression. Separated by a large bursa from the Shoulder-joint.

Muscles of the Upper Extremity—*continued.*

	Teres Major.	Teres Minor.
Origin	Outer Border of Scapula (lower ⅔) and posterior surface of Inferior Angle. Intermuscular Septum.	Outer Border of Scapula (upper ⅔). Intermuscular Septum.
Insertion	Immediately *below* Small Tuberosity to inner edge of Bicipital Groove (for 2 inches). Immediately above Inner Head of Triceps.	Lowest Facet of Great Tuberosity, and bone *below* ,, ,, for 1 inch. Immediately above Outer Head of Triceps.

In addition to these six Muscles, the long Heads of the Biceps and Triceps assist in raising and depressing the Humerus.

Biceps, Long Head	cord-like and tendinous—lying above Head of Humerus within Capsular Ligament, giving fibres to the Glenoid Ligament.
Triceps, Long Head	flat and semi-muscular — ,, below ,, ,, outside ,, ,, ,, ,, Capsular ,,

Of these Muscles, the *first pair*—Pectoralis Major and Latissimus Dorsi—pass from the front and back of the Chest respectively in the anterior and posterior folds of the Axilla, and after twisting more or less on themselves, are inserted side by side into the Bicipital Groove.

The *second pair*—Coraco-brachialis and Deltoid—arise, the former from the Coracoid Process, the latter by its chief part from the Acromion Process, and passing, one to the outer and the other to the inner side of the Shoulder-Joint, are inserted half way down the corresponding side of the Humerus.

The *third pair*—Teres Major and Teres Minor—arise from equal lengths of the outer border of the Scapula, and are inserted, the former below the small Tuberosity above the Inner Head of the Triceps, the latter below the large Tuberosity above the Outer Head of the Triceps.

B.—The movements of the Humerus at the Shoulder-joint are supplemented by movements of the Scapula, produced by a second group of *three pairs* of Muscles connected with the Scapula and Clavicle.

As regards their *attachments* they may be grouped as follows :—

two	(a) Sterno-mastoid (b) Trapezius	connect the Shoulder-girdle with the Head.
two	(c) Levator Anguli Scapulæ (d) Rhomboideus Major with Rhomb. Minor	,, ,, ,, ,, ,, Spine.
two	(e) Serratus Magnus (f) Subclavius	,, ,, ,, ,, ,, Ribs.

And as regards their *action*, as follows :—

two (a and b) raise the Shoulder-girdle and *one* (f) depresses it,
two (c and e) draw the Scapula forwards and rotate it, and *one* (d) draws it backwards and rotates it.

The Scapula in its movements is not only drawn directly forwards, backwards or upwards, but is also rotated round a point situated a short distance behind the Glenoid Fossa.

MUSCLES ACTING ON SHOULDER-JOINT AND SHOULDER-GIRDLE.

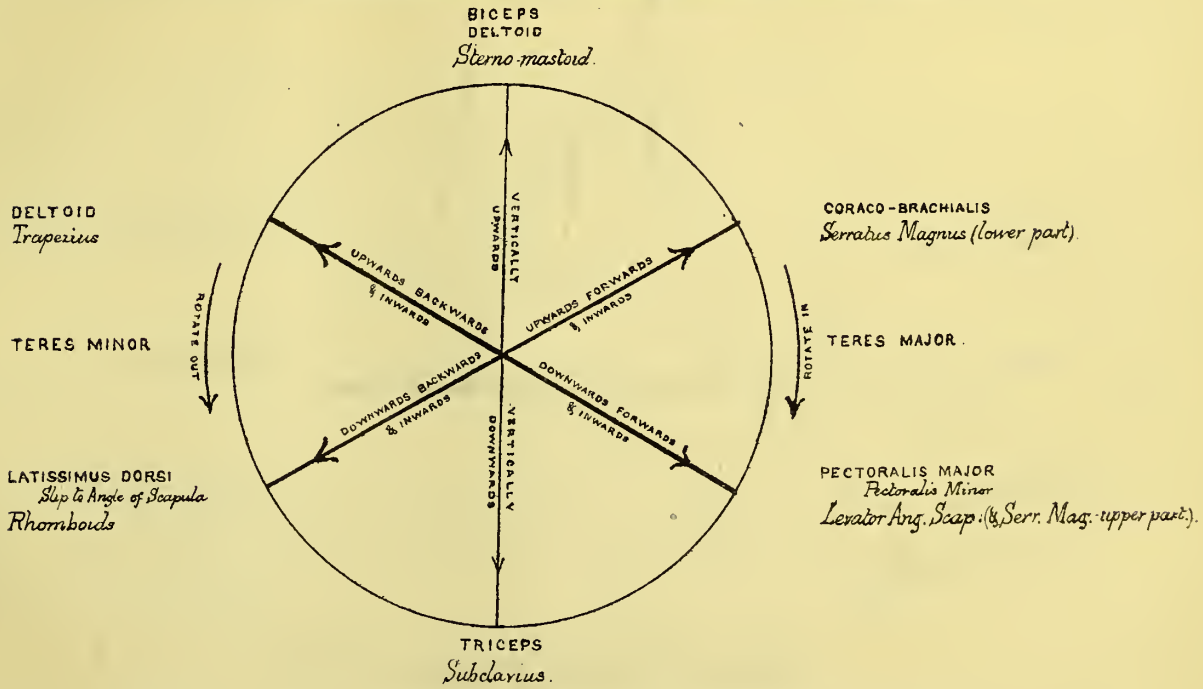

The names in capitals refer to Muscles of the Shoulder, those in italics to Muscles of the Shoulder-girdle.

MUSCLES OF SHOULDER-GIRDLE.

1:- Sterno-mastoid

2:- Trapezius

3:- Subclavius

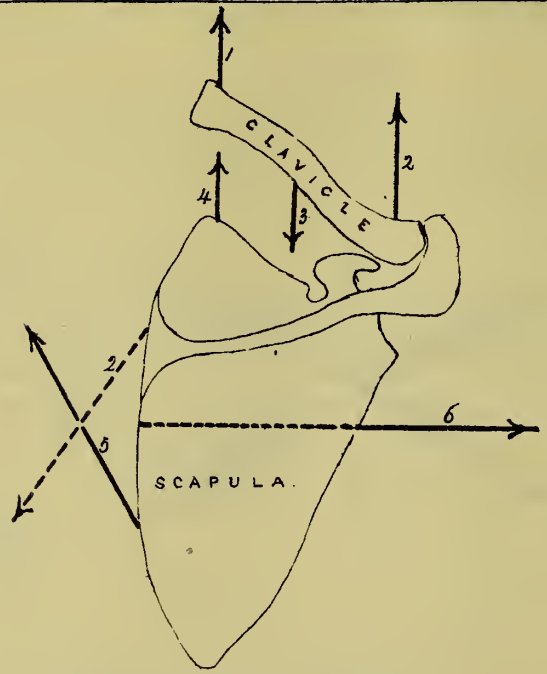

4:- Levator Anguli Scapulæ.

5 Rhomboidei

6:- Serratus Magnus.

To show lines of action of Muscles.

The Sterno-mastoid *raises* the Clavicle directly (though slightly).
The Trapezius *raises* the Acromion (directly by its upper fibres, indirectly by its lower fibres).
Both Muscles, acting together (assisted by the Levator Anguli Scapulæ) shrug the shoulder, that is, *raise* the whole shoulder-girdle directly.
Both Muscles also act on the Head as well as on the Shoulder-girdle, and are supplied by a Cranial Nerve, the Spinal Accessory, and by special branches of the Cervical Plexus.
The Subclavius directly *depresses* the Shoulder.

The Serratus Magnus, acting { by its upper fibres, turns the Acromion Process downwards and *forwards*.
„ „ lower „ „ „ „ upwards „ „
„ all its „ draws the Scapula directly forwards.
The Levator Anguli Scapulæ is allied in action to the upper fibres of the Serratus Magnus. (It also raises the Superior Angle of the Scapula, thus indirectly depressing the Acromion.)
The Rhomboids, drawing up and back the posterior border of the Scapula, indirectly depress the Shoulder; acting with the Trapezius (lower fibres) they draw the Scapula directly *backwards*.

Sterno-mastoid,* —*arising* from the Occipital and Temporal Bones, is *inserted* into the inner end of Clavicle and the Sternum.
Trapezius,* — „ „ „ Bone and Cerv. Dor. Spines „ „ outer „ „ „ the Spine of Scapula.

* For full origins and insertions see Muscles of Head and Back.

Subclavius, —*Origin* —1st Costal Cartilage at junction with Rib. *Insertion*—under surface of Clavicle between markings for Ligs.

Serratus Magnus { *Origin,* by *nine* slips from upper eight Ribs—two slips being connected with the 2nd Rib.
Insertion, „ *three* parts, into ant. surface of { upper angle of Scapula (by fibres from 1st and 2nd Ribs).
post. border „ „ („ „ „ 2nd, 3rd and 4th „).
lower angle „ „ („ „ „ 5th, 6th, 7th and 8th „).

Levator Anguli Scapulæ and **Rhomboids**—see Muscles of Back.

C.—The third group of Shoulder Muscles consists of *three* muscles, which, arising from the three fossæ of the Scapula, and lying in close relation with the Shoulder-joint, act as Ligaments retaining the Head of the Humerus in its socket.

Subscapularis, —*Origin* —Subscapular Fossa (inner $\frac{2}{3}$) and Fascia. *Insertion*—Small Tuberosity and bone below for 1 inch.
Supraspinatus, — „ —Supraspinal „ („ „) „ „ „ —Great „ highest facet.
Infraspinatus, — „ —Infraspinal „ („ „) „ „ „ — „ „ middle „

There are *three* **Bursæ** in connection with these Muscles :—
One under the Subscapularis *always* communicating with the Joint.
„ „ „ Infraspinatus *sometimes* „ „ „
„ over „ Supraspinatus *never* „ „

MUSCLES OF ELBOW.

There are *four* Muscles acting specially on the Elbow-joint,
two, Flexors —Biceps and Brachialis Anticus, lying *in front of* the Joint,
two, Extensors—Triceps „ Subanconeus „ *behind* „ „

Of these
- the Biceps and Triceps act also on the Shoulder, and are connected with the Ligaments *of* Shoulder-joint.
- the Brachialis Anticus & Subanconeus „ only „ Elbow „ „ „ its Ant. and Post. Ligaments.

Biceps
- *Origin*
  - *Long Head*, round tendon, from upper margin of Glenoid Cavity, in connection with Glenoid Ligament.
  - *Short* „ flattened „ „ apex of Coracoid Process „ „ „ Coraco-brachialis.
  - *a third* „ muscular, in connection with insertion of Coraco-brachialis (frequently).
- *Insertion*
  - Tubercle of *Radius*, posterior part (separated from anterior part by a bursa).
  - Deep Fascia of Forearm, over Pronator Teres, by Bicipital or Semilunar Fascia.

Triceps
- *Origin*
  - *Long Head*, flattened, from outer border of Scapula just below Glenoid Cavity for 1 inch, connected with Capsule.
  - *Outer* „ muscular „ post. surf. of Humerus above Musculo-spiral Groove, as high as insert. of Teres Minor.
  - *Inner* „ „ „ „ „ „ below „ „ „ „ „ „ „ Major.
- *Insertion*
  - Olecranon Process of *Ulna*, posterior part of upper surface (separated from anterior part by a bursa).
  - Deep Fascia of Forearm over Anconeus by a special aponeurosis.

Brachialis Anticus
- *Origin* —External and Internal surfaces of Humerus (lower half), and Intermuscular Septa.
- *Insertion*—Coronoid Process, lower and inner part of under surface.
  It is closely connected with the *Anterior* Ligament of the Elbow-joint.

Subanconeus
- *Origin* —The posterior surface of the Humerus above Olecranon Fossa.
- *Insertion*—Closely connected with the *Posterior* Ligament of the Elbow-joint.

The Biceps and Brachialis Anticus are supplied by the Musculo-cutaneous Nerve.
„ Triceps „ Subanconeus „ „ „ „ spiral „
The Brachialis Anticus also receives a branch from the „ „ „

Compare Origin and Insertion of Biceps and Triceps point by point.

MUSCLES OF SHOULDER AND ELBOW.

1.-Deltoid
2.-Coraco-brachialis
3-Pectoralis Major
4.-Latissimus Dorsi
5.- Teres Major
6.- Teres Minor

a.- Biceps
b.- Triceps
c.- Brach. Ant.
d-Subanconeus.

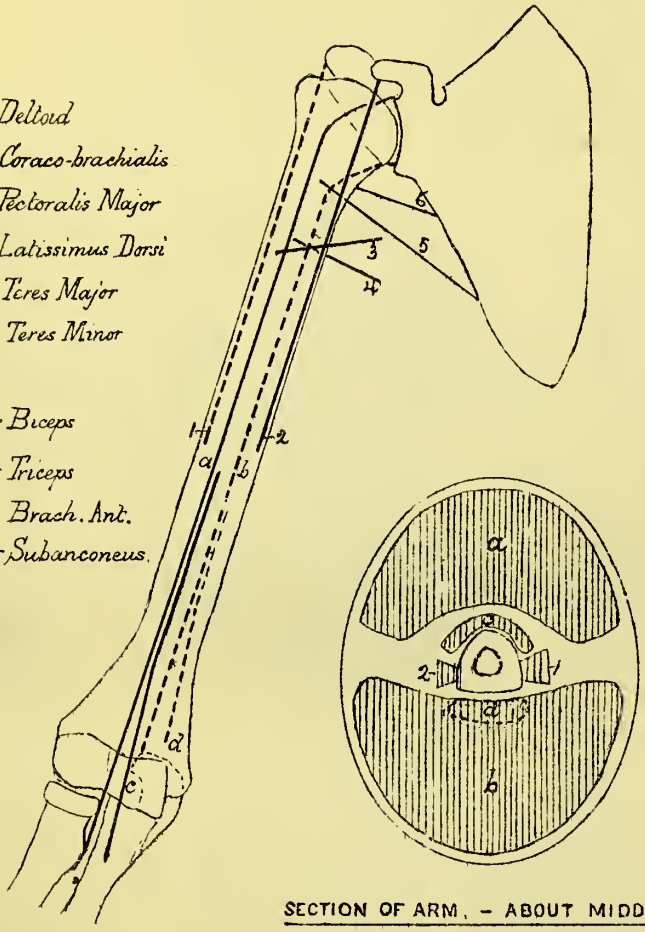

SECTION OF ARM, - ABOUT MIDDLE.

To indicate relative positions and directions of Muscles.

MUSCLES OF FOREARM.

1.-Pronator Teres.
2.-Flexor Carpi Radialis.
3.-Palmaris Longus.
4.-Flexor Carpi Ulnaris
5.-Flexor Sublimis Digit.
6.-Flexor Longus Pollicis.
7.-Flexor Prof. Digit.
8.-Supinator Longus
9.-Ext. Carpi Rad. Long.

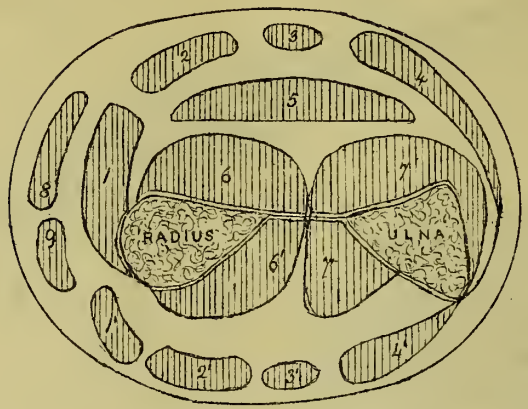

SECTION AT MIDDLE.

To indicate relative positions of Muscles.

1'-Ext. Carpi Radialis Brevior.
2'-Ext. Communis Digitorum.
3'-Ext. Minimi Digiti.
4'-Ext. Carpi Ulnaris.
6'-Ext. Ossis Metacarpi Pollicis.
7'-Ext. Secundi Internodii Poll.

The Ext. Primi Internodii & the Ext. Indicis are situated to the ulnar side of 6' and 7' respectively, but arise below the level of the section.

MUSCLES OF FOREARM.

On the Front of the Forearm there are *eight* Muscles—six Flexors and two Pronators.
,, ,, **Back** ,, ,, ,, *twelve* ,, —ten ,, ,, ,, Subspinators.

Both on the Front and Back the Muscles may be arranged in a *Superficial* Group, and a *Deep* Group.

On the Front { the Superficial Group consists of *one* Pronator and *three* Flexors of the Wrist.
,, Deep ,, ,, ,, ,, ,, ,, ,, ,, Fingers.

,, ,, **Back** { ,, Superficial ,, ,, ,, Supinator ,, *five* Extensors ,, Wrist and Fingers.
,, Deep ,, ,, ,, ,, ,, ,, Special Extensors.

,, ,, **Front** the Muscles of the Superficial Group arise from the *front* of the *Internal* Condyle of Humerus.
,, ,, **Back** ,, ,, ,, ,, ,, ,, ,, *back* ,, *External* ,, ,, ,,
,, ,, **Front & Back** ,, ,, ,, Deep ,, ,, ,, Bones of the Forearm.

,, ,, **Back** { excluding the *outer two* super. Muscles, viz. { one Supinator, ,, Extensor } —the *remaining four* resemble the four super. Muscles on the Front.
,, ,, *upper* ,, deep ,, ,, { ,, Supinator, ,, Extensor } — ,, ,, ,, ,, ,, deep ,, ,, ,,
(The two Muscles of each of the pairs excluded bear some analogy to each other.)

,, ,, **Front & Back**—Of the *four corresponding* muscles of the Superficial Group :— [arm.
The *outermost* and *innermost* arise each by two heads, one from the Common Tendon, the other from one of the Bones of the Fore-
,, *other two* arise each by one head, from the Common Tendon only.

,, ,, **Front & Back**—Of the *four corresponding* muscles of the Deep Group :—
One arises from the Radius, *one* from the Ulna, *one* from both Bones, and *one* is irregular.

Superficial Muscles on the Front of the Forearm.

	Pronator Teres.	**Flexor Carpi Radialis.**	**Palmaris Longus.**	**Flexor Carpi Ulnaris.**
Origins	2 Heads. { Internal Condyle. Side of *Coronoid* Proc. of Ulna. Median Nerve passes between Heads.	Internal Condyle.	Internal Condyle.	2 Heads. { Internal Condyle. Side of *Olecranon Proc.* and posterior border } of Ulna. Ulnar Nerve passes between Heads.

Superficial Muscles on the Back of the Forearm.*

	Ext. Carpi Radialis Brevior.	**Ext. Communis Digitorum.**	**Ext. Minimi Digiti.**	**Ext. Carpi Ulnaris.**
Origins	2 Heads. { External Condyle. Ext. Lateral Lig. of Elbow, and Orbic. Lig. (over Head of *Radius*).	External Condyle.	External Condyle.	2 Heads. { External Condyle. Posterior border of *Ulna* (middle ⅓).

These muscles are also connected with the Intermuscular Septa.

* Excluding the outer two, viz. Supinator Longus and Extensor Carpi Radialis Longior.

Deep Muscles on the Front of the Forearm.

	Pronator Quadratus.	Flexor Longus Pollicis.	Flexor Profundus Digitorum.	Flexor Sublimis Digitorum.
Origins	*Radius* } (lower 2 inches of each). *Ulna* } Aponeurosis over it.	*Radius* (anterior surface). Interosseous membrane. (Special Slip sometimes from Coronoid Pr.)	*Ulna* (ant. & int. surf., upper $\frac{3}{4}$) „ (post. border „ „) Interosseous membrane.	Int. Condyle of *Humerus*. Inner side of Coronoid Pr. of *Ulna*. Oblique Line of *Radius*. Internal Lateral Ligament and Intermuscular Septum.

Deep Muscles on the Back of the Forearm.*

	Extensor Ossis Metacarpi Pollicis.	Extensor Primi Internodii Pollicis.	Extensor Secundi Internodii Pollicis.	Extensor Indicis.
Origins	*Radius* (middle $\frac{1}{3}$). *Ulna* (for 2 or 3 inches below Anconeus). Interosseous Membrane.	*Radius* (below Extensor Ossis Metacarp.) Interosseous Membrane.	*Ulna* (2 or 3 in. below & behind Ext. Ossis Metacarp.) Interosseous Membrane for 1 inch below.	*Ulna* (2 or 3 in. below & behind Ext. Secundi Internodii) Interosseous Membrane for 1 inch below.

* Excluding the upper two, viz., the Supinator Brevis and the Anconeus.

The *Insertions* of the Muscles are given on the next page. Compare together, first the Muscles in each Group, and then each Muscle of each Group with the corresponding Muscle of the corresponding Group.

The *two remaining superficial* Muscles of the Back of the Forearm are attached as follows :—

Supinator Longus { *Origin* —External Supracondyloid Ridge (upper $\frac{2}{3}$) and Intermuscular Septum.
Insertion —Base of the Styloid Process of the Radius.

Extensor Carpi Radialis Longior { *Origin* —External Supracondyloid Ridge (lower $\frac{1}{3}$) and Intermuscular Septum.
Insertion —Base of the 2nd Metacarpal Bone.

The *two remaining deep* Muscles on the Back of the Forearm are attached as follows :—

Supinator Brevis, —*Origin* { External Condyle of Humerus
External Lateral Ligament of Elbow
Ulna below Lesser Sigmoid Cavity for 1 or 2 inches } —*Insertion* { *Radius* (post., ext., & ant. surfaces above Oblique Line).

Anconeus, — „ —External Condyle (by distinct Tendon) — „ { *Ulna* (post. surface above Oblique Line).

The two former Muscles have somewhat similar origins, the two latter somewhat similar insertions.

The relative and analogous positions of the Muscles at about the Middle of the Forearm are shown in the Diagram.

Muscles on the Front of the Forearm (*Insertions*, etc.).

Pronators	**Pronator Teres,**	—*inserted* into middle of outer border and contiguous surfaces of Radius.
	Pronator Quadratus,	—attachments given above.
Flexors of Wrist	**Flexor Carpi Radialis**	passing *between* outer attachments of Annular Ligament (viz., { ridge & body } of Trapezium). is *inserted* into Bases of 2nd and 3rd Metacarpal Bones.
	Palmaris Longus	passing *over* Annular Ligament, *ends* in Palmar Fascia, by which it is connected with Phalanges of Fingers.
	Flexor Carpi Ulnaris	*falling short* of Annular Ligament, is *inserted* into Pisiform Bone, sending on fibres to Bases of 4th and 5th Metacarpal Bones.
Flexors of Fingers	**Flexor Sublimis Digitorum**	Its four Tendons pass *under* Annular Lig. in pairs { those of larger fingers (3rd and 4th) in front. ,, ,, smaller ,, (2nd ,, 5th) behind. Each Tendon, dividing opposite 1st Phalanx to transmit tendon of Deep Extensor, is *inserted* upon sides of 2nd Phalanx of Finger.
	Flexor Profundus Digitorum	Its four Tendons pass *under* Annular Ligament beneath those of Flexor Sublimis, and are *inserted* into Bases of last Phalanges of Fingers after perforating Tendons of Flexor Sublimis.
	Flexor Longus Pollicis	Tendon passes *under* Annular Ligament, and between Heads of Flexor Brevis Pollicis, and is *inserted* into Base of last Phalanx of Thumb.

Muscles on the Back of the Forearm (*Insertions*, etc.).

For **Supinators Longus** and **Brevis** and **Anconeus,** see above.

Ext. of Wrist	**Extensor Carpi Radialis Longior,**	—passing *beneath* Ext. Tendons of Thumb, is *inserted* into Base of 2nd Metacarpal Bone (outer side).
	Extensor Carpi Radialis Brevior,	— ,, ,, ,, ,, ,, ,, ,, ,, ,, 3rd ,, ,, (,, ,,).
	Extensor Carpi Ulnaris,	—is *inserted* into Base of 5th Metacarpal Bone (inner side).

Ext. of Fingers

Extensor Communis Digitorum, —divides into three Tendons, the inner one subdividing later into two :—

Each Tendon { becomes aponeurotic over the 1st Phalanx and unites with tendons of { Interossei and Lumbricales.
divides over head of 1st Phalanx into three { the middle piece ending on base of 2nd Phalanx,
,, lateral pieces ,, ,, ,, 3rd ,,

Extensor Indicis, —joins tendon of Extensor Communis to Index Finger.

Extensor Minimi Digiti, —tendon divides into two portions, which join tendon of Ext. Communis to Little Finger.

Ext. of Thumb

Extensor Ossis Metacarpi Pollicis, —passing over Extensores Carpi Radialis, ends on Base of 1st Metacarpal of Thumb.

Extensor Primi Internodii Pollicis— ,, ,, ,, ,, ,, ,, ,, 1st Phalanx ,, ,,

Extensor Secundi Internodii Pollicis— ,, ,, ,, ,, ,, ,, ,, 2nd ,, ,, ,,

There are thus on the Back of the Forearm *one* Extensor of the Forearm and *two* Supinators, *three* Extensors of the Wrist, *three* Extensors of the Thumb, and *three* Extensors of Fingers.

The **Synovial Sheaths** at the back of the Wrist correspond with the Grooves on the Bones, for which see 'Radius' and 'Ulna.'

MUSCLES OF THE HAND.

There are *three* Flexors and *three* Extensors of the Thumb.
,, ,, *four* ,, ,, *two* ,, ,, Little Finger.
,, ,, *two* ,, ,, ,, ,, ,, Index ,,
,, ,, ,, ,, ,, *one* Extensor ,, 3rd and 4th Fingers.

The Thumb and the Little Finger have each a special Abductor, and the Thumb has also a special Adductor.
The Index, Middle, and Ring Fingers have each two Interossei attached to them, which act, the one as Abductor and the other as Adductor.
The 3rd Palmar Interosseous is the Adductor of the Little Finger.

Muscles of the Thumb.

The Extensors of the Metacarpal Bone and of the 1st and 2nd Phalanges, and the Long Flexor, have been mentioned previously.

Abductor, —*Origin*—Trapezium (ridge) and Annular Ligament *Insertion*,—1st Phalanx (outer side of base).
Flexor Ossis Metacarpi (Opponens) } ,, — ,, ,, ,, ,, ,, ,, —Metacarpal Bone (front and outer border).
Flexor Brevis, — ,, { Trapezoid and ,, ,, Os Magnum and bases of 2nd & 3rd Metacarpals ,, —by two Heads { one with Abductor, one with Adductor.
Adductor, — ,, —3rd Metacarpal (lower ⅔ of Shaft) ,, —1st Phalanx (inner side of base).

MUSCLES OF HAND.

1.- Abductor Pollicis

1'- " Minimi Digiti

2.- Flexor Brevis Pollicis

2'- " " Min. Dig.

3- Opponens Pollicis

3'- " Minimi Dig.

4.- Adductor Pollicis

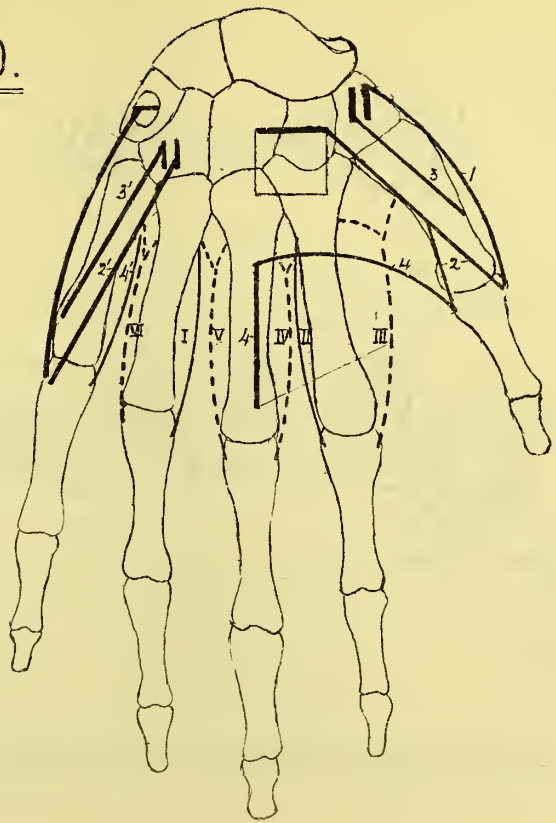

RELATIVE POSITIONS.

4'.- 3rd Palmar Inteross. (Add Min. Dig.).

I.- 2nd " " .

II 1st " "

III.- 1st Dorsal Inteross (Abd Indicis).

IV - 2nd " "

V - 3rd " "

VI - 4th " "

MUSCLES OF HAND.

I-V.- Metacarpal Bones.
1.- Abductor Pollicis
1'- " Min. Dig.
2.- Flexor Brevis Pollicis
2'- " " Min. Dig.
3.- Flex. Oss Met. (Opp.) Poll.
3'- " " " Min Dig.
4.- Adductor Pollicis.
4'- 3rd Palmar Inteross (Add. M^n D^i).
5.- 2nd " "
6.- 1st " "
7- 1st Dorsal " (Abd. Ind.).

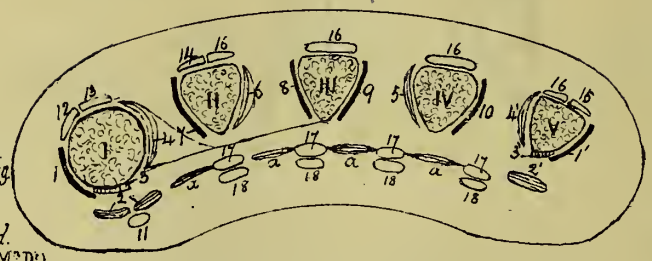

8.- 2nd Dorsal Interosseous.
9.- 3rd " "
10.- 4th " "
11.- Flex. Longus Pollicis.
12.- Ext. Primi Internodii Poll.
13.- " Sec. " "
14.- " Indicis
15.- " Minimi Digiti.
16.- " Communis Digitorum
17.- Flexor Profundus "
18.- " Sublimis "
a.- Lumbricales.

To show relative positions of Muscles on transverse section of Hand.

Muscles of the Little Finger.

The Extensor Minimi Digiti, Extensor Communis, Flexor Sublimis and Flexor Profundus Digitorum have been mentioned previously.

Abductor,	—*Origin*	Pisiform Bone Tendon of Flex. Carpi Ulna	*Insertion*—1st Phalanx (inner side of base).
Flexor Ossis Metacarpi (Opponens)	— ,,	Unciform Process of Unciform Annular Ligament	,, —Metacarpal Bone (inner margin).
Flexor Brevis,	— ,,	—Annular Ligament	,, —with Abductor.

The *first* two (outer two) Muscles of the Thumb have a common origin, as have also the *last* two (outer two) Muscles of the Little Finger. All four arise from the Annular Ligament.

Overlying the Muscles of the Little Finger is the **Palmaris Brevis** { *arising* from Annular Ligament and Palmar Fascia. *inserted* into skin of Ulnar side of Palm.

The **Lumbricales** are connected with the Tendons of the Flexor Profundus Digitorum.

the 1st and 2nd *arising* from radial sides of the tendons to the Index and Middle Fingers respectively.
,, 3rd ,, 4th ,, ,, contiguous ,, ,, ,, ,, { Middle and Ring ,, / Ring and Little ,,

Passing to the radial side of the corresponding finger, each *ends* in the Extensor Aponeurosis.

Interossei.

Dorsal (4)
- *Origin* —one in each Intermetacarpal Space, from the contiguous sides of the Metacarpal Bones.
- *Insertion* { Bases of 1st Phalanges of the Middle three Fingers, two being fixed to the Middle Finger, thus :—
  the **1st** on outer side of Index Finger, the **4th** on inner side of Ring Finger,
  the **2nd** and **3rd** on opposite sides of Middle Finger.
  A few fibres from each join the Extensor Aponeurosis over the 1st Phalanx.

Palmar (3)
- *Origin* —Metacarpal Bones of Index, Ring and Little Fingers.
- *Insertion* —Bases of 1st Phalanges ,, ,, ,, ,, ,, ,,
  the **1st** on the inner side, the **2nd** and **3rd** on the outer side of the Fingers to which they belong.

The Lumbricales pass from the Flexor Tendons to the Extensor Aponeuroses.
,, Interossei ,, ,, Metacarpal Bones ,, ,, ,, and the 1st Phalanges.

MUSCLES ACTING UPON THE HIP AND KNEE-JOINTS.

The Muscles acting upon the Hip-joint may be divided into **six Groups**; *four* of these Groups are specially concerned with the movements of the Hip, the other *two* chiefly with those of the Knee.

In each of *two Groups* of the former set there are *six Muscles*, in each of the other *two Groups* there are *three*.
One of the muscles of each of these four Groups extends below the Knee and acts upon it as well as upon the Hip.
The other ,, ,, ,, ,, ,, are attached to the Femur and act only upon the Hip.

As in the Upper Extremity, the **movements** produced by the Muscles of each of these four Groups are *compound*, thus :—

The	**First**	**Group**	consists of	*three*	**Flexors**	(a),	which also rotate out	(b)	and adduct slightly	(c).
,,	**Second**	,,	,,	,, *six*	**Adductors**	(c),	,, ,, flex	(a)	,, rotate out	(b).
,,	**Third**	,,	,,	,, *three*	**Rotators in**	(b′),	,, ,, abduct	(c′)	,, flex	(a).
,,	**Fourth**	,,	,,	,, *six*	**Rotators out**	(b),	,, ,, abduct	(c′)	,, extend	(a′).

FLEXORS—*three*—two acting on the Hip and one on the Hip and Knee.

Iliacus
- *Origin* —Iliac Fossa *intermediately*, Ilio-lumbar Ligament *behind*, and Capsular Ligament of Hip *in front*.
- *Insertion*—Small Trochanter (*lower edge*) and surface of Femur below and in front of it.

Psoas Magnus
- *Origin*
  - Contiguous borders of Bodies of last Dorsal and all the Lumbar Vertebræ and intermediate Intervert. Discs.
  - Roots of Transverse Processes of ,, ,, ,, and fibrous arches over lateral surfaces [of Bodies.
- *Insertion*—Small Trochanter (*apex*).

(Psoas Parvus arises with the 1st slip of origin of Psoas Magnus, and ends below in the Ilio-pectineal Eminence and Iliac Fascia.)

Sartorius
- *Origin* —Anterior Superior Spine of Ilium and half the Notch below it.
- *Insertion*—Tibia, inner surface for 1½ in. by the side of Tubercle, giving expansions to Fascia of Leg and Int. Lateral Lig.

In front of the Hip-joint the Psoas is *tendinous* and is *separated* from the Capsule by a bursa, whilst the Iliacus is *muscular* and is *united* to the Capsule by muscular fibres.

These Muscles are the outer three of the six entering into the formation of Scarpa's Triangle, and are supplied by special branches of the Lumbar Plexus or of the Anterior Crural Nerve.

SECTION OF THIGH.

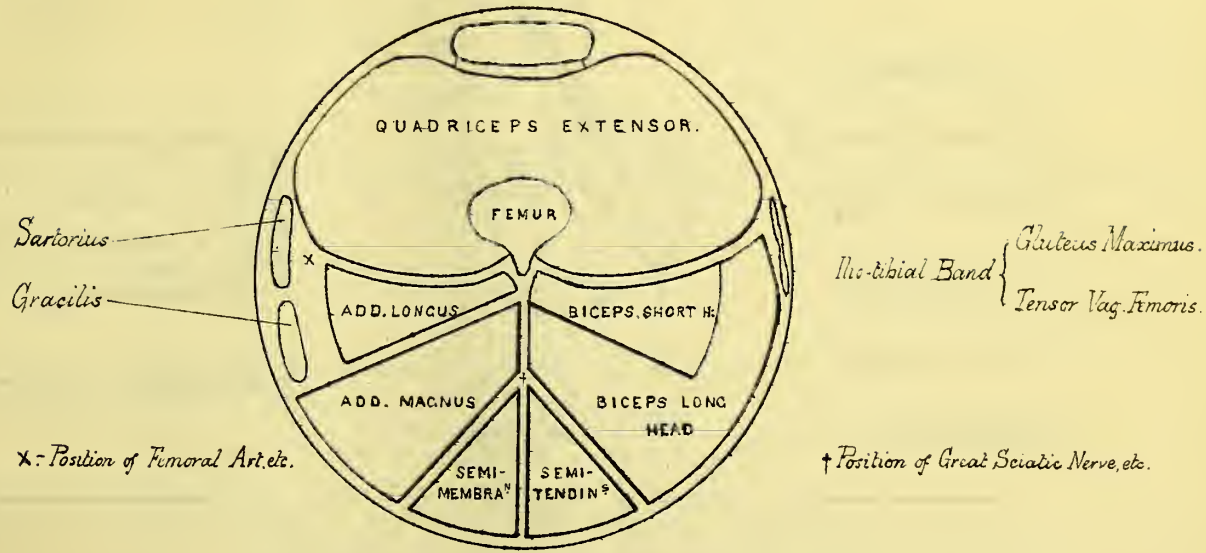

To indicate relative positions of Muscles about middle ⅓ of Thigh.

PSOAS MAGNUS, ETC.

1.- Ilio-hypogastric N.

2.- External Cutaneous N.

3.- Anterior Crural N.

1'.- Ilio-inguinal N.

2'.- Genito-crural N.

3'- Obturator N.

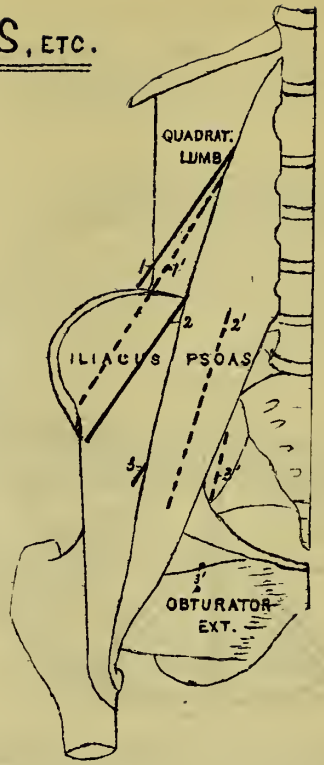

RELATION TO NERVES.

-The Nerves emerge
- 1- near upper end of outer edge of Psoas.
- 3- " " " " "
- 2- " mid-point " " "
- 1'- at outer border of Psoas above
- 3'- " inner " " below
- 2'- through ant. surf " intermediately

For other Relations see "Lumbar Plexus."

ADDUCTORS, *six*—five acting on the Hip and one on the Hip and Knee.

Pectineus	—*Origin**	Triangular Surf. on Pubes, ant. to Ilio-pectineal Line	*Insertion*†	Femur behind and below Small Trochanter. Upper ½ of line from Linea Aspera to ,, ,,
Adductor Brevis,	— ,,	—Ramus of Pubes	,,	—Line from ,, ,, ,, ,,
Adductor Longus,	— ,,	—Body ,, ,, below Crest	,,	—Linea Aspera (inner lip).
Adductor Magnus,	— ,,	Rami of Pubes and Ischium, and Tuber Ischii	,,	—Interspace between upper divis. of Linea Aspera.
Obturator Externus	— ,,	Inner ½ of margin of Obturator Foramen ,, ,, Obturator Membrane	,,	—Digital Fossa on inner surface of Great Trochanter.
Gracilis,	— ,,	—Rami of Pubes and Ischium	,,	Tibia, for ½ inch, behind upper part of Tendon of Sartorius.

These Muscles are supplied by the Obturator Nerve. The first three are the inner three of the six entering into the formation of Scarpa's Triangle. At their *Origins* the attachments of the Pectineus, Add. Magnus and Quadratus Femoris surround circumferentially that of the Obturator Externus, whilst those of the Add. Longus, Add. Brevis and Gracilis overlap along the margin of the Pubic Arch. At their *Insertions* the attachments of the Iliacus, Pectineus and Add. Brevis overlap.

* See Diagram and Description of Innominate Bone for this and succeeding Muscles.
† ,, ,, ,, ,, ,, Femur ,, ,, ,, ,,

ROTATORS IN, *three*—two acting on the Hip and one on the Hip and Knee.

Gluteus Medius	*Insertion*	—Oblique Line on *external* surface of Great Trochanter.
	Origin	—Concave surface between Superior and Middle Curved Lines of Ilium and Gluteal Aponeurosis.
Gluteus Minimus	,,	—Convex ,, ,, Middle ,, Inferior ,, ,, ,,
	Insertion	—Rough facet on *anterior* surface of Great Trochanter.
Tensor Vaginæ Fem.	*Origin*	—Outer lip of Iliac Crest for anterior two inches.
	Insertion	—Ilio-tibial band of Fascia Lata three inches below and in front of Great Trochanter.

These Muscles are supplied by the Superior Gluteal Nerve.

ROTATORS OUT AND EXTENSORS, *six*—five acting on the Hip and one on the Hip and Knee.

Pyriformis	*Origin*	Middle three pieces of Sacrum, between anterior Sacral Foramina. *Above* from margin of Sacro-sciatic Foramen, and *below* from Sacro-sciatic Ligaments.
	Insertion	—*Post Facet* on upper border of Great Trochanter, separated from Capsule of Hip by Obt. Int. Tendon.
Obturator Internus	*Origin*	Obturator Membrane and margin of Obturator Foramen, except above and in front. Pelvic Fascia, and inner surface of Body of Ischium ,, below ,, behind.
	Insertion	—*Anterior Facet* on upper border of Great Trochanter along with Gemelli.

Gemellus Superior, —*Origin* —Outer surface of Spine of Ischium
Gemellus Inferior, — ,, — ,, border ,, Tuber. ,, ,, (upper part) } *Insertion*—with Obturator Internus.

Quadratus Femoris,— ,, — ,, ,, ,, ,, ,, ,, ,, —Linea Quadrati.

Gluteus Maximus
- ,, Posterior ⅓ of Crest of Ilium and Bone below it. (*Bone*).
  Aponeurosis of Multifidus Spinæ (*Aponeurosis*).
  Back of lowest piece of Sacrum and back of Coccyx (*Bone*).
  Great Sacro-sciatic Ligament (outer surface) (*Ligament*).
- *Insertion* { *upper* ⅔ of muscle and *lowest* fibres } into Fascia Lata (Ilio-Tibial Band).
  intermediate ,, ,, Line leading from Great Trochanter to Linea Aspera.

Relation of Muscles to the Hip-joint.

The Muscles specially in relation with the Capsule of the Hip-joint are arranged as follows:

Behind and *below* the Capsule—Obturator Externus Tendon.
In front of ,, ,, —Psoas and Iliacus.
Above ,, ,, —Obturator Internus Tendon with Gemelli.
Above and *behind* ,, ,, —Pyriformis Tendon separated from Capsule by Obturator Internus Tendon.
Behind ,, ,, —Quadratus ,, ,, ,, ,, Obturator Externus ,,

The Muscles lie in one turn of a spiral round the Capsule (see Diagram).
Fasciculi are sent into the Capsule above and in front { by the Rectus (Reflected Head) internally. ,, ,, Gluteus Minimus Tendon externally.

The remaining two Groups (the Fifth and Sixth) which act on the Hip, act also and chiefly on the Knee.
The **Fifth Group** consists of *three* Muscles which supplement the **Extensors** of the Hip and are also Flexors of the Knee.
,, **Sixth** ,, ,, *one* Muscle ,, supplements ,, **Flexors** ,, ,, ,, is ,, an Extensor ,, ,,

In addition to these there are one Flexor and three Extensors of the Knee only, and two Flexors of the Knee and Extensors of the Ankle.

EXTENSORS OF HIP AND FLEXORS OF KNEE.

Biceps, —*Origin* { *Short Head,* Linea Aspera (outer lip) / *Long* ,, *lower & inner* facet on Tuber Ischii } *Insertion* { Fibula, outer side of Head by double tendon. in front and behind the Long Ext. Lateral Lig.

Semi-membranosus,— ,, — *Upper & outer* ,, ,, ,, ,, { Tibia, Groove on back of Internal Tuberosity. giving 3 offsets to { Internal Lateral Ligament of Knee. Posterior Ligament ,, ,, Fascia over Popliteus.

Semi-tendinosus, — ,, —with Long Head of Biceps ,, { Tibia, for ½ in. behind lower part of insertion of Sartorius.

MUSCLES. IN RELATION WITH NECK OF FEMUR.

1.- Tendon of Obturator Ext.
2.- Psoas & Iliacus.
3.- Obturator Int. with Gemelli
4.- Pyriformis
5.- Quadratus Femoris
6.- Offset from Glutæus Min.

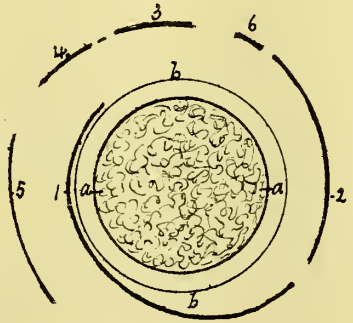

To indicate relative position of the Muscles in relation with the Joint-Capsule as seen on transverse section of it (a) and of the Neck of the Femur (b).

MUSCLES ARISING FROM TUBER ISCHII.

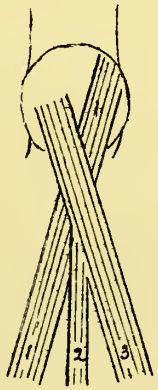

1.- Semi-membranosus.

2.- Semi-membranosus.

3.- Biceps (Long Head).

To show relation of the Muscles at & just after origin.

FLEXOR OF KNEE.

Popliteus	—*Origin*	Groove on outer side of External Condyle Posterior Ligament of Knee-joint	*Insertion*	Tibia, posterior surface above Oblique Line.

FLEXOR OF HIP AND EXTENSOR OF KNEE.

Rectus Femoris	—*Origin*	*Straight Head* Ant. Inf. Spine of Ilium *Reflected* „ rough groove above Acetabulum	„	—Patella (upper border) with the Vasti.

EXTENSORS OF KNEE.

Vastus Externus	—*Origin*	Root of Great Trochanter, ant. and ext. Line from „ „ to Linea Aspera Linea Aspera (upper half) and Ext. Intermusc. Sept.	„	— „ (external border).
Vastus Internus with Crureus	„	Ant. and lat. Surf. of Shaft of Femur (upper $\frac{3}{4}$) Both Intermuscular Septa	„	— „ (internal „).
Subcrureus,	— „	—Femur, anterior surface (lower $\frac{1}{4}$)	„	—Synovial Membrane of Knee-joint.

FLEXORS OF KNEE AND EXTENSORS OF ANKLE.

Gastrocnemius	—*Origin*	by *Inner Head*, from upper & *outer* part of Int. Condyle „ *Outer* „ „ „ part of *outer* surf. of Ext. „	„	—Os Calcis by Tendo Achillis.
Plantaris	— „	External Supracondyloid Ridge Posterior Ligament of Knee-joint	„	—with Tendo Achillis.

The Heads of the Gastrocnemius both arise from the outer side of the corresponding Condyle.
The fibres of the *inner* head of the Gastrocnemius descend lower than those of the outer head.
„ „ „ Vastus *Internus* „ „ „ „ Vastus Externus.
The Plantaris and Popliteus both arise from the Posterior Ligament of the Knee-joint.

There are thus in all *fourteen* Muscles acting on the Knee-joint.

Eight	Biceps Semi-tendinosus Semi-membranosus Rectus Femoris	with the	Sartorius Gracilis Tensor Vag. Fem. through Ilio-tibial Band Gluteus Max.	acting on Hip and Knee.
Four	Vastus Internus Vastus Externus	with the	Subcrureus Popliteus	„ „ Knee only.
Two	Gastrocnemius, Plantaris			„ „ Knee and Ankle.

The three Muscles attached by the side of the Tubercle of the Tibia (Sartorius Gracilis and Semitendinosus) arise from the most prominent points of the Ilium, Pubes and Ischium respectively.

MUSCLES OF THE FRONT OF THE LEG.

Of the *four* Muscles on the front of the Leg (Flexors of Ankle and Extensors of Toes)

two, Tibialis Anticus and Extensor Longus Digitorum, are long, attached, the former to the Tibia, the latter to the Fibula chiefly.
two, Extensor Proprius Pollicis and Peroneus Tertius ,, short, and alternate with the others, both being attached to the Fibula.

Tibialis Anticus,	—*Origin*	—Outer surface (upper $\frac{2}{3}$)		and outer Tuberosity of Tibia, Interosseous Membrane & Fascia.
Ext. Longus Digitorum,	— ,,	—Ant. ,, (upper $\frac{3}{4}$) of Fibula	,, ,, ,, ,, ,, ,, ,, ,, ,,	
Ext. Proprius Pollicis,	— ,,	— ,, ,, (middle $\frac{3}{5}$)	,, ,,	and Interosseous Membrane.
Peroneus Tertius,	— ,,	— ,, ,, (lower $\frac{1}{4}$)	,, ,, ,, ,, ,,	
Tibialis Anticus,	—*Insertion*	—Base of *first* Metatarsal Bone, and Internal Cuneiform.		
Peroneus Tertius,	— ,,	— ,, ,, *last* ,, ,,		
Ext. Longus Digitorum,	— ,,	—by four tendons into Bases of 2nd and 3rd Phalanges of four outer toes, as in the Hand.		
Ext. Proprius Pollicis,	— ,,	— ,, one tendon ,, Base of 2nd Phalanx of Great Toe.		

MUSCLES OF THE OUTER SIDE OF THE LEG.

Peroneus Brevis,	—*Origin*	—Fibula, lower $\frac{2}{3}$ of outer surface and Fascia	*Insertion*—Base of *first* Metatarsal Bone.
Peroneus Longus,	— ,,	— ,, upper ,, ,, ,, ,, ,, ,,	— ,, ,, *last* ,, ,,

The tendons lie in the same groove behind the External Malleolus, and are invested by a common Synovial Sheath, but lie in separate grooves on the outer side of the Os Calcis, lined by prolongations from the common Sheath. The tendon of the Peroneus Longus is invested by a special Synovial Sheath as it lies in its canal in the Sole of the Foot.

MUSCLES ON THE BACK OF THE LEG.

Of the *six* Muscles on the Back of the Leg,

two, the Plantaris and Gastrocnemius, are Flexors of the Knee and Extensors of the Ankle,
two, the Soleus and Tibialis Posticus ,, Extensors of the Ankle only.
two, the Flexor Longus Digitorum and Flexor Longus Pollicis ,, ,, ,, ,, and Flexors of the Toes.

The attachments of the first two have been already mentioned; the remaining four arise from the bones of the Leg; the Soleus and Tibialis Posticus from both, the Flexor Longus Pollicis from the Fibula, and the Flexor Longus Digitorum from the Tibia.

(The Muscle passing to the *inner* side of the Foot arises from the *outer* Bone of the Leg, and *vice versâ*.)

MUSCLES OF FRONT OF LEG.

1.-Peroneus Tertius

2-Ext. Longus Digit.

3.- Ext. Prop. Pollicis.

4-Tibialis Anticus

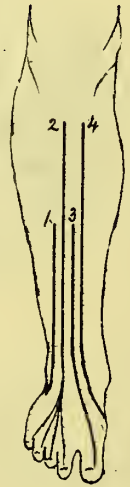

MUSCLES OF BACK OF LEG.

5.-Flexor Longus Digit.

6.-Tibialis Posticus

7.-Flexor Longus Pollicis

8.-Peroneus Brevis.

9.-Peroneus Longus.

To indicate relative position & length.

SECTION ABOVE ANKLE.

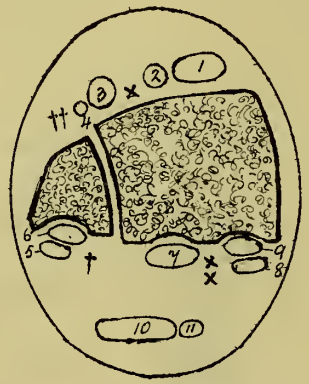

1.- Tibialis Anticus.
2.- Extensor Proprius Pollicis.
3.- Extensor Longus Digit.
4.- Peroneus Tertius.
5.- " Longus
6.- " Brevis.
7.- Flexor Longus Pollicis.
8.- Flexor Longus Digit.
9.- Tibialis Posticus
10.- Tendo Achillis
11.- Plantaris [Vessels etc.
X.- Ant. Tibial & XX. Post. Tibial
†.- Peroneal & ††. Ant. Peroneal
T.- Tibia & F. Fibula. [Vessels.

SECTION AT MIDDLE THIRD OF LEG.

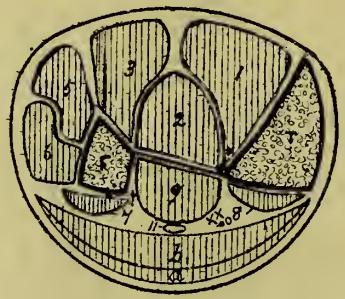

a.- Gastrocnemius.
b.- Soleus

The other references are the same in the two Diagrams

The attachments of these four Muscles taken together extend much nearer the Knee and Ankle on the outer than on the inner side of the Leg, thus :—

Origins

Soleus and **Flexor Longus Pollicis**	from the upper and lower half respectively of the outer part of the post. surf. of the Fibula.				
Tibialis Posticus,	— ,, ,, middle $\frac{4}{5}$ of the contiguous portions	,,	,,	surfaces of Fibula and Tibia.
Flexor Longus Digitorum,	— ,, ,, ,, $\frac{1}{3}$,, outer part	,,	,,	surface of the Tibia.

Soleus is also attached to the Head of the Fibula, to the Oblique Line on the Tibia, and to a fibrous arch between them.
Tibialis Posticus is attached ,, posterior surface of the Fibula internal to the Oblique Line, to the post. surface of the Tibia external to the Vertical Line, and to the Interosseous Membrane.

Flexor Longus Pollicis is attached to within **1** inch from the Ankle, the Tibialis Posticus to within **2** inches, and the Flexor Longus Digitorum to within **3** inches.

Insertions

Soleus, —by Tendo Achillis to lower half of posterior surface of Os Calcis.
The muscular portion of the Gastrocnemius ends in tendon a little below the middle of the Leg, that of the Soleus just above the Ankle.

Tibialis Posticus, —Tuberosity of Scaphoid, giving special offsets to all the Bones of the Tarsus and Metatarsus, except the extremes, viz., the Astragalus and the first and last Metatarsal Bones.

Flexor Longus Digitorum, —Last phalanges of four outer Toes, as in Hand, joining Flexor Accessorius and perforating Flexor Brevis.

Flexor Longus Pollicis, — ,, phalanx ,, Great Toe ,, ,, passing between Heads of Flexor Brevis Pollicis.

In its course the Tendon of the Flexor Longus Digitorum crosses that of the Tibialis Posticus behind the Internal Malleolus, and that of the Flexor Longus Pollicis in the Sole of the Foot, separated from the former by Synovial Membrane, but receiving from the latter a special slip.

The Tendons crossing behind the Ankle have the following relations to each other :—

In the Groove behind the Internal Malleolus lies the Tibialis Posticus with the Flexor Longus Digitorum superficial to it.

,, ,, ,, External ,, ,, Peroneus Brevis ,, ,, Peroneus Longus ,, ,,

,, ,, on Tibia midway betw. Malleoli ,, Flexor Longus Pollicis, grooving also the post. border of the Astragalus.

The tendons behind each Malleolus have a common Synovial Sheath, the middle tendon has a special Sheath.

For Diagrams of the attachment of Muscles to the Bones of the Leg, see pp. 38 and 39.

The Great Toe has two Extensors and two Flexors, a special Abductor and a special Adductor.
„ Little „ „ one Extensor „ three „ „ „ „ a Plantar Interosseous as „
„ other Toes have each two Extensors „ „ „ and two Interossei as Abductor and Adductor.

Ext. Brevis Digit.	*Origin*	Superior Surface of Great Process of Os Calcis Inferior border of Anterior Annular Ligament	*Insertion*	by four tendons with tendon of Extensor Proprius Pollicis and three *inner* tendons of Ext. Long. Digit.
Flexor Brevis Digitorum	„	*Inner* Tubercle of Os Calcis Fascia and Intermuscular Septa	„	by four tendons into 2nd Phalanges of four *outer* Toes like Flexor Sublimis Digitorum of Hand.
Flexor Accessorius Digit.	„	*Inner Head*, fleshy, from inner surface of Os Calcis *Outer* „ tendinous „ outer edge of Inf. surf. of „ „ „ and Long Plantar Ligament		—Tendon of Flex. Long. Digit., outer border.
Flexor Brevis Pollicis	„	Cuboid and External Cuneiform Bones Ligaments between them	„	* by two Heads into 1st Phalanx with Abductor and Adductor Pollicis.
Adductor Pollicis	„	Bases of 2nd, 3rd and 4th Metatarsal Bones Sheath of Peroneus Longus	„	—1st Phalanx, *inner* side of Base.
Abductor Pollicis	„	*Inner* Tubercle of Os Calcis Internal Annular Ligament and Fascia	„	— „ „ *outer* „ „ „

* The Heads contain Sesamoid Bones, and are separated by the Tendon of the Flexor Longus Pollicis.

Flexor Brevis Min. Digiti	„	Base of 5th Metatarsal Bone Sheath of Peroneus Longus	„	„ „ „ „ „
Abductor Min. Digiti	„	*Outer* and *Inner* Tubercles of Os Calcis Fascia and Intermuscular Septa	„	— „ „ „ „ „
Transversus Pedis	— „	Head of 5th Metatarsal Bone Transverse Metatarsal Ligament	„	„ „ of Great Toe, with Adductor Pollicis.

Of the three Muscles connected with the Tubercles of the Os Calcis, one the Abductor of the *Little* Toe, arises from *both* Tubercles, the others from the Inner Tubercle only.

Each of the above Muscles is connected at its origin partly with Bone, partly with Ligament or Fascia, and at its insertion (excluding the common Muscles of the Toes) with the Base of a 1st Phalanx. Notice the grouping in sets of three, each consisting of a pair and a single Muscle.

MUSCLES OF FOOT.- RELATIVE POSITIONS.

1.- Abductor Pollicis

2.- " Minimi Digiti.

3.- Flexor Brevis Pollicis.

4.- " " Minimi Digti

5.- Adductor Pollicis

6.- 3rd Plantar Interos. (Add Min Digti).

13.- Transversalis Pedis.

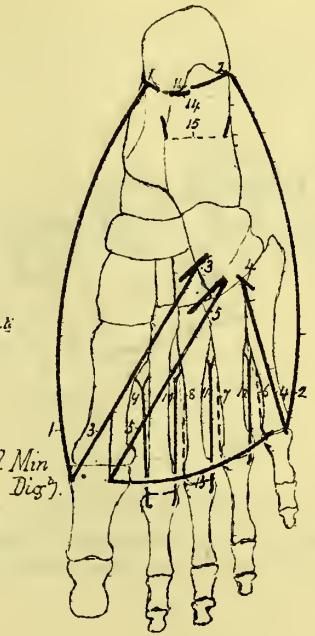

7.- 2nd Plantar Interosseous.

8.- 1st " "

9.- 1st Dorsal "

10.- 2nd " "

11.- 3rd " "

12 - 4th " "

14.- Flex Brev. & 15.- Flex. Access. Digit. [not represented.

SECTION OF FOOT.

1.- Abductor Pollicis
2.- " Min. Dig.
3.- Adductor Pollicis.
4.- 3rd Plant. Inteross.
5.- 2nd " "
6.- 1st " "
7.- 1st Dorsal "
8.- 2nd " "
9.- 3rd " "
10.- 4th " "

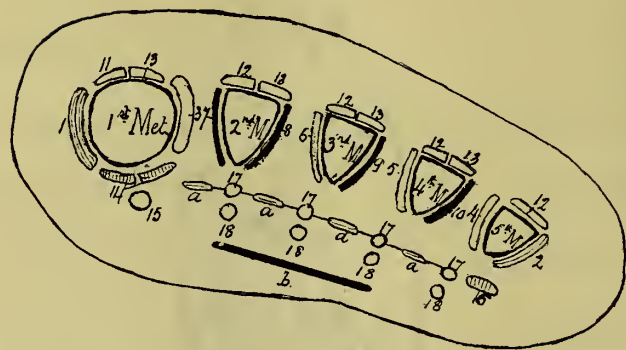

11.- Ext. Prop. Pollicis.
12.- " Longus Digit.
13.- " Brevis " .
14.- Flexor Brevis Pollicis
15.- " Longus " .
16 - " Brevis Min. Dig.
17.- " Longus Digit.
18.- " Brevis " .
a.- Lumbricales
b.- Plantar Fascia.

To indicate relative positions of Muscles on transverse section through Metatarsal Bones.

Lumbricales
- *four* in number { connecting the Tendons of the Flexor Longus Digitorum / with ,, ,, ,, Extensor ,, ,, } as in Hand.
- The innermost is attached to the inner border of the 1st Tendon.
- The other three are ,, ,, contiguous borders of the other Tendons.

Interossei
- *four* Dorsal **Abductors** from, and *three* Plantar **Adductors** to, the mid-line.
- *Origin* —as in the Hand { the Dorsal, one in each interspace, from the contiguous surfaces of the Metatarsal Bones. / ,, Plantar, each from the Metatarsal Bone of the Toe to which it belongs.
- *Insertion*
  - The Dorsal into the middle three Toes, two ending on the 2nd Toe.
    - The 1st and 2nd are connected with opposite sides of the base of the 1st Phalanx of 2nd Toe.
    - The 3rd ,, 4th ,, ,, ,, the outer ,, ,, bases ,, ,, Phalanges ,, 3rd & 4th Toes.
  - The Plantar into the outer three Toes (inner ,, ,, ,, ,, ,, ,, .)
- From the insertion of each Interosseous Muscle an offset is sent to each Extensor Tendon.

The Lumbricales and Plantar Interossei are more simple in arrangement in the Foot than in the Hand, thus :
In the Hand the two outer Lumbricales arise each from a single Tendon, in the Foot only the innermost (which cannot arise from two).
,, ,, ,, Palmar Interossei are inserted into the 2nd, 4th and 5th Fingers ,, ,, (Plantar Interossei) into the *outer* three Toes.
The Dorsal Interossei in the Foot are attached to the *middle* three Toes (as in the Hand).

Layers of Muscles, etc., in the Foot.

(1) Integuments and Plantar Fascia with Superficial Vessels and Nerves.

(2) Muscles
- Abductor Pollicis, on *inner* side.
- Abductor Minimi Digiti ,, *outer* ,,
- Flexor Brevis Digitorum, *intermediately.*

(3) Tendons, —Tendons of { Flexor Longus Digitorum / Flexor Longus Pollicis } with { Flexor Accessorius. / Lumbricales. }

(4) Muscles
- Flexor Brevis Pollicis.
- Flexor Brevis Minimi Digiti.
- Adductor Pollicis.
- Transversus Pedis.

(5) Bones and Ligaments, Interossei Muscles, and Tendons of Peroneus Longus and Tibialis Posticus.

For layers of Vessels and Nerves see 'Arteries of Foot.'

Temporal Fascia, attached as { a *single* layer to the Temporal Ridge bounding the Temporal Fossa.
two layers ,, inner and outer borders of the Zygomatic Arch.

{ Inferiorly, between the two layers are { an Orbital twig from the Temporal Artery (Anastomotic Br.).
a Temporal ,, ,, ,, Orbital Nerve (from Superior Maxillary).
The *superficial* surface of the Fascia is covered by the Epicranial Aponeurosis.
,, *deep* ,, ,, ,, attaches fibres of the Temporal Muscle, except below and in front.

Immediately above the Zygoma anteriorly there are *seven layers* overlying the Temporal Muscle.

1. Skin,
2. Superficial Fascia and Vessels,
3. Epicranial Aponeurosis,
4. Outer layer of Temporal Fascia,
5. Fatty tissue,
6. Inner Layer of Temporal Fascia,
7. Loose tissue over tendon of Temporal Muscle.

Deep Cervical Fascia.

From *behind forwards* {
is attached *posteriorly* to Spines of Vertebræ and Ligamentum Nuchæ,
splits into two layers to enclose Trapezius,
forms a single layer over the Posterior Triangle,
splits into two layers to enclose the Sterno-mastoid,
forms a single layer over the Anterior Triangle,
splits to enclose the Depressor Muscles of the Larynx,
blends *anteriorly* with the corresponding Fascia of the opposite side.

{ Connected *above* with { Zygoma *posteriorly*.
Body of Jaw *anteriorly*.
Angle of Jaw and Styloid Process *intermediately*, by a special layer forming Stylo-maxillary Ligament.

,, *below* ,, { Clavicle *externally*.
Anterior surface of Sternum *internally*.
Posterior ,, ,, ,, by a distinct layer, separated from that attached to front of Sternum by fat and a [gland.

,, *intermediately* ,, { Hyoid Bone.
Sheath of Carotid Vessels.

{ Gives *investments above* to { Parotid Gland (viz., Parotid Fascia).
Masseter Muscle (viz., Masseteric Fascia).

Forms *sheaths below* for { Subclavian Artery *externally*.
Great Vessels passing into Thorax *internally*.
{ The sheath of the Subclavian Artery is connected with the Fascia of the Arm.
,, ,, ,, Thoracic Vessels ,, ,, ,, the fibrous layer of the Pericardium.

{ Develops a special *band above* by which the Sterno-mastoid is held forward towards the Angle of the Jaw.
,, ,, ,, ,, *below* ,, ,, ,, Omo-hyoid ,, bound down to the 1st Rib.

Vertebral Aponeurosis (Sheath of Extensors of Back)
- blended
  - *below* with Aponeurosis of Erector Spinæ, Latissimus Dorsi and Serratus Posticus Inferior.
  - *above* ,, Deep Cervical Fascia, beneath Splenius (unconnected with Serratus Posterior Superior).
- attached
  - *internally* to Spinous Processes of Lumbar and Dorsal Vertebræ.
  - *externally* ,, Crest of Ilium / Fascia Lumborum and to Ribs. / Intercostal Fascia.

FASCIÆ OF UPPER EXTREMITY.

Costo-coracoid Membrane
- split
  - *below* to enclose Pectoralis Minor and to form sheath of Axillary Vessels on inner side,
  - *above* ,, ,, Subclavius ,, join Anterior and Posterior Borders of Clavicle.
- attached
  - *internally* to upper two Ribs and Intercostal Fascia.
  - *externally* ,, Coracoid Process ,, Fascia of Arm.
- transmitting
  - always
    - Acromio-thoracic *Artery.*
    - Cephalic *Vein.*
    - External Anterior Thoracic *Nerve.*
  - sometimes
    - Branch of Superior Thoracic *Artery.*
    - Acromio-thoracic *Vein.*
    - Branch of Internal Anterior Thoracic *Nerve.*

Ext. Intermuscular Septum — thin — attaching Brachialis Anticus *in front* and Biceps *behind* / Supinator Long. & Ext. Carpi Rad. Long. *laterally* — pierced by Superior Profunda Artery. / Musculo-spiral Nerve.

Int. Intermuscular Septum — strong — ,, —Brachialis Anticus *in front* and Biceps *behind* ,, ,, Inferior Profunda Artery. / Ulnar Nerve and / Post. branch of Anastomotic Art.

Fascia of Forearm.

Anteriorly —thick *above*, receiving fibres from Biceps and attaching Superficial Flexors, thinner *below*, joining Ant. Ann. Lig.
Posteriorly — ,, ,, ,, ,, ,, Triceps ,, ,, ,, Extensors ,, ,, ,, Post. ,, ,,

Anterior Annular Lig.—fibres pass *transversely* from Scaphoid and Trapezium *externally*, to Unciform and Pisiform *internally*.
Posterior Annular Lig.— ,, ,, *obliquely* ,, Radius *above*, downwards and inwards* to First Row of Carpal Bones *below*.

* In same direction as fibres of Anterior and Posterior Ligaments of Wrist Joint.

Palmar Fascia
- connected *above* with Palmaris Longus Tendon, and by deep surface with Ant. surface of Ant. Annular Lig.
- split *below* into four pieces, each subdivided near fingers into
  - processes passing to Skin.
  - ,, ,, ,, Sheaths of Tendons.

The *Common Synovial Membrane* beneath the *Anterior* Annular Ligament is distinct from the Membranes of the Sheaths of the Tendons, except in the case of the Thumb Tendon usually, and the Little Finger Tendon sometimes.

There is a *separate Synovial Membrane* within each of the six Compartments of the *Posterior* Annular Ligament.

Sheaths of Tendons
- strong and complete opposite shafts of 1st and 2nd Phalanges, thin and weak over corresponding Joints.
- containing
  - Synovial Membranes, *giving* slender vascular folds here and there to Tendons (Vincula Vasculosa).
  - Flexor Tendons, each at its insertion *giving* an offset to the head of the bone above that into which it is inserted (Ligamentum Breve).

FASCIÆ OF LOWER EXTREMITY.

Fascia Lata of Thigh
- attached
  - *above* to prominent points round Pelvis.
  - *below* ,, ,, ,, ,, Knee.
- perforated *in front and above* by Saphenous Opening (for which see "Femoral Hernia").
- thickened
  - *behind* ,, ,, over Gluteus Medius, giving origin to it, *forming* Gluteal Fascia.
  - *in front* ,, *below* ,, Quadriceps Tendon, blending with Apons. of Vasti ,, Retinacula of Patella.
  - *externally* by the insertion into it of Gluteus Max. and Tens. Vag. Fem. ,, Ilio-tibial Band.

- **Ext. Intermuscular Septum,** strong, separating Vastus Externus and Biceps (short Head).
- **Int. Intermuscular Septum,** thin ,, ,, Internus ,, Adductor Muscles.

Fascia of Leg
- *anteriorly,* strongest above, connected *above* with Tibia, etc.; continued *below* into Anterior Annular Lig.
- *posteriorly* ,, ,,
  - continuous ,, ,, Fascia of Thigh, and ,, with Internal ,, ,,
  - ,, *externally* ,, ,, on Front of Leg.
  - attached *internally* to Internal Margin of Tibia.

A deep layer of the Fascia on the back of the leg between the superficial and deep Muscles is strongest *below*.

Ant. Annular Lig. —in two parts
- the *superior*, a broad band between the Tibia and Fibula just above the Malleoli.
- ,, *inferior* ,, Y-shaped ,,
  - attached *externally* to upper surface of Os Calcis.
  - ,, *internally* ,, Int. Malleolus and Tuber. of Scaphoid.
  - attaching by lower edge the Extensor Brevis Digitorum.

The whole Ligament is thus Z-shaped (see Diagram).
The upper piece has *one* Synovial Membrane for the Tibialis Anticus, the other Muscles being uninvested.
,, lower ,, ,, *three* ,, Membranes ,, ,, ,, ,, Extensor Proprius Pollicis and
- Extensor Longus Digitorum.
- Peroneus Tertius.

Int. Annular Lig.
- attached *above* to Internal Malleolus and to Os Calcis (inner surface) *below*.
- continuous ,, with Fascia of Leg ,, attaching *below* the Abductor Pollicis Muscle.
- having separate Synovial Sheaths for Tibialis Posticus, Flexor Longus Digitorum and Flexor Longus Pollicis.
- covering the Posterior Tibial Vessels and Nerve in their passage to the Foot.
- pierced by branches of the Posterior Tibial Artery and Nerve (Cutaneous to Heel).

The Posterior Tibial Nerve divides opposite the upper border of the Ligament.
,, ,, ,, Artery ,, ,, ,, lower ,, ,, ,,
(Similarly the main Nerve of the back of the Leg, the Great Sciatic, divides higher up than the main Artery, the Popliteal.)

Ext. Annular Lig.
- attached to External Malleolus *above* and to Os Calcis (outer surface) *below*.
- having one Synovial Sheath for the Peronei, which subdivides to accompany each tendon.

Plantar Fascia
- consists of
  - *central* part, strong, triangular
    - attached *behind* to Tubercles on Inferior surface of Os Calcis.
    - subdivided *in front* for the Toes (like Palmar Fascia).
    - covering Flexor Brevis Digitorum.
  - *outer* ,, ,, band-like ,, Abd. Min. Dig., attached ant. to Base of 5th Met. Bone.
  - *inner* ,, thin and weak ,, ,, Pollicis.
- sends Intermuscular Septa on either side of Flexor Brevis Digitorum, which become united below it.

The **Sheaths** of the Tendons are like those of the Hand, but are not so distinct.

VESSELS.

Thoracic Aorta
- commences opposite the lower border of the joint between the 3rd Left Costal Cartilage and Sternum.
- ends at the Aortic opening of the Diaphragm,
- and is subdivided into the Arch and the Descending Aorta.

ARCH OF AORTA
- *Ascending Part*, runs from 3rd *Left* Cartilage, *lower* border to 2nd *Right* Cartilage (*upper* border).
- *Transverse* ,, ,, ,, 2nd Cartilage on *right* side ,, 2nd Dorsal Vertebra on its *left* side (or 3rd, or 4th).
- *Descending* ,, ,, ,, 2nd Dorsal Vertebra ,, 3rd ,, ,, (or 4th, or 5th).

Thus the Arch passes
- first from Cartilage to Cartilage, then from Cartilage to Vertebra, and then from Vertebra to Vertebra.
- ,, ,, 3rd to 2nd ,, ,, ,, 2nd ,, ,, 2nd ,, ,, ,, ,, 2nd to 3rd ,,

The Ascending part and the first portion of the Transverse are separated from the Sternum only by fat and remains of Thymus.
,, Descending ,, ,, last ,, ,, ,, ,, deeply placed in the Thorax under cover of the Left Lung.

Ascending Part
- Relations
  - *in front*, at origin, Right Auricular Appendage and Pulmonary Artery.
  - *behind* ,, ,, Left Auricle, and higher up Right Branch of Pulmonary Artery.
  - *to left side* Pulmonary Artery and Anterior Coronary Artery.
  - ,, *right* ,, Vena Cava Superior ,, Phrenic Nerve.
  - *invested* by the same reflection of Serous Pericardium as the Pulmonary Artery.
- Branches —The two Coronary Arteries.

Transverse Part
- Relations
  - *in front* (5)
    - Left Vagus Nerve and Left Phrenic Nerve, separated by
    - Sup. Card. of Left Symp. ,, Inf. Card. of Left Vagus (the roots of Super. Card. Plex.)
    - Left Superior Intercostal Vein.
  - *behind* (5)
    - Deep Cardiac Plexus and Left Recurrent Laryngeal Nerve.
    - Trachea ,, Œsophagus.
    - Thoracic Duct.
  - *along upper edge*, Left Innominate Vein.
  - ,, *lower* ,, ,, Branch of Pulmonary Artery.
  - *in concavity*, lies the Superficial Cardiac Plexus.
  - *through* ,, passes the Left Bronchus.
- Branches, etc.
  - arising from the *upper* margin are the
    - Innominate,
    - Left Carotid and Left Subclavian.
  - connected with the *lower* ,, is ,, Ductus Arteriosus (to left side).

Descending Part { Relations
- *behind,* —Vertebral column with Ligaments.
- *to left,* —Left Lung ,, Pleura.
- *to right,*—Œsophagus ,, Thoracic Duct.
- *in front,*—Root of Left Lung ,, Posterior Pulmonary Plexus.

DESCENDING AORTA.

Course, etc. { commences at left side and lower border of 3rd (or 4th or 5th) Dorsal Vertebra, and ends in mid-line at 12th Dorsal Vertebra.

Relations
- Lies *in* Posterior Mediastinum, *behind* Pericardium, resting *on* Vertebræ and Ligaments.
- Œsophagus is at first *to right* side, then *in front*, and lastly a little *to left* side.
- Vena Azygos Minor is *behind* in lower part.
- ,, ,, Major and Thoracic Duct are *to right* side.
- Left Lung and Pleura are *to left* side.

The **Branches of the Thoracic Aorta,** like the branches of the Abdominal Aorta or the Internal Iliac Artery may be arranged in *three Groups*, each consisting of *three* Vessels or sets of Vessels.

The *First Group* comprises three *single* Arteries, which supply *parts external* to the Thorax.
,, *Second* ,, ,, ,, *sets* of ,, ,, ,, the *walls* of ,, ,,
,, *Third* ,, ,, ,, ,, ,, ,, ,, ,, *viscera* ,, ,, ,,

FIRST GROUP.

Innominate
- *at origin* rests *on* Trachea to right side of mid-line, close to Left Common Carotid Artery.
- *next* passes *to right* of ,, ,, rest on the Longus Colli Muscle.

Left Common Carotid
- *at origin* rests *on* ,, to left side of mid-line, close to Innominate Art.
- *next* passes *to left* of ,, ,, rest on Œsophagus and Thoracic Duct.
- *lastly* ,, ,, ,, Œsophagus ,, ,, Longus Colli Muscle.

In front of both Vessels are { the Sternum and the Muscles attached to it, the remains of the Thymus Gland and the Left Innominate Vein.
Alongside ,, ,, lie the Cardiac Nerves.
On *outer side* of Innominate is the Right Innominate Vein separating it from the Phrenic Nerve.
,, ,, ,, Left Carotid ,, Left Pneumogastric Nerve ,, ,, ,, Left Subclavian Artery.
(The two Vessels would have similar relations if the Œsophagus did not lie somewhat to the left side of the Trachea at the top of the Thorax)

Left Subclavian
- *at first* rests *on* Œsophagus and Thoracic Duct, lying to left of Left Carotid Artery.
- *next* passes *to left* of ,, ,, ,, ,, to rest on Longus Colli Muscle.
- *in front* are the Left Innominate Vein and the Left Lung, the former crossing it, the latter overlapping it.
- *to the right* ,, ,, Pneumogastric ,, ,, Cardiac Nerves, separating it from the Left Carotid Art.
- ,, ,, *left* ,, ,, Lung and the Pleura.

Compare the Relations of the Innominate, Left Carotid and Left Subclavian as given above.

SECOND GROUP, —*three* sets of Vessels supplying the *walls* of the Thorax.

Intercostal, —10 pairs, one pair opposite each of the 10 lower Dorsal Vertebræ.

Course
- between Pleura and External Intercostal Muscle as far as Angles of Ribs.
- ,, Internal ,, ,, ,, Muscles ,, ,, Anterior $\frac{1}{3}$,, ,,

Branches, etc.
- Each gives off Posterior or Dorsal Branch between Transverse Processes of Vertebræ,
- divides opposite the Angles of the Ribs bounding the space into two parallel branches, which
- end near the Anterior Extremities of Ribs by joining corresponding Branches of the Internal Mammary.

In each Space the Artery lies between the Vein above and the Nerve below (except in the upper spaces where the Nerve is at first above the Artery). (See p. 118.)

Dorsal Branch
- passes back across inner edge of Anterior Costo-Transverse Ligament,
- gives off Spinal Branch opposite Intervertebral Foramen,
- ends in two offsets to Muscles and Skin of Back, which accompany corresponding Nerve.

Spinal Branch divides in Intervertebral Foramen into
- Branch to Bodies of Vertebræ.
- ,, ,, Spinal Cord.

Branch to Bodies ,, on their posterior Aspect ,,
- Ascending Twig } which join similar Vessels from above and below,
- Descending ,, } to form longitudinal Vessel on each side.

Branch to Cord ,, into
- offset on Anterior Nerve Root, which
  - joins its fellow of opposite side, and
  - assists in forming Anterior Spinal Artery.
- ,, ,, Posterior ,, ,, ,, divides into
  - Ascending Twig.
  - Descending ,,
  - assists in forming Posterior Spinal Artery of same side.

The same arrangement of Vessels in the Canal and on the Cord is found also in the Cervical and Lumbar Regions, where Spinal Branches are sent through the Intervertebral Foramina by the Vertebral, Ascending Cervical, and Superior Intercostal Arteries in the former case, and by the Lumbar, Ilio-Lumbar, and Lateral Sacral Arteries in the latter.

There are *three* longitudinal Arteries in relation with the Vertebræ, *one*, the Aorta, in front, and *two*, the Vertebral Twigs of the Spinal Arteries behind.
,, ,, ,, ,, ,, ,, ,, ,, ,, Spinal Cord ,, ,, Ant. Spinal ,, ,, ,, ,, Posterior Spinal behind.

Mediastinal (Posterior),—Small irregular offsets to Fat, etc., of Mediastinum.
Pericardiac, — ,, ,, ,, ,, Pericardium and Pleura.

N.B.—In the case of the three chief Vessels, etc., in the five following successive positions from above down, viz. :—(1) in an Intercostal Space, (2) in the Root of the Lung (right side), (3) in the Transverse Fissure of the Liver, (4) in the Root of the Kidney, and (5) in relation with the Internal Iliac Artery,—the Artery lies in each case between the other two, and the Vein alternates in position with the third structure, thus :—

From below upwards. From before backwards.

Intercostal Space.	Root of Right Lung.	Root of Liver.	Root of Kidney.	Relations of Int. Iliac.
Nerve	*Vein*	Duct (Hepatic)	*Vein*	Ureter
Artery	Artery	Artery (,,)	Artery	Artery (Int. Iliac)
Vein	Bronchus	*Vein* (Portal)	Ureter	*Vein* (,,)

THIRD GROUP, —*three* sets of Vessels supplying the *Viscera* of the Thorax.

Two, **Coronary**
- Right: arises from commencement of Arch of Aorta, appears to *right* of Pulmonary Artery, and curves round the *right* border of the Heart, lying in the groove between the *Right* Auricle and Ventricle, and giving off a branch toward the Apex in the *right* (or Posterior) Interventricular Sulcus.
- Left: takes a course similar to that of the Right, 'left' being substituted for 'right' and 'anterior' for 'posterior' in the above description.

Three, **Bronchial**
- *Two* passing to the Left Lung (the smaller Lung) and *one* to the Right Lung (the larger Lung). Arising directly from the Aorta from termination of Arch or from one of the Intercostal Arteries, lying on the deep aspect of the Bronchi and Root of Lung.

Four or *Five* **Œsophageal**
- small, oblique, arising from Descending Aorta, passing at once to Œsophagus.

INTERCOSTAL ARTERIES.

a.-Skin etc
b.-Trapezius.
c.-Longiss Dorsi etc.
d.-Ilio-costalis etc.
e.-Ext. Intercostal M.
f.-Int Intercostal M.
g.-Pectoralis Major.
h.-Pleura.
i.-Sternum.
k.-Rib.

1.-Aortic Intercost. Art.
2.-Dorsal Br. of do.
3.-Spinal Offset of do.
4. Lateral Br. of do.
5.-Terminal Brs. of do.

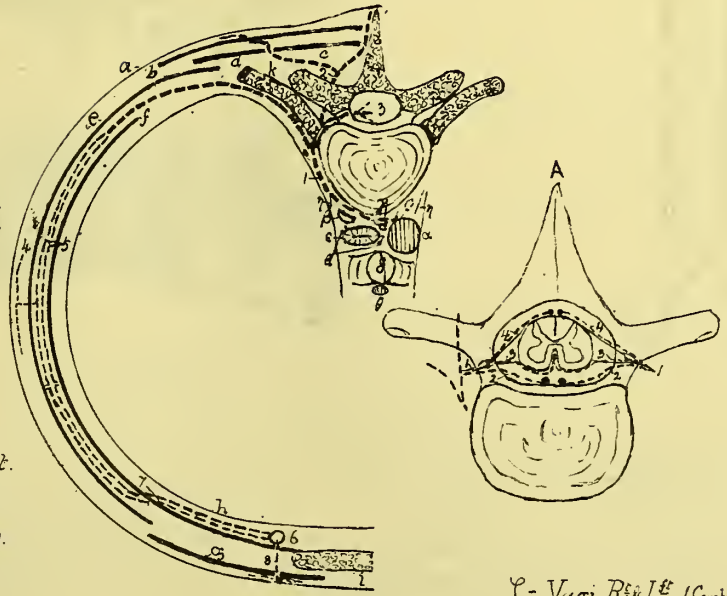

6.-Int Mammary Art.
7.-Intercostal Brs. of do.
8.-Perforating Br of do.

A:-DIAGRAM of Brs. of Spinal Offset.
1.-Spinal Offset.
2.-Br. to Post.r Vertebral Art. of same side.
3.-" Ant Spinal Art.
4.-" Post. " " of same side.

PARTS IN POST. MEDIASTINUM.

α.-Descending Aorta. (Artery).
β.-Vena Azygos Major. (Vein)
γ.-Thoracic Duct. (Lymph.s).
δ.-Trachea. (Resp. Syst).
ε.-Œsophagus. (Alim. ").
ζ.-Vagi, R.t & L.ft (Cerebro-spinal). θ.-Mediastinal Glands (Gland.s).
η.-Splanchnics (Sympathetic). Connective Tissue & Fat.

RELATIONS OF ABDOMINAL AORTA.

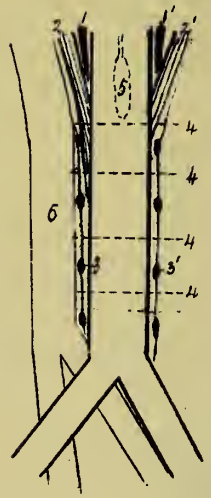

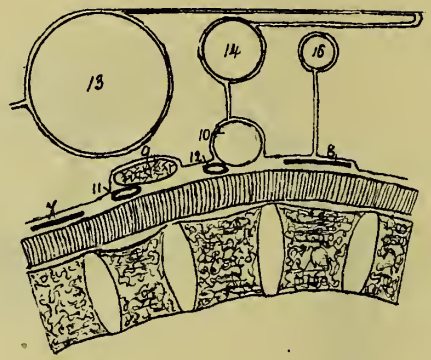

1.-1'-Azygos Veins, R^t & L^t.
2.-2'-Crura of Diaphragm, R^t & L^t
3.-3'-Sympathetic Cords, R^t & L^t
4.- Lumbar Veins-Left.
5.- Receptaculum Chyli.
6.- Vena Cava Inferior.
7.- Solar Plexus.
8.- Aortic "
9.- Pancreas.
10.- Duodenum.
11.- Splenic Vein.
12.- Left Renal ".
13.- Stomach.
14.- Transverse Colon.
15.- Small Intestine.

Course, etc.
- continuous *above* with Thoracic Aorta at Aortic opening in Diaphragm, lying in mid-line.
- bifurcates *below* into common Iliacs opposite 4th Lumbar Vertebra, lying a little to left of mid-line.

Relations.

- Lies *between*
  - in the upper half of its course
    - the right and left Crura of the Diaphragm.
    - ,, ,, ,, Azygos Veins (V. A. Major and V. A. Minor).
  - ,, lower ,, ,, ,, ,, ,, ,, Cords of the Sympathetic.
- ,, *upon*
  - Anterior Common Ligament of Vertebræ.
  - Receptaculum Chyli above.
  - Left Lumbar Veins (4) lower down.
- ,, *beneath*
  - Stomach
  - Transverse Colon
  - Small Intestine
  - } separated from them by folds of Peritoneum.
  - Solar Plexus, at commencement
  - Aortic ,, just before termination
  - Pancreas
  - * Splenic Vein
  - Duodenum (3rd part)
  - Left Renal Vein
  - } intermediately
  - } being immediately in relation with them.

* Two Plexuses, two Veins and two Viscera.

The Vena Cava Inferior lies to its right side below, but is separated from it above by the Right Crus of the Diaphragm.

Only one of the Veins opening into the Vena Cava Inferior crosses the Aorta (viz., Left Renal).
,, ,, ,, Branches of the Abdominal Aorta ,, ,, Vena Cava Inferior (viz., Right Spermatic).

The **Branches** of the Abdominal Aorta, like those of the Thoracic, may be arranged in *three Groups*, each consisting of *three* Vessels or sets of Vessels.

The *First Group* comprises three *single* Arteries which supply the *Alimentary* Viscera.
,, *Second* ,, ,, ,, *pairs* of ,, ,, ,, ,, *Non-alimentary* ,,
,, *Third* ,, ,, ,, *sets* ,, ,, ,, ,, ,, Abdominal *Parietes.*

FIRST GROUP.

Three single Vessels, arising from the front of the Aorta
- the Cœliac Axis ¼ inch below Diaphragm.
- ,, Sup. Mesenteric ½ ,, lower down.
- ,, Inf. ,, 2 inches above bifurcation.

Cœliac Axis, —appears at upper border of Pancreas, runs forward for ¼ inch, and divides into 3 branches :—

Gastric, —runs up & to the *left* on to Œsophagus, & curving on itself runs down, & to right along upper border of Stomach.

Hepatic
- Course, —passes to *right* along upper border of Pancreas, then curves upwards to enter Transverse Fissure of Liver.
- Branches
  - *Pyloric,* to *upper border* of Stomach, joins termination of Coronary Artery.
  - *Post. Pyloric* ,, posterior surface ,, *small end* of Stomach.
  - *Gastro-duodenal** ,, *lower border* of Stomach, and to Duodenum and Pancreas, joins branches of Splenic.
  - *Terminal Branches* (2) to Liver
    - Right, giving off Cystic Artery to Gall Bladder.
    - Left ,, ,, Spigelian ,, ,, Spigelian Lobe.

For the relative position of the Structures in the Transverse Fissure see 'Intercostal Arteries,' p. 118.

* Subdivided into Right Gastro-epiploic and Superior Pancreatico-duodenal.

Splenic
- Course, —runs directly to the *left* along the upper border of the Pancreas in a sinuous manner.
- Branches
  - *Vasa Brevia,* to the *large end* of the Stomach.
  - *Left Gastro-epiploic* ,, ,, *lower border* ,, ,,
  - *Pancreatic* (and Pancreatica Magna) ,, ,, left end ,, Pancreas.
  - *Terminal Branches* (4 or 5) ,, ,, Spleen.

Thus the Branches of the Hepatic correspond to those of the Gastric and Splenic together, except in the fact that the Branches of the Hepatic to the Pancreas and the lower border of the Stomach arise by a common trunk instead of as separate offsets.
See also 'Arteries of Stomach and Pancreas.'

Superior Mesenteric appears at the lower border of the Pancreas, runs down towards the Right Iliac Fossa, and gives off *six* Branches or sets of Branches (3 to Small Intestine and 3 to Large Intestine) as under :—

Branches
- To 3rd part of Duodenum and right end of Pancreas, —Inferior Pancreatico-duodenal.
- ,, Jejunum and Ileum, —Intestinal Branches (12 to 15).
- ,, lower end of ,, —Terminal Branch.
- ,, Ileo-cæcal valve and Cæcum, —Ileo-colic ,,
- ,, Ascending Colon, —Right Colic ,,
- ,, Transverse ,, —Middle ,, ,,

The Inferior Pancreatico-duodenal joins the Superior from the Hepatic.
,, Intestinal and Terminal Branches join with one another to form before distribution 4 or 5 series of Arches.
,, three Arteries to the Colon ,, ,, ,, ,, ,, ,, ,, ,, 1 ,, 2 ,, ,, ,,

BRANCHES OF AORTA.

THORACIC AORTA.

EXTRA-THOR. BRS.
1.- Innominate Art.
2.- Left Common Carotid.
3.- Left Subclavian Art.

PARIETAL BRS:
4.- Intercostal Arts.- R^t & L^ft.
5.- Mediastinal Brs.
6.- Pericardiac ".

VISCERAL BRS:
7.- Coronary.- R^t & L^ft
8.- Bronchial.- " ".
9.- Œsophageal.

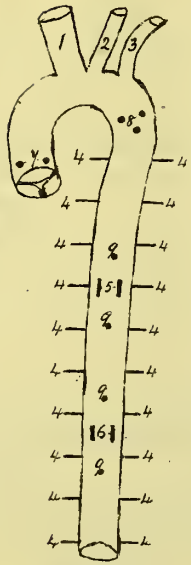

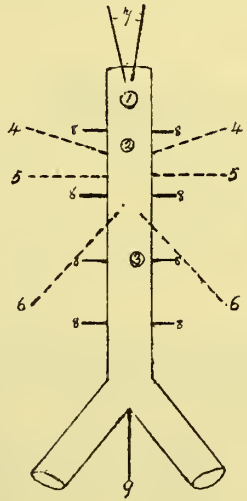

ABDOMINAL AORTA.

ALIMENT. BRS.
1.- Cœliac Axis.
2.- Sup. Mesenteric Art.
3.- Inf. " "

VISCERAL BRS
4.- Suprarenal Arts.- R^t & L^ft.
5.- Renal " "
6.- Spermatic " "

PARIETAL BRS.
7.- Diaphragmatic " "
8.- Lumbar " "
9.- Middle Sacral Art.

COELIAC AXIS.

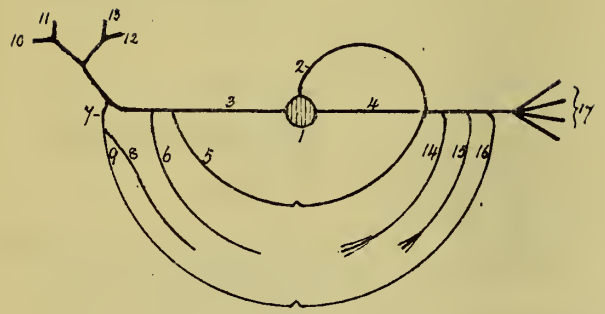

1.- Cœliac Axis.
2.- Coronary (Gastric) Art.
3.- Hepatic Art.
4.- Splenic " .
5.- Pyloric " .
6.- Post Pyloric Art.
7.- Gastro-duodenal Art.
8.- Pancreatico " "
9.- Rt. Gastro-epiploic Art.
10.- Cystic Art.
11.- Br to Rt. Lobe of Liver.
12.- " Left " " .
13.- " Spig'n " "
14.- Vasa Brevia.
15.- Pancreatic Brs.
16.- Left Gastro-epiploic Art.
17.- Term. Brs. of Splenic Art.

DIAPHRAGMATIC ARTS

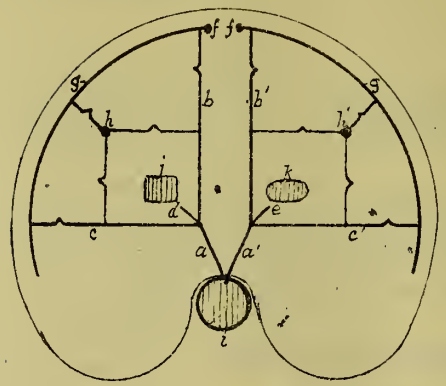

a & a'- Diaphragm. Arts. Rt. & Left.
b & b'- " " Art. Divs.
c & c'- " " Lat. " .
d- Br. to Vena Cava.
e.- " Œsophagus.
f.- Internal Mammary Arts.
g.- Musculo-phrenic Arts
h-h' Comes Nervi Phrenici Rt. & Lft.
i.- Aorta.
j.- Vena Cava Opening.
k.- Œsophageal

Inferior Mesenteric { passes downwards and a little to the left to enter the Pelvis, and gives off *three* Branches to the Large Intestine as under :—

Branches	To the Descending Colon,—the Left Colic	Branch.	
	,, ,, Sigmoid Flexure, — ,, Sigmoid	,,	(double or triple).
	,, ,, Rectum, — ,, Superior Hæmorrhoidal	,,	(double).

The Left Colic and Sigmoid Branches anastomose like the Colic Branches of the Superior Mesenteric.
,, Superior Hæmorrhoidal gives its two terminal branches to the sides of the Rectum.

{ Each of the Branches of the Abdominal Aorta above-named is accompanied by a corresponding Plexus of Sympathetic Nerves.
{ The Corresponding Veins (except the Hepatic) are directly or indirectly connected with the Portal Vein (see Veins).

SECOND GROUP.

Three pairs of Vessels arising from the sides of the Aorta, as under :—

Suprarenal, —Right and Left,—arise opposite Superior Mesenteric, and pass directly to the Suprarenal Capsules.

(The Suprarenal Capsule also receives twigs from the Diaphragmatic and Renal Arteries).

Renal, —Right and Left,—arise ½ an inch below the Superior Mesenteric, the Right lower than the Left.

Branches { 4 or 5 terminal branches to the Kidney.
{ a small branch upwards to the Suprarenal Capsule.
{ ,, ,, ,, downwards ,, Ureter.
{ a few twigs outwards ,, fat behind the Kidney.

Spermatic, Right and Left, { arise from the forepart of the Aorta ½ inch below the Renal,
pass obliquely downwards to the Psoas Muscle, the Right Artery crossing the Vena Cava Inferior,
cross the Ureter, rest on the External Iliac Artery, and enter the Spermatic Cord in the Internal Abdominal Ring,
become tortuous behind the Testis, supply it and join the Artery of the Vas Deferens.

or.

Ovarian, Right and Left { correspond to the Spermatic Arteries as far as the Margin of the Pelvis.
They then turn down and in, into Broad Ligament, become tortuous, and enter attached margins of Ovaries.
Each Artery gives twigs to the Fallopian Tube, to the Round Ligament, and to join the Uterine Artery.

The Right Artery thus crosses a Vein, an Artery and a Duct,—the Left an Artery and a Duct only.

{ Each of the above Arteries is accompanied by the corresponding Plexus of Sympathetic Nerves.
{ The Suprarenal and Renal Arteries have each a corresponding Vein; the Spermatic have each two Venæ Comites.

THIRD GROUP.

Three sets of Vessels, as under :—

Middle Sacral (single)
- arises from bifurcation of Aorta,
- passes vertically downwards along mid-line of Sacrum to Coccyx,
- gives twigs to Sacrum and Rectum, and joins the Lateral Sacral.

Diaphragmatic (two)
- arise separately or together from Abdominal Aorta at its commencement, or from Cœliac Axis,
- pass thence on Diaphragm, the Right towards the Vena Cava, the Left towards the Œsophagus,
- each dividing behind the corresponding tube into two terminal branches.

Terminal Branches of each
- include the corresponding Opening (for Vena Cava or Œsophagus) in the angle between them,
- and pass
  - one forwards to the Sternum to join Phrenic Branches of Internal Mammary.
  - ,, outwards ,, Ribs ,, ,, Musculo-phrenic ,, ,, ,, and Intercostals.

The Right Diaphragmatic supplies twigs to the Vena Cava, the Left to the Œsophagus.
Each gives offsets to the corresponding Suprarenal Capsule.

Lumbar (4 pairs)
- arise, one pair opposite each of the upper 4 Lumbar Vertebræ,
- pass under Psoas Muscle between points of attachment to Vertebræ,
- divide into Abdominal and Dorsal Branches.

Abdominal Branches
- pass out behind Quadratus and Transversalis,
- anastomosing with the other Arteries of the Abdominal Parietes.

Dorsal ,, resemble closely the corresponding branches of the Intercostal Arteries.

The Abdominal Branches are separated from the Abdominal Cavity chiefly by 3 successive Muscles, viz., the Psoas, Quadratus and Transversalis.

COMMON ILIAC ARTERIES.

Course
- from bifurcation of Aorta to Lumbo-sacral Joint, where each Vessel divides into Ext. and Int. Iliac Arts. of same side.
- indicated on the surface by a line drawn from left of Umbilicus towards middle of Poupart's Ligament.
- Both Vessels lie between the Vertebral Ligaments and the Peritoneum.

Relations

Right
- Right Common Iliac Vein crosses *behind* it below, and the Left behind it above.
- ,, Ureter and Right Root of Hypogastric Plexus cross *in front* of it.
- The Common Iliac Veins unite to form the Vena Cava Inferior on the right of the Artery at its commencement.

Left
- Left Common Iliac Vein lies *on its right* side.
- ,, Ureter, Left Root of Hypogastric Plexus and Superior Hæmorrhoidal Artery cross *in front of* it.

There are thus four Structures in relation with each Vessel :—
On the right side two cross in front and two behind.
,, ,, left ,, three ,, ,, ,, one lies on the right side (none being behind).

Course { runs from Lumbo-sacral Joint to upper border of Sacro-sciatic Foramen,
ends by subdividing into two trunks, Anterior and Posterior.

Relations, —*in front* the Ureter, *behind* the Internal Iliac Vein (separating it from the Lumbo-sacral Cord).

For other parts with analogous relations see 'Intercostal Arteries,' p. 118.

The **Branches**, like those of the Thoracic or Abdominal Aorta, may be arranged in *three Groups*, each consisting of *three* Vessels or sets of Vessels.

The *First Group* comprises three Arteries, which supply *parts external* to the Pelvis.
,, *Second* ,, ,, ,, ,, ,, ,, the *walls* of ,, ,,
,, *Third* ,, ,, ,, sets of ,, ,, ,, ,, *viscera* ,, ,, ,,

FIRST GROUP.

Three single Vessels { *two terminal* branches of the Anterior Division
one ,, branch ,, Posterior ,, } of the Internal Iliac.

Pudic
- leaves Pelvis through the Great Sacro-sciatic Foramen lying on Ischial Spine internal to Sciatic Artery, etc.
- re-enters ,, ,, ,, Small ,, ,, ,, below ,, ,, between accompanying Nerves.
- runs along outer wall of Ischio-rectal Fossa in aponeurotic Canal superficial to Pudic Nerve.
- enters between layers of Triangular Ligament, and piercing the anterior, divides into 2 terminal branches.

Relations
- lies first on Pyriformis and Sacral Plexus of Nerves, separated from them by Pyriformis Fascia.
- ,, next ,, Spine of Ischium between Pudic Nerve on inner and Nerve to Obturator Internus on outer side.
- ,, ,, ,, Obturator Internus Muscle ,, ,, ,, above ,, Perinæal Branch of Pudic Nerve below.

Branches, six (all primary)
- *two* in Ischio-rectal Fossa, —Inferior Hæmorrhoidal and Superficial Perineal.
- *two* ,, relation with Triangular Lig.,—Transverse Artery ,, Artery of Bulb.
- *two* terminal, —Dorsal Artery and Artery of Corpus Cavernosum.

Compare with the Branches of the Pudic Nerve.

Sciatic
- Passes out of Pelvis along with and on outer side of the Pudic Artery, having similar relations.
- ,, down between Tuber Ischii and Great Trochanter to end opposite lower border of Gluteus Maximus.

Branches
- one *upwards* to join Gluteal,
- ,, *forwards* (Anastomotic) towards upper border of Great Trochanter.
- ,, *backwards* (Coccygeal) through Great Sacro-sciatic Ligament to back of Coccyx.
- ,, *downwards* (Comes Nervi Ischiatici) to substance of Great Sciatic Nerve.

Small twigs are given to the Hip-joint, and to the Muscles and Skin behind it.

Gluteal, —Leaves Pelvis at upper border of Pyriformis, and divides at once into terminal branches.

Branches
- one *outwards* (Superficial Branch) to supply Gluteus Maximus.
- ,, *forwards* (Deep ,,) double to accompany the Superior Gluteal Nerve.
- ,, *downwards*, to communicate with the Sciatic Artery.
- ,, *backwards* (Sacral) over Sacrum, to communicate with the Coccygeal Branch of the Sciatic.

The Deep Branch supplies offsets to the Hip-joint.

SECOND GROUP
- *One* single Vessel and *one* pair of Vessels from Posterior Division
- *One* ,, ,, ,, Anterior ,,

} of Internal Iliac.

Ilio-lumbar, —passes beneath Psoas to margin of Iliac Fossa, and divides into Lumbar and Iliac Divisions.

Branches
- Lumbar Division { passes *upwards* and turns *outwards* opposite the last Lumbar Vertebra, beneath the Quadratus, and gives branches like a Lumbar Artery.
- Iliac ,, passes directly *outwards* and gives branches to Iliacus Muscle and Ilium.

Lateral Sacral
- the *upper* Vessel (the larger) ends over the upper part of the Sacrum.
- the *lower* ,, ,, ,, lower ,, ,, ,,

Both Vessels
- descend obliquely, supplying the subjacent structures, and
- give Dorsal offsets through the Sacral Foramina to the Spinal Cord and Back of Sacrum.

Obturator
- passes directly forward to Obturator Groove at upper and outer part of Obturator Foramen.
- lies in Sub-peritoneal tissue below Obturator Nerve, and
- divides beneath Obturator Externus Muscle into two terminal branches.

Branches
- *Within* Pelvis { offsets to Iliacus Muscle and Ilium, joining Branches of Ilio-lumbar.
  - ,, ,, Pubes and Bladder (Pubic) ,, ,, ,, Epigastric.
- *External to* ,, { External Terminal Branch, winding ext. round Obturator For., supplying muscles and Hip-joint
  - Internal ,, ,, ,, int. ,, ,, ,, ,, ,, only

} joining below Foramen

THIRD GROUP, —*One single, one double* and *one triple* Vessel from the Anterior Division of the Internal Iliac.

Middle Hæmorrhoidal,—passes direct to Rectum (often from Inferior Vesical).

- **Uterine** { enters Uterus at Neck and passes upwards tortuously,
  - gives twigs to Bladder and Ureter, and joins offset from Ovarian.
- **Vaginal** supplies Vagina, and gives twigs to contiguous parts of Bladder and Rectum.

- **Superior Vesical**—(lower part of obliterated Hypogastric Artery) supplies summit of Bladder.
- **Middle** ,, —(given off from Superior Vesical) supplies sides of Bladder, Vas Deferens and Ureter (lower end).
- **Inferior** ,, —generally arising separately ,, Base ,, ,, Prostate and Vesiculæ Seminales.

RELATIONS OF COMMON ILIAC ARTS.

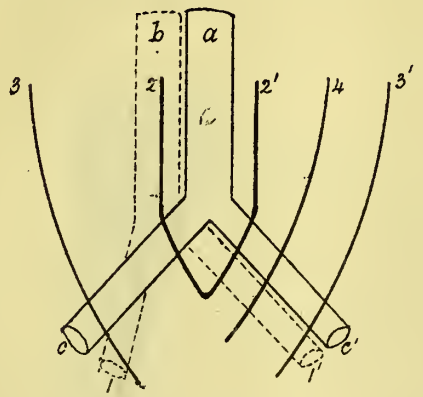

a.- Aorta
b.- Vena Cava Inferior.
c & c'- Common Iliac Arts. Rt. & Lft.

1 & 1'- Common Iliac Veins Rt. & Lft.
2 & 2'- Roots of Hypogastric Plex.
3 & 3'- Ureters Rt. & Left.
4.- Sup. Hemorrhoidal Art.

BRANCHES OF INT. PUDIC ART. AND PUDIC NV.

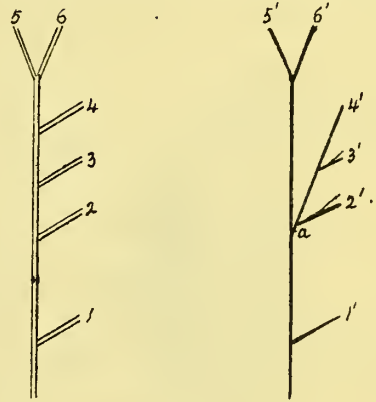

INT. PUDIC ARTERY.

1. Inf. Hemorrhoidal Art.
2.- Superficial Perineal "
3.- Transverse "
4.- Artery of Bulb.
5.- Art. to Corpus Cavernosum.
6.- Dorsal Art. of Penis.

PUDIC NERVE.

1'.- Inf. Hemorrhoidal Nerve.
a.- Perineal Division.
2'.- Superficial Perineal.
3'.- Muscular (Deep. ").
4'.- Br to Corp. Spong.m (Bulb).
5'.- " " " Cavernosum.
6'.- Dorsal Nerve of Penis.

RELATIONS OF FEMORAL ARTERY.

A.

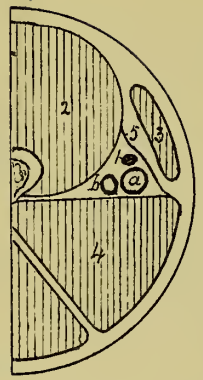

B.

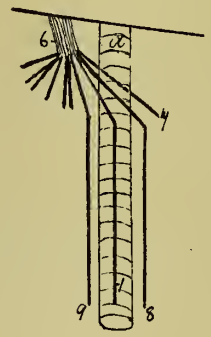

C.

A.- Relative position of Art. in its lower $\frac{2}{3}$rds
B.- Relation of Artery to Nerves.
C.- " " " " Vessels.
a- Femoral Artery.
b.- " Vein.
c.- Profunda Artery.
1.- Internal Saphenous N.
2.- Quadriceps Extensor.
3.- Sartorius.
4.- Adductor Muscles.
5.- Fascia of Hunter's Canal.
6.- Ant. Crural Nerve.
7.- Nerve to Pectineus.
8.- Int. Cutaneous Nerve.
9.- Nerve to Vastus Internus.
10.- Iliacus
11.- Psoas Magnus.
12 -Pectineus.

FEMORAL ARTERY.

Course, etc.

- Enters Thigh beneath *mid-point* of Poupart's Ligament, resting on the Psoas, the *middle* Muscle of Scarpa's Triangle.
- Lies at first *superficially* beneath Integuments in Scarpa's Triangle, then *deeply* beneath Sartorius in Hunter's Canal.
- Is enclosed at first in *Crural Sheath* in Scarpa's Triangle, then is covered by *fibrous reflection* in Hunter's Canal.
- Becomes continuous below with Popliteal Artery at opening in Adductor Magnus Muscle.

Relation to *Vessels, Nerves,*

- The Profunda *Artery* is at first to its *outer* side, and next (at Apex of Triangle) *beneath* it, separated by Fem. & Prof. Veins.
- ,, Femoral *Vein* ,, ,, ,, *inner* ,, ,, ,, ,, ,, ,, ,, and lastly (in Hunter's Canal) to [its *outer* side.
- ,, Ant. Crural *Nerve* ,, ,, ½ in. ,, *outer* ,, and gives branches round it, thus :—

Nerve to Pectineus	crosses	*beneath*	the Artery	*transversely above.*	
Int. Saphenous Nerve	lies	*over*	,, ,,		
Nerve to Vastus Internus	,,	to *outer* side of	,, ,,	*longitudinally below.*	
Int. Cutaneous N. (post. div.)	,,	,, *inner* ,, ,, ,,	,,		

- The Obturator Nerve gives a branch to supply the Artery from its Superficial Division.

and *Muscles*

As compared with the Profunda Femoris its relations are as follows :—

- The Femoral rests successively on the Psoas, Pectineus, Adductor Brevis and Adductor Longus.
- The Profunda ,, ,, ,, Iliacus ,, ,, ,, ,, ,, Magnus.

The Femoral is separated from the Adductor Brevis by a little fat, and it may rest on the Adductor Magnus at its termination ; the lowermost fibres of the Adductor Longus, however, are often blended with those of the Adductor Magnus.

Near the **Base of Scarpa's Triangle** the chief structures lie side by side from *without inwards* as follows :

Iliacus supporting Profunda Artery.	Anterior Crural Nerve.	Psoas supporting Femoral Artery.	Femoral Vein	Pectineus supporting Crural Canal (*i.e.*, inner side of Crural Sheath).

At the **Apex of Scarpa's Triangle** the chief structures lie superposed from *before backwards* in the following order :—

Femoral Artery, —— Femoral Vein, —— Profunda Vein, —— Profunda Artery.

At the **upper part of Hunter's Canal** the chief structures are from *before backwards* in the following order :—

Sartorius— { Femoral Artery and Vein / Internal Saphenous Nerve } —Adductor Longus— { Profunda Artery and Vein / Deep Branch of Obturator Nerve } —Adductor Magnus.

In the last-named situation the Femoral Artery lies in a position as regards the Muscles similar to that of the Carotid in the Neck *i.e.*, in the Angle between two sets of Muscles covered by a third Muscle (see Diagram).

There are *five* named **Branches of the Femoral Artery,** *three* arising close together, and *two* at a distance apart.

,, ,, ,, ,, ,, Profunda ,, *two* ,, ,, ,, ,, *three* ,, ,, ,,

A *sixth* set of unnamed Muscular Branches also arises from each Vessel.

Superficial Ext. Pudic, Superficial Epigastric and **Superficial Circumflex Iliac,** the *three* contiguous Branches of the Femoral, are all superficial, radiating from the upper part of the Femoral Artery to supply the Integuments of the lower part of the Abdomen and Groin.

The **Profunda,** the *fourth* branch, arises from the Femoral 1½ in. below Poupart's Ligament (see above).

The **Anastomotica Magna** ,, *fifth* ,, ,, ,, ,, at the Opening in the Adductor Magnus, and divides into three Branches:
- one running down to *inner* side of Knee *superficially*, accompanying the Internal Saphenous Nerve.
- ,, ,, ,, ,, ,, ,, ,, *deeply*, accompanying branch to Knee from Nerve to Vastus Internus.
- ,, lying along tendon of Adductor Magnus in substance of Vastus Internus.
- ,, crossing *transversely above* the Knee to join Superior External Articular Artery beneath Quadriceps Extensor.

The **Muscular** Branches have no definite arrangement.

The *two* contiguous **Branches of the Profunda** arise near its origin, and are distributed as follows :—

External Circumflex
- passes *outwards* beneath the Sartorius and Rectus,
- and supplies, by Ascending, Transverse and Descending Branches, the whole of the outer side of the Thigh.

Internal Circumflex
- passes *backwards* between Psoas and Pectineus, then between Adductor Brevis and Obturator Externus, & appears at back between Adductor Magnus & Quadratus Femoris.
- and supplies the Adductor Muscles and Hip-joint, giving a special branch to the Great Trochanter which appears above the Quadratus.

The **Sup. Middle** and **Inf. Perforating*** (the other *three* named Branches of the Profunda) arise at intervals from the Profunda, the Middle supplying a branch to the Femur.

,, **Muscular*** Branches of the Profunda (five in number) pierce the Adductor Magnus a little internal to the Perforating.

* For termination see p. 128.

POPLITEAL ARTERY.

Course
- *Obliquely* downwards and outwards in *upper* part of Popliteal Space.
- *Vertically* downwards „ *lower* „ „ „

Relation to *Muscles*, etc.,
- *Beneath* it successively are
  - in *upper* third, the lower end of Femur (*Bone*).
  - „ *middle* „ „ Posterior *Ligament* of Knee.
  - „ *lower* „ „ Popliteus *Muscle*.
- *Covering* „ „ „
  - „ *upper* „ „ Hamstring *Muscles* { Semimembranosus. Semitendinosus.
  - „ *middle* „ „ *Integuments*.
  - „ *lower* „ „ *Muscles* of Calf { Gastrocnemius. Plantaris.

and *Vessels* and *Nerves*
- The Popliteal Vein and Int. Popliteal Nerve lie
  - „ *upper* „ to *outer side* of the Artery.
  - „ *middle* „ directly *over* „ „
  - „ *lower* „ to *inner side* of „ „
- The Deep Division of the Obturator Nerve sends its terminal branch on to the Popliteal Artery, supplying it.
- (The Superficial „ „ „ „ „ „ „ „ Femoral „ „ „)

There are *five* named **Branches** of the Artery, and a *sixth* set of unnamed Muscular Branches (as in the case of the Femoral and Profunda Arteries).

- **Superior External Articular** passes *outwards above* Outer Condyle of Femur, *beneath* Biceps Tendon, to end in Vastus Externus.
- **Superior Internal Articular** „ *inwards* „ Inner „ „ „ „ Adduc. Magnus „ „ „ „ Internus.
- **Inferior External Articular** „ *outwards* „ Head of Fibula „ Ext. Lateral Lig. „ beneath Lig. Patellæ.
- **Inferior Internal Articular** „ *inwards below* Inner Tuberosity of Tibia „ Int. „ „ „ „ „ „
- **Middle** or **Azygos Articular** pierces the Posterior Ligament to supply the internal structures of the Joint.

Muscular Branches supply the Muscles bounding the Space above and below (the lower set being named Sural).

ANASTOMOSES ROUND THE HIP-JOINT.

In front.

Internally	The **Deep Epigastric**	(of *Ext.* Iliac)	communicates	with the	Obturator	(of *Int.* Iliac)	by its Pubic	Branches.
	,, **Obturator**	(,, *Int.* ,,)	,,	,,	,, Int. Circumflex	(of Deep Fem.)	,, ,, Terminal	,,
Externally	,, **Deep Circumflex Iliac***	(,, *Ext.* ,,)	,,	,,	,, Gluteal	(,, Int. Iliac)	over Crest	of Ilium.
	,, **Gluteal**	(,, *Int.* ,,)	,,	,,	,, Ext. Circumflex	(,, Deep Fem.)	,, Ant. Border	,, ,,

* The Deep Circumflex Iliac also joins directly some of the Ascending branches of the External Circumflex.
In this Anastomosis branches of the Internal and External Iliac and Profunda Femoris are associated.

Behind (and at back of Thigh).

The **Deep Circumflex Iliac** and the **Ilio-lumbar** form an arterial arch *along* the Crest of the Ilium.

,, Deep Circumflex Iliac	communicates	*in front*	with the	Ascending Branches of the External Circumflex.
,, Ilio-lumbar	,,	*behind*	,, ,,	Dorsal Branches of the Lateral Sacral by its Lumbar Division.
Each Vessel	,,	*below*	,, ,,	Gluteal.
,, **Gluteal**	,,	*in front*	,, ,,	Ascending Branches of the External Circumflex.
		behind	,, ,,	Dorsal Branches of the Lateral Sacral by its Sacral Branch.
		below	,, ,,	Sciatic.
,, **Sciatic**	,,	*externally*	,, ,,	Ascending Branches of Ext. Circumflex by its Anastomotic Branch.
		internally	,, ,,	Sacral Branch of Gluteal by its Coccygeal Branch.
		inferiorly	,, ,,	Internal Circumflex.*
,, **Internal Circumflex**	,,	*externally*	,, ,,	Ascending Branches of Ext. Circumflex above Great Trochanter. Transverse ,, ,, ,, below ,, ,,
		internally	,, ,,	External Branch of the Obturator.
		inferiorly	,, ,,	1st Perforating Branch of the Profunda.
,, three **Perforating** Branches & ,, Terminal Branch of Profunda	,,	*above & below*	,, one	another.
		externally	,, the	Descending Branches of the External Circumflex.
		internally	,, ,,	corresponding Muscular Branches of the Profunda.
,, Sup. Branches of **Popliteal Art.**	,,	*externally*	,, ,,	lowest Descending Branches of the External Circumflex.
		internally	,, ,,	Branches of the Anastomotica Magna.
		above	,, ,,	terminal Branch of the Profunda.

* The Sciatic joins also the External Terminal Branch of the Obturator.

There are thus three parallel and longitudinal sets of Arteries on the Back of the Thigh, one central and two lateral, anastomosing longitudinally and transversely. The External Circumflex supplies the whole of the outer side of the Thigh.

The **Hip-joint** is supplied by *four* Arteries { *above* by the Gluteal; *below* ,, Int. Circumflex } { *in front* by the Obturator; *behind* ,, Sciatic.

ANASTOMOSES AROUND HIP.

IN FRONT.

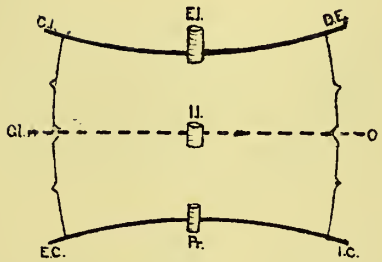

E.I.- *Ext. Iliac. Artery.*
I.I.- *Int. " " .*
Pr.- *Profunda Femoris.*
D.E.- *Deep Epigastric.*
C.I. - " *Circumflex Iliac.*
O. - *Obturator.*
Gl. - *Gluteal.*
I.C.- *Int. Circumflex.*
E.C.- *Ext. " .*

I.L.- *Ilio-lumbar Artery.*
L.S.- *Lateral Sacral " .*
M. - *Muscular Brs. of Profunda.*
1st P. - 2nd P. - 3rd P. - *Perforating Arteries.*
4th P. - *Terminal Br. of Profunda.*
A. - *Anastomotica Magna.*
Pop.M.- *Supt Muscular of Popliteal.*
1.- *Ascending.* 2.- *Transverse &*
3.- *Descending Brs. of Ext. Circumflex.*

AT BACK.

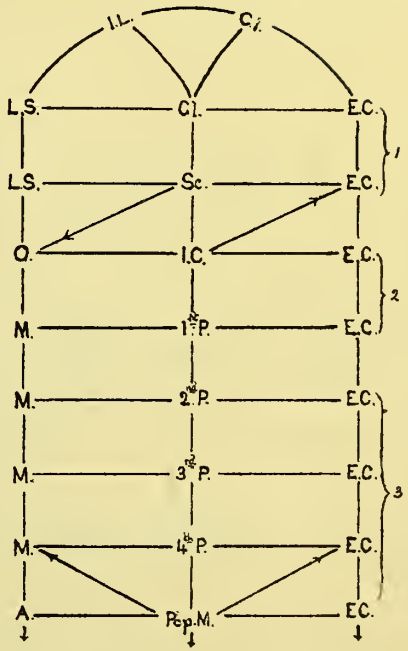

ANASTOMOSIS AROUND KNEE.

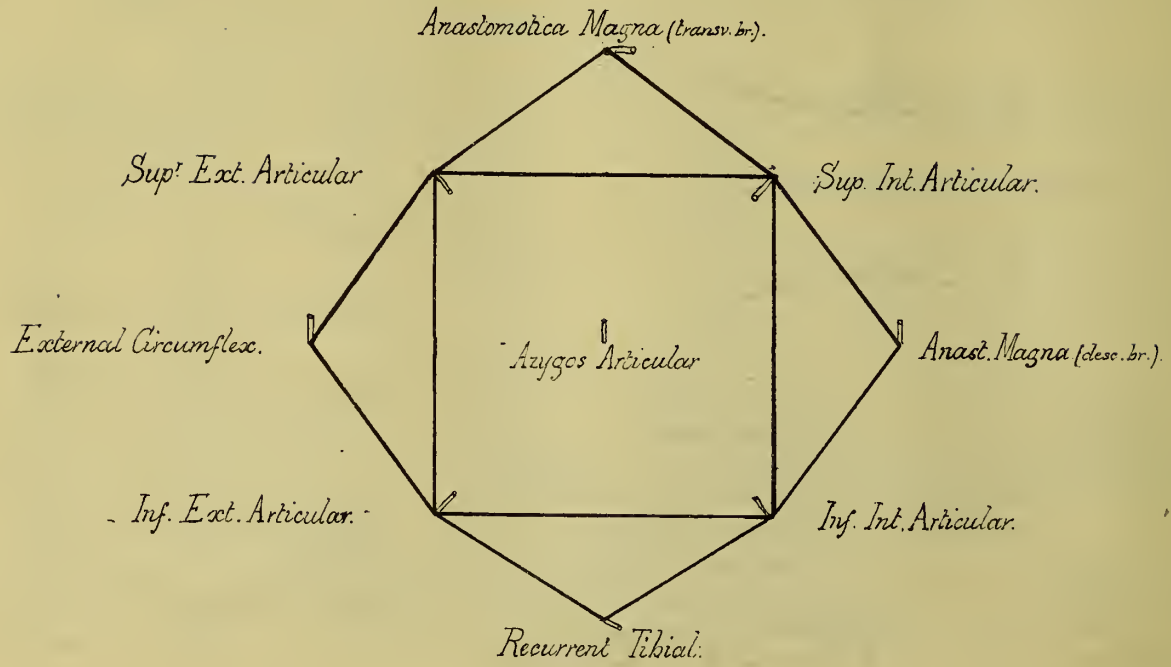

ANASTOMOSES ROUND THE KNEE-JOINT.

The Arteries which anastomose round the Knee-joint also supply it, thus :—

- The *two* **Ext. Articular** Branches of the Popliteal ramify one at the *upper*, the other at the *lower* parts of the Joint *externally*.
- ,, *two* **Int. Articular** ,, ,, ,, ,, ,, ,, ,, ,, ,, ,, ,, ,, *internally*.
- ,, **Middle** or **Azygos** Branch ,, ,, enters the Joint at the Back *centrally*.

- The **External Circumflex** (by Descending Branches) supplies the *outer* side of the Joint and joins the External Articular Arteries.
- ,, **Anastomotica Magna** { (by Descending Branch) ,, ,, *inner* ,, ,, ,, ,, ,, ,, Internal ,, ,, (,, Transverse Branch) communicates at the *upper* part of the Joint with the Sup. Ext. Artic. Art.
- ,, **Recurrent Tibial** ,, ,, *lower* ,, ,, ,, ,, Inf. Artic. Arts.

ANTERIOR and POSTERIOR TIBIAL ARTERIES.

Course
- Anterior Tibial,—from inner side of Head of Fibula to mid-point between Malleoli.
- Posterior Tibial,— ,, ,, ,, ,, ,, ,, ,, ,, Internal Malleolus and Os Calcis.
- Anterior Tibial,—is continuous with the Dorsal Artery of the Foot under the Anterior Annular Ligament.
- Posterior Tibial,—divides into the Plantar Arteries at the *lower** border of ,, Internal ,, ,,

Relation to *Muscles*, etc.
- Anterior Tibial in its upper two-thirds lies *deeply* on the Interosseous Membrane & in its lower third lies on the Tibia *superf.*
- Posterior Tibial ,, ,, ,, ,, ,, between Superf. & Deep Muscles ,, lowest part ,, ,, ,, ,,
- Anterior Tibial lies { between Tibialis Anticus and Ext. Long. Digitorum for an inch or two at first, then
  - ,, ,, ,, ,, ,, Prop. Pollicis ,, the greater part of its course, and lastly
  - ,, Ext. Long. Digit. ,, ,, ,, ,, (tendons) ,, an inch or two at the lower end.
- Posterior Tibial ,, { on Tibialis Posticus first, then on Flex. Long. Digit., and lastly on Tibia for an inch or two.
  - beneath Gastroc. & Soleus first, ,, beneath Integuments to inner side of Tendo Achillis.

and *Nerves* —The Anterior and Posterior Tibial Nerves lie to the *outer* side of the corresponding Arteries.

* The Posterior Tibial Nerve divides at the *upper* border of the Internal Lateral Ligament, just as the main nerve to the back of the Limb (the Sciatic) divides higher than the main Artery (the Popliteal).

Branches of Anterior Tibial.

- **Recurrent** to Knee-joint, *above*, piercing the fibres of the Tibialis Anticus.
- **Malleolar** (**Ext.** and **Int.**) to Ankle, *below*, running transversely and joining Arteries on corresponding sides of Foot.
- **Muscular** and **Cutaneous** twigs, *intermediately*, the largest accompanying the Musculo-cutaneous Nerve.

Branches of Posterior Tibial.

- **Muscular**, to Muscles on inner side and
- **Nutrient** (largest in the Body), to Tibia.
- **Communicating** with Peroneal, two inches above the Ankle.
- **Cutaneous** to Skin of lower half of back of Leg.
- **Articular** twigs to Ankle-joint.
- **Peroneal**, (collateral,) to outer side of back of Leg (see p. 130).

Peroneal, arising $1\frac{1}{2}$ in. below origin of Posterior Tibial, and ending behind External Malleolus.

Relations { Lies first on Tibialis Posticus, then in substance of Flexor Longus Pollicis, and lastly on Tibia above Ankle.
,, ,, beneath Gastrocnemius and Soleus ,, ,, ,, ,, ,, ,, ,, ,, beneath Integuments.

Branches { *Muscular* to Muscles on outer side of Leg.
Nutrient ,, Fibula. *Communicating* to Posterior Tibial two inches above Ankle.
Anterior Peroneal, passing through Interosseous Membrane below, to front of External Malleolus.

Compare with the Posterior Tibial Artery.

DORSAL ARTERY OF THE FOOT.

Course, etc. { continuous with Anterior Tibial Artery *above*, entering Sole of Foot through first Interosseous Space *below*.
resting on *inner* Bones of Tarsus, crossed by *inner* tendon of Extensor Brevis Digitorum.

The **Branches** must be distinguished from those of the Radial and Carpal on the back of the Hand.
The **Tarsal** Branch is not represented in the case of the Hand.
,, **Metatarsal** ,, resembles the Posterior Carpal Arch, but gives off three Dorsal Interosseous Branches instead of two.
,, 3rd and 4th Dorsal Interosseous resemble ,, the two Dorsal Interosseous Branches of the Posterior Carpal Arch.
,, 2nd ,, ,, resembles ,, Metacarpal Branch of the Radial Artery.
,, **1st Dorsal Interosseous** resembles ,, Dorsalis Pollicis together with the Dorsalis Indicis.
,, **Plantar Branch** supplies the inner side of the Great Toe; the **2nd Plantar** supplies the contiguous sides of the Great and 2nd Toes;—as distinguished from the Radial, which gives off the Princeps Pollicis to both sides of the Thumb, and the Radialis Indicis to the radial side of Second Finger.

PLANTAR ARTERIES.

The **Internal**, *small*,—ends on inner side of Great Toe, & curves out beneath Fascia to give branches to join Digital Arts. of $3\frac{1}{2}$ inner Toes.

,, **External**, *large* { passes { first *outwards* and forwards between Flexor Brevis Digit. and Accessorius towards base of 5th Metatarsal Bone, then *inwards* obliquely beneath Flexor Tendons on bases of Metatarsal Bones.
supplies 4 Digital Branches to $3\frac{1}{2}$ outer Toes, joining Dorsal Artery of Foot in 1st Interosseous Space.

Each Artery gives off Muscular Branches, similar to those of the corresponding Nerve.

Perforating Arts. (Ant. & Post.) { On Dorsum,—both sets are connected with the Dorsal Interosseous Arteries.
In Sole, —the Posterior joins the Plantar Arch; the Anterior, the Plantar Digital Arteries.

In the Foot, —The *External Artery* supplies $3\frac{1}{2}$ *outer* Toes, The *External Nerve* $1\frac{1}{2}$.—The Dorsal Artery $1\frac{1}{2}$ *inner*, The *Internal* Nerve $3\frac{1}{2}$.
,, ,, **Hand**,— ,, *Int.* (Ulnar) ,, ,, ,, *inner* Fingers, ,, *Int.* (Ulnar) ,, ,, — ,, Radial (*Ext.*) ,, ,, *outer*, ,, Median (*Ext.*) ,, ,,

LAYERS IN SOLE. (1) *Integuments* and Fascia.
(2) Terminal part of Int. Plantar *Artery* (see above).
(3) Superficial *Muscles*.
(4) Main Trunks of Ext. Plantar *Artery and Nerve*.
(5) *Tendons* of Flexors with Accessorius.
(6) Plantar Arch of *Arteries*, etc.
(7) *Bones* and Interosseous Muscles.

DORSAL ARTERIES OF FOOT AND HAND.

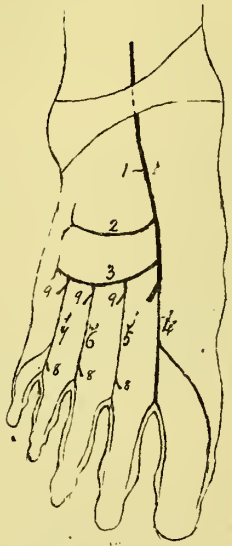

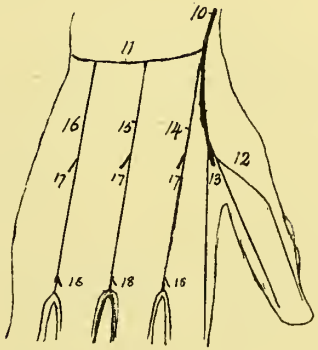

1.- Dorsal Artery of Foot.
2.- Tarsal " "
3.- Metatarsal " "
4.- Dorsalis Hallucis Art. or 1st Dors. Inteross.
5.- 2nd Dorsal Inteross. Art.
6.- 3rd " " "
7.- 4th " " "
8 & 9.- Ant. & Post. Perforating Arts.
10.- Radial Artery.
11.- Post. Carpal Arch.
12.- Dorsalis Pollicis Art.
13.- " Indicis " "
14.- Metacarpal Art. (1st Dors. Int.).
15.- 2nd Dorsal Inteross. Art.
16.- 3rd " " "
17 & 18.- Sup. & Inf. Perfor. Arts.

The **Subclavian** supplies the lower and posterior parts of the Neck; the **External Carotid** the upper and anterior. The **Common Carotid** and **Internal Carotid** Arteries give no branches in the Neck.

SUBCLAVIAN ARTERY
- commences its course in the Neck at the *upper border* of the Sterno-clavicular Articulation.
- terminates „ „ *lower border* „ „ 1st Rib, and
- arches *intermediately* over the Apex of the Lung.

It is thus subdivided into **three Parts**, 1st or *Ascending*, 2nd or *Transverse*, and 3rd or *Descending*.

Relation to Muscles, etc.
- In the *First* and *Second* Parts it *rests on* the summit of the Pleura, and in the *Third* Part on the 1st Rib.
- „ „ *Second* „ *Third* „ „ *lies in front* of the Scalenus Medius „ „ *First* „ in front of the Longus Colli.
- „ „ *First* „ *Second* „ „ *lies beneath* „ Sterno-mastoid „ „ *Third* „ beneath the Integuments.
- The *First Part* is also covered by the Hyoid Depressors, the *Second* by the Scalenus Anticus, and the *Third* is overlapped by the Clavicle.

- The *First* and *Third Parts* are each *invested* by a Sheath of Deep Cervical Fascia.
- The Sheath on the *Third* Part is continued on the Axillary Vessels into the Axilla and is connected with the Costo-coracoid Membrane.
- „ „ „ *First* „ „ „ Great „ „ Thorax „ „ „ Pericardium.

Relation to Vessels and Nerves.—Considerable analogy may be noticed in the relations of the 1st and 3rd Parts of the Subclavian, and of the three Carotid Arteries, thus :—the Arteries in relation with them are in multiples of two; the Veins in each case are four in number, one being parallel to the Vessel and three crossing it, or three being parallel and one crossing it; the Nerves are in pairs, two being usually in front and two behind.

First Part.

to *Arteries*	(4)	*four Branches* are given off. (usually three only on right side).	
to *Veins*	(4)	Subclavian, below, lying *parallel*.	
		Internal Jugular, Anterior Jugular*, Vertebral	crossing, *transversely*.
to *Nerves*	(4)	Nerve to Subclavius, crossing	*in front*
		Lowest Cord of Brachial Plexus lying parallel	*behind*
		Desc. Cut. Ns. of Cerv. Plex. in Integuments	*in front*
		Long Thoracic N. of Brach. Plex. in Scal. Med.	*behind*

* Generally separated by Hyoid Muscles.

Third Part.

	(2)	Transverse Cervical, Suprascapular	crossing.
	(4)	External Jugular, Suprascapular, Transverse Cervical, Subclavian †	crossing *transv.*
			lying *parallel*.
	(4)	Vagus, Cardiac of Sympathetic	crossing *in front*.
		Sympathetic, Recurrent of Vagus (on right side only)	crossing *behind*.

† Forming a Plexus over the Artery.

The **Second Part**, lying behind the Scalenus Anticus, has no Vessels or Nerves immediately in relation with it.

On the Anterior Surface of the Scalenus Anticus lie { the Suprascapular and Transverse Cervical Arteries and Subclavian Vein *transversely*, and the Phrenic Nerve *longitudinally*.

The **Branches** are described later on.

COMMON CAROTID ARTERY.

Course
- Commences its course in the Neck opposite the *upper border* of the Sterno-clavicular Articulation,
- becomes comparatively superficial ,, ,, ,, ,, ,, Cricoid Cartilage, and
- divides into Ext. and Int. Carotid ,, ,, ,, ,, ,, Thyroid ,,

Relation to *Muscles*, etc.
- Lies *upon* Longus Colli *below* and Rectus Anticus Major *above*, being separated by them from the Vertebræ.
- ,, *beneath* Sterno-mastoid (covered by it below, overlapped by it above), and also beneath Hyoid Depressors below.
- ,, *against* { the structures in mid-line of Neck on *inner* side, viz.— { Larynx and Pharynx / Trachea & Œsophagus } with Thyroid Body.
  - ,, ,, under the Sterno-mastoid ,, *outer* ,, viz.— Glandulæ Concatenatæ.
- ,, *within* a Sheath of Deep Cervical Fascia together with Int. Jugular *Vein* and Vagus *Nerve* (both to its *outer* side).

to *Arteries* (2)
- Main trunk of *Inferior* Thyroid crosses *beneath* it *below*.
- Sterno-mastoid Br. of *Superior* ,, ,, *over* ,, *above*.

—There are no Branches arising from it.

to *Veins* (4)
- Internal Jugular, lying *parallel* on *outer* side.
- Superior Thyroid, Middle ,, , Anterior Jugular* — crossing *transversely*.

to *Nerves* (4)
- Descendens Noni over Sheath, Pneumogastric in ,, — lying *parallel*.
- Sympathetic beneath ,,
- Recurrent Laryngeal *crossing* beneath it *below*.

* Separated by Muscles.

EXTERNAL CAROTID ARTERY.

Course
- Lies at first internal to the Internal Carotid, but is afterwards superficial to it.
- Its Course may be divided, like that of the Internal Carotid, into *three Parts*.

Relation to *Muscles*, etc.
- In its *first* *part* it is comparatively superficial, and rests against the Pharynx.
- ,, ,, *second* ,, ,, passes { *beneath* the Stylo-hyoid and Digastric Muscles. / *over* ,, Stylo-pharyngeus and Styloid Process.*
- ,, ,, *third* ,, ,, lies in the substance of the Parotid Gland, parallel to the Ramus of the Jaw.

* The Stylo-glossus arising from the tip of the Styloid Process is too far forward to be in relation with the Artery.

to *Arteries* (8) { *Eight* Branches are given off,—four *forwards*, two *backwards* and two *upwards* (see p. 135).

to *Veins* (4) { Ext. Jugular, lying *parallel* and superf. to it in its 3rd part.
Commun. Br. betw. Ext. & Int. Jugular
Facial
Lingual } crossing *transversely*.

to *Nerves* (4) { *over* it { 7th (Facial) *above* Digastric.
9th (Hypoglossal) *below* ,,
beneath it { Glosso-pharyngeal
Pharyngeal of Vagus } between it and Int. Carotid.

INTERNAL CAROTID (In the Neck).

Course { Passes up to Carotid Canal in the Angle between the Rectus Capitis Anticus Major behind and Pharynx internally.
At *first* it is superficial, or is overlapped by Sterno-mastoid, *next* it lies beneath Styloid Process and Stylo-pharyngeus Muscle, and *lastly* beneath Parotid Gland.

Relation to *Arteries* (4) { Asc. Pharyngeal, on inner side, lying *parallel*.
Post. Auricular, above Digastric
Occipital, below ,,
Sterno-mastoid Br. of Occipital } crossing *transversely*.

to *Veins* (4) { Internal Jugular, on inner side, lying *parallel*.
Communicating between Int. & Ext. Jugular
Facial
Lingual } crossing *transversely*.

to *Nerves* (8) { Glosso-pharyngeal
Pharyngeal of Vagus
,, ,, Sympathetic
Superior Laryngeal of Vagus } crossing *over* it
,, *beneath* ,, and { Hypoglossal
Vagus
Sympathetic (main trunk)
Loop between 1st and 2nd Cervical } lying *parallel*.

Lines of Direction of the chief Vessels of the Neck, as indicated on the Surface.

{ Int. Carotid and Common Carotid, from mid-point between Angle of Jaw and Mastoid Process to Sterno-clavicular Articulation.
External Jugular Vein ,, ,, ,, ,, ,, ,, ,, ,, Middle of Clavicle.
External Carotid ,, front of External Auditory Meatus to Cricoid Cartilage.
(Steno's Duct ,, ,, ,, ,, ,, ,, Mid-point between Nasal and Oral Apertures).

Note that the mid-point between the Jaw and Mastoid Process marks the upper end of two of these lines, and the front of the External Auditory Meatus the upper end of the other two. The Cricoid Cartilage (opposite 5th Cervical Vertebra) marks the point at which the Trachea and Œsophagus commence, opposite to which the Common Carotid becomes superficial, opposite to which the Inferior Thyroid Artery crosses inwards behind its Sheath, and opposite to which the Middle Cervical Ganglion of the Sympathetic is situated. It also indicates the lower end of the line of the External Carotid as shown above.

The named **Branches** of all the main Arteries of the Head and Neck may be grouped in *sets of two* or *four*.

BRANCHES OF THE SUBCLAVIAN ARTERY.

{ *One* (Vertebral) passes *upwards* to the Skull, *one* (Internal Mammary) passes *downwards* to the Thorax.
{ *One* (Sup. Intercostal) ,, *backwards* ,, back of Neck, and *one* (Thyroid Axis) ,, *forwards* to lower part of Neck.

Vertebral (in Neck)
- passes up through Foramina in Cerv. Trans. Proc. (from 6th upwards) to enter Spinal Canal over Arch of Atlas, accompanied by Vertebral Vein (which is in front of it) & by Vertebral Plexus of Sympathetic Nerves (which is upon it).
- lies at first *behind* Int. Jugular Vein, *between* Scalenus Anticus externally and Longus Colli internally.
- ,, next *in front of* Cervical Nerves, with lastly { the Anterior Division of 2nd Nerve on its *outer* side. ,, ,, ,, ,, 1st ,, ,, *inner* ,,

Branches, —**Spinal** *internally* through Intervertebral Foramina to Bones and Cord; and **Muscular** *externally* to Posterior Triangle.
For Course and Branches within Cranium see 'Vessels of Brain,' p. 139.

Int. Mammary
- runs *parallel to* and ½ in. from border of Sternum *beneath* Cartilages of Ribs.
- close to origin, *crosses* over Subclavian Artery and under Subclavian Vein, and is *crossed* by Phrenic Nerve,
- intermediately *lies between* Pleura and Cartilages, and lower down between Cartilages and Triangularis Sterni,
- and finally *terminates* by joining Deep Epigastric *in* substance of Rectus Muscle.

Branches
- The *first* (**Comes Nervi Phrenici**) accompanies the Phrenic Nerve and supplies *centre* of corresponding side of Diaphragm.
- The *last* (**Musculo-phrenic**) leaves trunk at 6th Intercostal Space and supplies { *circumference* of ,, ,, ,, and lower Intercostal Spaces.
- The *intermediate* Branches resemble the Parietal Brs. of the Thoracic Aorta; thus :—
- **Pericardiac** and **Mediastinal** twigs supply the Membranes and fat in the front of the Thoracic Cavity.
- **Anterior Intercostal** Arteries (each double) pass outwards in upper 5 or 6 spaces to join terminal branches of Aortic Intercostals.
- **Perforating** Branches (like Dorsal of Aortic Intercostals) pass one in each space to Muscles and Integuments by side of Sternum.

Thyroid Axis, —¼ in. long, giving off Inferior Thyroid *inwards,* Suprascapular and Transverse Cervical *outwards.*
Inferior Thyroid,—passes first up to 5th Cervical Vertebra, then inwards to Thyroid Body behind Carotid Sheath and Middle Cervical Ganglion.

Branches
- **Ascending Cervical*** { passing vertically upwards between Scalenus Anticus and Rectus Anticus Major, supplying neighbouring Muscles, Vertebræ and Spinal Cord.
- **Inferior Laryngeal, Tracheal** and **Œsophageal.**

Suprascapular†
- passing transversely outwards { over Scalenus Ant. and 3rd Part of Subclavian Art. behind Clavicle and Subclavius Muscle } to end upon back of Scapula.
- gives **Supra-acromial, Articular, Infrascapular** and **Infraspinous** Branches, for which see 'Arteries of Shoulder.'

* See note on Profunda Cervicis, p. 135.
† See 'Suprascapular Nerve and Artery,' in Appendix.

Transverse Cervical { passes transversely outwards, parallel to but higher than Suprascapular Artery as far as Trapezius, then divides into { Superficial Cervical Artery, which supplies structures in lower part of Posterior Triangle, Posterior Scapular ,, * ,, runs down posterior border of Scapula beneath attached Muscles.

* For distribution see 'Arteries of Scapula.'

Sup. Intercostal { arises from First Part of Subclavian on the left side, and from Second Part on the right side. passes backwards and downwards behind summit of Pleura in front of Neck of 1st Rib to end in 1st Intercostal Space. gives off between Neck of 1st Rib and 1st Cervical Transverse Process the Profunda Cervicis.

Profunda Cervicis { ascends between Complexus and Semispinalis to Sub-occipital Triangle, to anastomose with Princeps Cervicis from Occipital and Muscular twigs from Vertebral (see Diagram).

There are thus three Arteries in the Neck which pass up parallel to the Transverse Processes, viz., the Ascending Cervical in front of the Processes, the Deep Cervical behind them (separated by Muscles), and the Vertebral within them. The three corresponding Veins unite at the lower part of the Neck to enter the Subclavian as the Vertebral Vein.

BRANCHES OF THE EXTERNAL CAROTID ARTERY.

The Four Anterior Branches (see p. 133) supply { the *first* (Sup. Thyroid), —structures connected with the Larynx, ,, *second* (Lingual) ,— ,, between the Larynx and Lower Jaw, ,, *third* (Facial) ,— ,, in the superficial parts of the Face, ,, *fourth* (Int. Maxillary),— ,, ,, deep ,, ,, ,, *

* In addition each Vessel gives offsets to structures connected with the Pharynx.

Superior Thyroid Artery { arises *just below* Great Cornu of Hyoid Bone, and running downwards by side of Thyroid Cartilage ends in the upper and anterior part of the Thyroid Body, giving twigs also to the Inf. Constrictor of the Pharynx.

Branches { **(1) Hyoid** and **(2) Crico-thyroid** lying transversely on Thyro-hyoid and Crico-thyroid Membranes respectively. **(3) Sup. Laryngeal** accompanying Sup. Laryngeal Nerve to Larynx, & **(4) Sterno-mastoid** crossing Carotid Sheath to Sterno-mastoid.

Lingual Artery { arises *opposite* Great Cornu of Hyoid Bone, and passes in its 1st part *upwards* and *forwards*, in its 2nd *forwards*, in its 3rd *upwards* and *forwards*. [Genio-hyo-glossus. lies in its 1st part superficially, in its 2nd between Hyo-glossus and Middle Constrictor, in its 3rd on outer surface of

Its course is parallel to that of the Facial Artery on the Face.

Branches { **(1) Hyoid,** *transverse,* along upper border of Hyoid Bone. **(2) Dorsal of Tongue,** vertical, *beneath* Hyo-glossus, to Tongue and Tonsil.* **(3) Sublingual** ,, *superficial to* ,, ,, Subling. Gland and Mucous Membrane. **(4) Ranine,** *longitudinal* ,, under surface of Tongue, parallel to Frænum.

* See 'Arteries of Pharynx.'

Facial Artery.

In Neck
- arises *just above* Great Cornu of Hyoid Bone, and passes upwards and forwards to the Lower Jaw.
- lies *at first* (1) superficially, *then* passes (2) under Digastric and Stylo-hyoid, and *lastly* (3) into Submaxillary Gland.*

* Compare with relations of External Carotid.

Branches
- (1) **Ascending Palatine,** *vertical,* between { Stylo-glossus and Stylo-pharyngeus.
- (2) **Tonsillar** ,, ,, { Stylo-glossus and Internal Pterygoid.
- (3) **Glandular,** *deep,* to Submaxillary Gland.
- (4) **Submental,** *superficial,* to parts below Ramus of Jaw.

On Face
- reaches Face anterior to insertion of Masseter, passes first *upwards* and *forwards* to Angle of Mouth,
- then directly *forwards* above Upper Lip, and lastly *upwards* and *forwards* towards inner angle of Orbit.
- is *at first* covered by Platysma, *then* crossed by Zygomaticus Major, and *lastly* overlapped by Levator Alæque Nasi,
- ,, ,, rests upon Buccinator ,, on Levator Anguli Oris ,, ,, on Levator Labii Superioris.

For relation to Facial Vein, see 'Veins of Head and Neck.'

The *four* named Branches are all directed inwards, *two below* and *two above* the Mouth. Unnamed branches pass outwards.

Branches
- (1) **Inferior Labial,** betw. { Depressor Anguli Oris & Bone (Inferior Maxilla) } to structures of Chin.
- (2) **Inferior Coronary,** betw. { Orbicularis Oris & Mucous Membrane } to Lower Lip.
- (3) **Superior Coronary** ,, { Orbicularis Oris & Mucous Membrane } to upper Lip and Nose.*
- (4) **Lateral Nasal** ,, { Levator Alæque Nasi and Bone, etc., of Nose } to Ala and Dorsum of Nose.

* By Artery of Septum.

The terminal part of the Facial Artery, named 'Angular,' joins the Nasal Branch of the Ophthalmic of the Internal Carotid.

LINGUAL, FACIAL AND PHARYNGEAL ARTERIES.

1.-Internal Carotid.
2.-External " .
3.-Superior Thyroid.
4.-Ascending Pharyngeal.
5.- Ext. Brs. of do:
6.- Pharyngeal Brs. of do:
7.- Meningeal Br " ".
8.- Palatine " " ".
9.-Lingual A.
10.- Dorsal A. of Tongue.
11.- Ranine A.

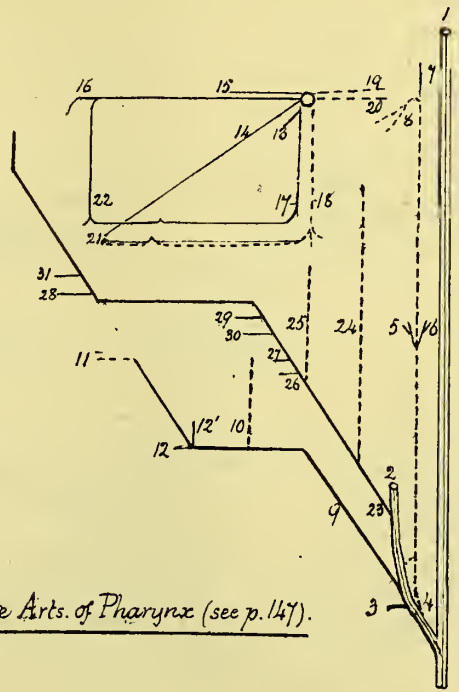

12 - Superior Hyoid A.
12'.- Sublingual A.
13-22-Term. Brs. of Int. Maxillary (See p.137 for names).
23.- Facial-Artery.
24.- Asc.ds Palatine.
25.- Tonsillar A:
26.- Glandular Brs.
27.- Submental A.
28-29.- Sup. & Inf. Coronary.
30.- Inf. Labial A.
31.- Lateral Nasal.

The dotted lines indicate Arts. of Pharynx (see p. 147).

INTERNAL MAXILLARY ART. – BRANCHES.

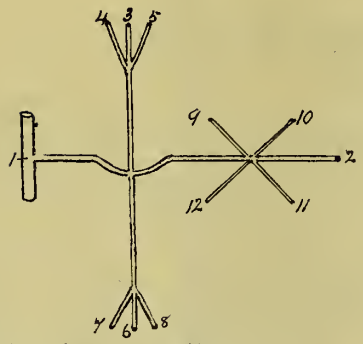

OF FIRST AND SECOND PARTS:-

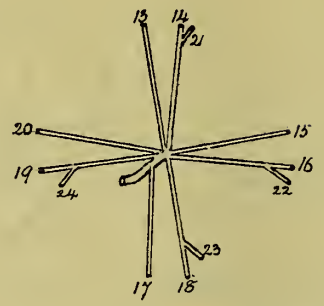

OF THIRD PART:-

1.- External Carotid.
2.- Internal Maxillary.
3.- Great Meningeal.
4.- Small " .
5.- Tympanic.
6.- Inferior Dental.
7.- Mylo-hyoid.
8.- Gustatory.
9.- Masseteric.
10.- Deep Temporal.
11.- Buccal.
12.- Pterygoid.
13.- Superior Nasal.
14.- Naso-palatine.
15.- Orbital.
16.- Infraorbital.
17.- Alveolar.
18.- Descending Palatine.
19.- Vidian.
20.- Pterygo-palatine.
21.- Palatine Br. of Naso-pal.
22.- Ant. Dental Br.
23.- Inferior Nasal Br.
24.- Eustachian Br.

Internal Maxillary Artery.

Relations, etc.
- arises in Parotid Gland opposite neck of Condyle of Lower Jaw.
- passes in its 1st *part* betw. { Neck of Condyle & Int. Lateral Lig. } in its 2nd betw. { Ext. Pterygoid Coronoid Proc. } in its 3rd { betw. Heads of Ext. Pterygoid, into Spheno-Maxillary Fossa.

Branches
- In its 1st *part* it gives off *two*; in its 2nd *part*, *four*; and in its 3rd *part*, *eight* (or six).
- The Branches of the 1st and 3rd parts all pass through bony Canals, those of the 2nd part are all Muscular.

Of First Part (2)
- **Great Meningeal*** { passes *vertically upwards* on Int. Lateral Lig. between Roots of Auriculo-temporal Nerve to Foramen Spinosum. gives off *backwards* the Tympanic Branch to enter Glaserian Fissure, & *forwards* Small Meningeal to enter Foramen Ovale.
- **Inferior Dental†** { passes *vertically downwards* on Internal Lateral Lig. with Inferior Dental Nerve to Dental Canal in Lower Jaw. gives off *inwards* the Mylo-hyoid Branch, and *forwards* a Branch to accompany the Gustatory Nerve.

* For Distribution see 'Meningeal Arteries.' † For Distribution see 'Arteries of Teeth.'

Of Second Part (4)
- **Temporal** (Deep), with Deep Temporal Nerve,
- **Buccal,** with Buccal Nerve,

and
- **Masseteric,** with Masseteric Nerve.
- **Pterygoid** twigs to Pterygoid Muscles.

Of Third Part (8)

two forwards	to Orbit,	—**Orbital***	and	**Infraorbital.**
,, *inwards*	,, Nose,	—**Superior Nasal**	,,	**Naso-palatine.***
,, *downwards*	,, Mouth,	—**Sup. Dental**	,,	**Descending (Great) Palatine.**
,, *backwards*	,, Pharynx,	—**Pterygo-palatine**	,,	**Vidian.**

* Frequently not described as special branches.

The Branches forwards and downwards correspond with branches of the Superior Maxillary Nerve.
,, ,, backwards ,, inwards ,, ,, ,, ,, Meckel's Ganglion (see 'Meckel's Ganglion').

In the case of each of these pairs one of the Vessels is simple in its distribution, whilst the other gives off a special secondary branch to some other Region; thus:

- The **Orbital** Branch accompanies the Temporo-malar Nerve and is distributed with it.
- The **Sup. Nasal** Branches accompany the Superior Nasal Nerves to the upper and back part of the Nose.
- ,, **Sup. Dental** (Alveolar) Branch accompanies ,, ,, Dental ,, ,, ,, Teeth and Gums.
- ,, **Pterygo-palatine** ,, ,, ,, Pterygo-palatine Nerve ,, Roof of the Pharynx.

- ,, **Infraorbital** ,, ,, ,, Infraorbital Nerve to the Face, and gives a branch to the upper Incisors and Canines.
- ,, **Naso-palatine** ,, ,, ,, Naso-palatine Nerve ,, Septum Nasi ,, ,, ,, ,, Mouth through the Ant. Palatine Foramen.
- ,, **Descending Palatine** ,, ,, ,, Ant., Post. and Ext. Palatine Nerves to Palate and Tonsil, and gives Inf. Nasal to lower and back part of Nose.
- ,, **Vidian** ,, ,, ,, ,, Vidian Nerve to the Pharynx, and gives a branch to the Tympanum.

The Two Posterior Branches supply { *one,* the Occipital, the posterior part of the Scalp and the Dura Mater,
the other, ,, Post. Auricular, ,, lateral and post. parts ,, ,, ,, Ear.

Posterior Auricular Artery { arises just above Digastric Muscle, is crossed by the Facial Nerve, and ends superficially over the Mastoid Process with and like the Posterior Auricular Nerve.

Branches (2) { (1) **Stylo-mastoid,** through Stylo-mastoid Foramen to Tympanum. See 'Arteries of Tympanum.'
(2) **Auricular,** through or over margin of Cartilage of Auricle to supply anterior surface.

Occipital Artery. { arises just below Digastric, hooks round the Ninth Nerve, & passes deeply beneath Mastoid Process & Muscles attached to it.
rests *first* on Carotid Sheath, *next* in Occipital Groove, and *lastly* upon the Superior Oblique and Complexus.
finally pierces the Trapezius to ramify over the posterior part of the Scalp.

Branches { (1) **Sterno-mastoid,** crossing Carotid Sheath.
(2) **Meningeal (Post.),** accompanying Int. Jugular Vein.
(3) **Auricular,** to back of Auricle, etc.
(4) **Princeps Cervicis,** to upper and back part of Neck.

Compare the Occipital and Posterior Auricular Arteries.

The Two Ascending Branches arise, one from the *beginning,* the other from the *end* of the External Carotid.
{ *one,* the Ascending Pharyngeal, ends *deeply* in the upper part of the Pharynx and base of Skull,
the other ,, Temporal, ends *superficially* on the lateral and anterior part of the Scalp.

Ascending Pharyngeal Artery { Arises just above origin of External Carotid, and passes up to the Base of the Skull parallel and internal to Internal Carotid,
ends opposite the upper border of Superior Constrictor in branches to Pharynx and Eustachian Tube.

Branches { (1) **External,** to Recti Antici, etc.
(2) **Meningeal,** through Foramen Lacerum Medium.
(3) **Pharyngeal,** to Constrictors.
(4) **Palatine,** to Soft Palate and Tonsil.*

* Passing over margin of Superior Constrictor, and subdividing to form with its fellow two arches in the Soft Palate, near the upper and lower borders respectively.

Temporal Artery { passes upwards superficially in the line of External Carotid, and divides 2 in. above Zygoma into Anterior and Posterior Branches.

Branches
(1) **Transverse Facial** { arising *just below* Zygoma, passing forwards above Parotid Duct.
(2) **Middle Temporal** { arising *just above* Zygoma, passing into Temporal Muscle.
(3) **Ant. Temporal,** runs *transversely forwards,* an inch above Orbit.
(4) **Post. Temporal** ,, *vertically upwards,* in front of Pinna of Ear
(5) **Parotid,** (6) **Articular,** (7) **Auricular,** (8) **Anastomotic** (joining with Branch of Lachrymal between layers of Temporal Fascia).

INTERNAL CAROTID.

Course, etc., in Cranium
- enters the Skull through the Carotid Canal, with Carotid and Cavernous Plexuses of *Nerves*.
- lies next in the Cavernous Sinus with the *Nerves* passing through the Sphenoidal Fissure external to it.
- divides opposite Anterior Clinoid Process, lying between the 2nd and 3rd *Nerves*.

Branches
- *Two* in Carotid Canal, viz. : —Art. Receptaculi and Branches to Tympanum.
- *Four* in Cranial Cavity, viz. :—Ophthalmic, Post-Communicating, Ant. and Middle Cerebral.

Ophthalmic
- passes into Orbit through Optic Foramen on *outer side* of Optic Nerve,
- next crosses *over* the Nerve, and
- finally runs along the *inner side* of Orbit to end on the Face.

It gives off *three Sets* of *Branches*, one on the *outer* side, one *over*, and one on the *inner* side of the Optic Nerve.
The *First Set* comprises *two* Arteries, the *Second three*, and the *Third four*.
The first and last Sets supply parts external to the Orbit, and the other parts within it.

First Set
- **Lachrymal,** accompanying Lachrymal Nerve, and anastomosing with Great Meningeal through Sphenoidal Fissure.
- **Supraorbital,** ,, Frontal Nerve.

Second Set
- **Central of Retina,** runs in the substance of the Optic Nerve to innermost coat of Eyeball, viz., the Retina.
- **Ciliary** *Short* (12) and *Long* (2), lie closely round ,, ,, and pass to the middle ,, ,, ,, Choroid.
- **Muscular,** ramify in the fat, etc., ,, ,, ,, ,, give off *Anterior* Ciliary Brs. to front of Eyeball, viz., the Iris, etc.

Third Set
- **Ethmoidal** (*two*) *inwards*, through Ethmoidal Canals to Cranial Cavity and Nose.
- **Palpebral** (,,) *outwards*, Superior and Inferior, to Eyelids and Conjunctiva.
- **Frontal** (*one*) *upwards*, with Supraorbital Nerve.
- **Nasal** (,,) *downwards*, to join termination of Facial Artery.

See also 'Arteries of Dura Mater,' 'Arteries of Nose,' and 'Arteries of Eyelids.'

For Cerebral Arteries, etc., see p. 140.

VERTEBRAL.

Course, etc., in Cranium
- winds to Anterior surface of Medulla between Roots of Suboccipital and Hypoglossal Nerves.
- joins with its fellow at the lower border of the Pons to form the Basilar Artery.

Branches (4)
- Anterior and Posterior Spinal (See 'Intercostal Arteries' p. 117).
- Posterior Meningeal and Posterior Inferior Cerebellar (see p. 140).

BASILAR ART.

extends from lower to upper border of Pons in mid-line, parallel to the 6th Nerve.

Branches (4)
- Anterior Inferior Cerebellar and Superior Cerebellar
- Transverse Arteries of Pons* and Posterior Cerebral

(See p. 140).

* One of these accompanies the Auditory Nerve to the Ear.

THE CEREBRUM is *supplied* by Branches from *three* Vessels { the two Internal Carotids *anteriorly*, „ Basilar *posteriorly*.

Each **Carotid** supplies the Cerebrum by *two* Branches, viz., the Anterior and Middle Cerebral.
The **Basilar** „ „ „ *four* „ „ Posterior Cerebral and Superior Cerebellar on each side.

Anterior Cerebral winds round the Corpus Callosum in the Median Fissure to supply the *ant.* and *int.* aspects of the Hemisphere.
Middle Cerebral „ „ Island of Reil „ Sylvian „ „ „ *external* aspect „ „
Posterior Cerebral „ „ Crus Cerebri parallel to the Transverse „ „ „ *posterior* „ „ „
Superior Cerebellar „ „ { parallel to the Post. Cerebral Art. (separated at first by 3rd Nerve) } „ { a twig to *interior* of Cerebrum. branches to upper surface of Cerebellum.

Each Vessel gives off special twigs into the substance of the Hemisphere ; thus :—
The Anterior and Middle Cerebral give branches to the Anterior Perforated Spot.
„ Middle „ Posterior „ „ „ Choroid Plexus of the Lateral Ventricle.
„ Posterior Cerebral gives twigs to the Posterior Perforated Spot (floor of Third Ventricle).
„ Superior Cerebellar „ „ Velum Interpositum (roof „ „).

CIRCLE OF WILLIS.
The **Anterior Cerebral** are connected with one another by the **Anterior Communicating** and spring from the **Internal Carotids.**
The **Posterior** „ „ „ „ the Int. Carotids „ **Posterior** „ „ „ „ **Basilar** (See Diagram).

THE CEREBELLUM is supplied by branches from *three* Vessels, viz., { the two Vertebrals *posteriorly*. „ Basilar *anteriorly*.

Each **Vertebral** supplies the Cerebellum by *one* Branch, „ „ Posterior Inferior Cerebellar.
The **Basilar** „ „ „ *four* Branches „ „ Anterior, Inferior and the Superior Cerebellar on each side.

Hence there are *two* Branches for the upper surface of the Cerebellum, and *four* for its lower surface.

Of these Arteries, one, the **Anterior Inferior Cerebellar**, is unimportant.
The **Superior Cerebellar** winds round the Crus Cerebri behind the 3rd Nerve, parallel to the 4th, to Superior Surface of Cerebellum.
The **Inferior** „ **(Post.)** „ „ Restiform Body between the Vagus and Spinal Acc. Nerves to Inf. „ „

Each gives off a special Choroidal Branch ; thus :
Superior Cerebellar to Choroid Plexus of Third Ventricle (as above mentioned).
Inferior „ „ „ Fourth „

Compare the arterial supply of the Cerebrum and Cerebellum as indicated above.

There are *four* **Choroid Arteries** on each side.

two passing to the Lateral Ventricle { one from the Anterior Cerebral. „ „ Posterior „ }
one „ „ Third „ „ Superior Cerebellar. }
one „ „ Fourth „ „ Inferior „ (Post.). }

ARTERIES OF CEREBRUM.

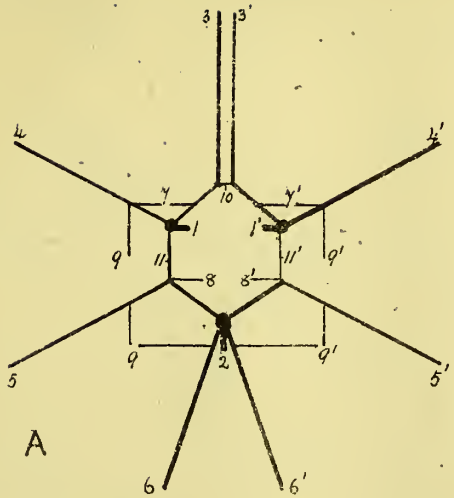

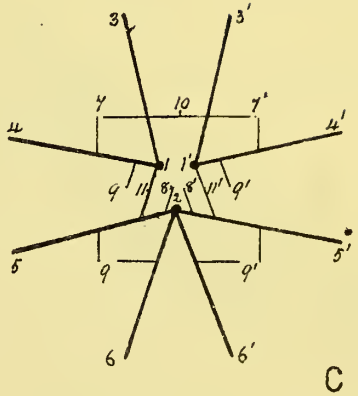

A. ARTERIES ON BASE OF CEREBRUM.

1 & 1' - Internal Carotids - Rt & Lft
2 - Basilar Art.
3 & 3' - Anterior Cerebral - Rt & Lft
4 & 4' - Middle " "

B. CIRCLE OF WILLIS (Right half).

5 & 5' - Posterior Cerebral - Rt & Lft
6 & 6' - Superior Cerebellar " "
7 & 7' - Brs. to Ant. Perfor. Spots " "
8 & 8' - " " Post. " " " "

C. ARTERIES ON BASE (Very diagram).

9 & 9' - Choroid Brs. - Rt & Lft.
10. - Ant. Commun. Art.
11 & 11' Post. " Arts. - Rt & Lft.

AXILLARY ARTERY.

RELATION TO NERVES.

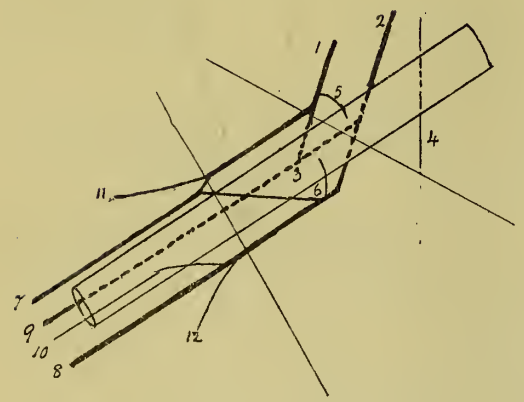

ARRANGEMENT OF BRANCHES.

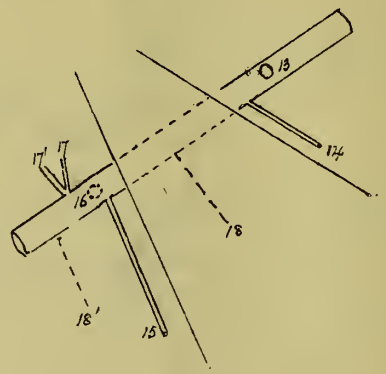

1.- Outer Cord of Brachial Plexus.
2.- Inner " " "
3.- Middle " " "
4.- Nerve to Serratus Magnus
5.- Ext. Ant. Thoracic N.
6.- Int. " " "
7.- Median Nerve.
8.- Ulnar "
9.- Musc.-spiral "
10.- Int. Cutan. "
11.- Musc.-Cutan. "
12.- Nerve of Wrisberg.

13.- Acromio-thoracic Artery.
14.- Superior " " .
15.- Long " "
16.- Subscapular "
17 & 17'- Ant. & Post. Circumflex Arts.
18 & 18'- Alar Thoracic & Ext. Mammary Arts.

AXILLARY ARTERY.

Course and Relations to *Muscles*, etc.

- Commences at the *lower border* of the 1st Rib and ends at the *lower border* of the Teres Major.
- In its *first part* it *rests upon* the 1st Intercostal Space (wall of Thorax) and upon the Serratus Magnus (1st Digit.).
- ,, *second* ,, ,, ,, ,, ,, fat, etc., of upper part of Axilla.
- ,, *third* ,, ,, ,, *against* ,, Coraco-brachialis close to Humerus ,, crosses Subscap., Lat. Dorsi & Teres Major.
- ,, *first and third parts* it is *covered* by Pectoralis Major; and in the *second* both by it and Pectoralis Minor.

The *first* part is also *invested* by the Sheath prolonged from the Cervical Fascia, and by the Costo-coracoid Membrane.
,, *third* ,, ,, *covered* ,, Skin and Axillary Fascia below the lower border of the Pectoralis Major.

to *Vessels* — In its *upper* $\frac{2}{3}$ the Axillary Vein lies to its inner side,
- In its *lower* $\frac{1}{3}$ the two Venæ Comites accompany it.
- ,, *upper* $\frac{1}{3}$,, Cephalic Vein crosses it.

to *Nerves* (4 in each part)

- In its *first part, two* Cords of the Brachial Plexus lie to its *outer side*, Long Thoracic N. *behind*, and Ext. Ant. Thoracic N. *in front*.
- ,, *second* ,, *three* ,, ,, ,, ,, ,, one *on each side* and one *behind*, and the Int. ,, ,, ,,
- ,, *third* ,, *four* Branches* ,, ,, ,, to Forearm
  - Median, to *outer side*, Musculo-spiral *behind*,
  - Ulnar, ,, *inner* ,, Internal Cutaneous *in front*.

* The other two descending Branches are separated from the Artery
- the Musculo-cutaneous by the Coraco-brachialis Muscle.
- ,, Nerve of Wrisberg by the Axillary Vein or Veins.

Branches,—*Six,**

One,	**Acromio-thoracic,**	passes *forwards*	from *front* of Artery,	*above*	Pectoralis Minor,	to supply *ant.* wall of Axilla.
One,	**Subscapular,**	,, *backwards*	,, *back* ,,	*below*	,, ,, ,,	*post.* ,, ,,

Two,	**Sup.** or **Short Thoracic**	pass *inwards*	the Sup. Thoracic	above *upper* edge of	,, ,,	to 1st or 2nd Intercostal Space.
	Inf. or **Long Thoracic**		,, Long ,,	along *lower* ,,	,, ,,	,, 5th or 6th ,, ,,
Two,	**Anterior Circumflex**	,, *outwards*	,, Ant. (small)	*below* Pect. Min.,	crossing beneath Biceps	to Delt. & Shoulder-joint.
	Posterior ,,		,, Post. (large)	,, ,, ,, ,, ,,	Triceps ,, ,, ,,	,, & Skin.

* All the structures in connection with the Axilla may be grouped in sets of *three* or *six* (see 'Muscles of Shoulder' and 'Brachial Plexus').

There are occasionally *two* other Branches
- **Alar Thoracic**, beneath Pectoralis Minor
- **External Mammary**, at lower border of Axilla

to Fat and Glands of Space.

ANASTOMOSES OVER THE SCAPULA.

Suprascapular Artery, along *Superior* Border of Bone, ends on the *Posterior* Surface, giving Infrascapular Branch to *Anterior* Surface
Subscapular ,, ,, *External* ,, ,, ,, ,, *Anterior* ,, ,, Dorsalis Scapulæ ,, *Posterior* ,,
Post. Scapular ,, ,, *Internal* ,, ,, ,, *both* Surfaces ,, Branches equally to *each* ,,
These Arteries communicate with each other on both surfaces, forming two sets of Anastomoses, one in the Muscles and the other on the Bone.

BRACHIAL ARTERY.

Course { from the lower border of the Teres Major to a point half an inch below the bend of the Elbow.
{ the surface line being drawn from mid-point between folds of Axilla externally to mid-point between Condyles of Humerus.

Relation to *Muscles*, etc. { is covered by the Integuments, etc., in its whole course, and is crossed just before termination by the Bicipital Fascia.
{ lying first on the Triceps, lastly against the Biceps (Tendon), intermediately on the Coraco-brachialis and Brachialis Anticus.
{ resting in the upper part of its course against Coraco-brachialis and Biceps, and in the last part in the space between Supinator Longus and Pronator Teres.

to *Veins* (4) Two Venæ Comites accompany it, the Basilic lies superficial to it, and the Median Basilic crosses it below.

to *Nerves* (2) { the Median Nerve lies *in front of* it in its upper part, and crossing it superficially lies on its *inner* side below.
{ ,, Musculo-spiral ,, ,, *behind* ,, ,, ,, piercing the Triceps reappears ,, *outer* ,, ,,
{ The Internal Cutaneous and Ulnar Nerves leave it close to its commencement.

Branches (*four*)*

{ **Superior Profunda**† arising near the *commencement* of the Artery accompanies the Musculo-spiral Nerve to Ext. Condyle of Humerus.
{ **Inferior Profunda**† ,, about the *middle* ,, ,, ,, ,, Ulnar ,, Int. ,, ,,

{ **Nutrient** ,, ,, ,, ,, ,, enters the Humerus near insertion of Coraco-brachialis.
{ **Anastomotic**† ,, near the *lower end* ,, ,, (an inch above Condyle) passes down and in to Int. Condyle.

* The Structures lying round about the Elbow may be grouped in sets of two or four (see 'Muscles of Elbow').

† For termination of these Branches see 'Anastomosis round Elbow-joint' (p. 144).

ANASTOMOSES OF SCAPULAR ARTS.

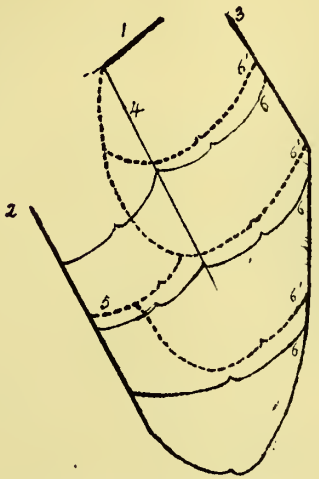

1.- Suprascapular Artery.
2.- Subscapular " .
3.- Post. Scapular "
4 - Infrascapular "
5 - Dorsal Scapular "
6 & 6'- Ant. & Post. Brs. of Post. Scap. Art.

ANASTOMOSES ROUND ELBOW.

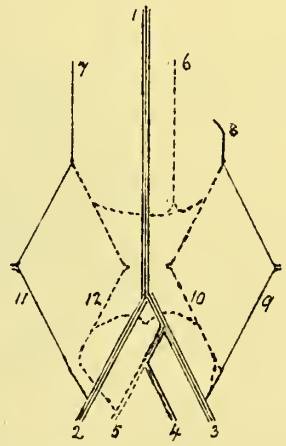

1:- Brachial Artery.
2:- Radial " "
3:- Ulnar " "
4 - Ant. Inteross " "
5 - Post. " "
6 - Inf. Profunda "
7.- Sup. Profunda Artery.
8.- Anastomotic "
9.- Ant. Ulnar Recurrent A.
10.- Post. " " "
11 - Radial " "
12 - Post. Inteross " "

ARTERIES OF FOREARM.

RELATIVE POSITIONS.

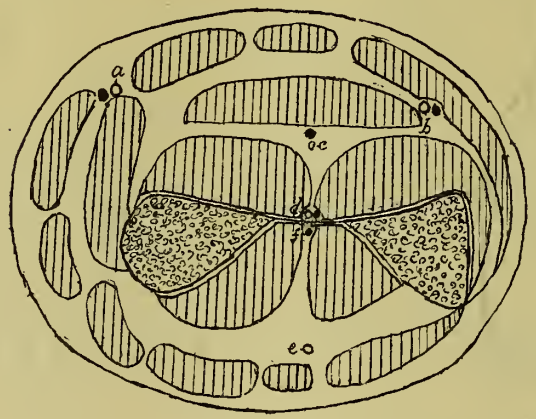

a.- Radial Artery.
b.- Ulnar " .
c.- Median " .
d.- Art. Inteross " .

e.- Post. Inteross. Artery.
f.- " " Nerve.

The Nerves accompanying the other Arts. are represented by dots.

For the Muscles see p. 95.

ULNAR AND RADIAL ARTERIES.

The **Ulnar**, the *larger*, lies *deeply* *above* but *superficially below*, and in the Hand forms Superficial Palmar Arch.
,, **Radial** ,, *smaller*, ,, *superficially* ,, *deeply* ,, ,, ,, ,, Deep ,, ,,

In Forearm
- **Ulnar** passes downwards and inwards
  - beneath Muscles arising from Int. Condyle above, and overlapped by Flexor Carpi Ulnaris.
  - resting on the *three* Muscles attached to Ant. Surface of Ulna (see 'Ulna').
- **Radial** ,, ,, ,, outwards
  - beneath the Integuments, overlapped by Supinator Longus.
  - resting on the *six* Muscles attached to the ant. surf. of Radius (see 'Radius').

Each Artery is accompanied by Venæ Comites.
The Ulnar is accompanied by the Ulnar Nerve in its lower $\frac{2}{3}$, the Radial by the Radial Nerve in its middle $\frac{1}{3}$ only.
The Ulnar and Radial Nerves lie to the inner and outer sides of the Ulnar and Radial Arteries respectively.

Just above Wrist both Arteries lie superficially on the outer sides of the Flexor Carpi Ulnaris and Flexor Carpi Radialis respectively.

At Wrist
- **Ulnar** runs *superficially* over Annular Lig. beneath Integuments to pass into Palm beneath Palmaris Brevis.
- **Radial** ,, *deeply* ,, Ext. Lateral ,, ,, Extensors of Thumb ,, ,, ,, through 1st Dorsal Interosseous.

The Ulnar Nerve accompanies the Ulnar Artery over the Annular Ligament, to end on the inner side of the Palmar surface of the Hand.
,, Radial ,, passes away from ,, Radial ,, beneath the Supinator Longus Tendon ,, ,, outer ,, ,, Dorsal ,, ,, ,,

In Hand
- **Ulnar** curves *outwards*, resting on Flexor Tendons beneath Palmar Fascia, forming *Superficial* Palmar Arch.
- **Radial** ,, *inwards* beneath ,, ,, resting on Metacarpus ,, *Deep* ,, ,,

The *Superficial Arch* is completed by joining *externally* a branch of the Radial, viz., *Superficialis* Volæ (or Radialis Indicis).
,, *Deep* ,, ,, ,, *internally* ,, ,, Ulnar, ,, *Deep* Palmar Branch.

BRANCHES IN FOREARM.

Radial
- Radial Recurrent to anterior aspect of External Condyle of Humerus, supplying *Elbow-joint.*
  Muscular Branches, unnamed, to outer Muscles of Forearm anteriorly.
- Anterior Carpal to anterior aspect of lower end of Radius, supplying *Wrist-joint.*
  Muscular Branch (Superficialis Volæ) to outer Muscles of Palm (Muscles of Thumb).

Ulnar
- Anterior Ulnar Recurrent, to anterior aspect of Internal Condyle of Humerus.
- Posterior ,, ,, ,, posterior ,, ,, ,, ,,
- Interosseous Artery
  - Unnamed Muscular Branches, to muscles on inner side of Forearm anteriorly.
  - by Anterior Interosseous Div. to deep Muscles on front of Forearm and to Bones of Forearm.
  - ,, Posterior ,, ,, all ,, back ,, ,, ,, Elbow and Wrist-joints.
- Anterior Carpal, to join Anterior Carpal of Radial, across lower margin of anterior surface of Radius (*above* Wrist).
- Posterior ,, ,, Posterior ,, ,, ,, the back of the Carpus (*below* ,,).
- Superficial Branch, to form Superficial Palmar Arch, and to supply parts on inner side of Palm of Hand.
- Deep ,, (Communicating Branch) to join Deep Palmar Arch.

Thus for every Branch of the Radial Artery in the Forearm there are two somewhat similar Branches of the Ulnar Artery.

ANASTOMOSIS ROUND ELBOW-JOINT.

The Superior Profunda divides above the External Condyle into two branches, one going in front of it and one behind it.
,, Anastomotica ,, ,, Internal ,, ,, ,, ,, ,, ,, ,, ,, ,,
,, Anterior and Posterior Ulnar Recurrents pass up to the Internal Condyle, the Anterior ,, ,, ,, the Post. ,,
,, Radial and ,, Interosseous ,, ,, ,, External ,, ,, former ,, ,, ,, the latter ,,
,, Inferior Profunda ends behind the Internal ,,

,, Arteries in front of and behind each Condyle anastomose with each other.

,, Superior Profunda forms an arch above the Joint posteriorly with the Anastomotica and Inf. Profunda } the arteries behind the
,, Posterior Interosseous ,, ,, below ,, ,, ,, Posterior Ulnar Recurrent } Condyles.

INTEROSSEOUS ARTERIES.

Common Interosseous, an inch in length, arises from Ulnar near its origin and divides opposite upper border of Interosseous Membrane.

Anterior Interosseous
- runs down *deeply* on anterior surface of Interosseous Membrane to supply the deep Muscles and both Bones of Forearm.
- passes through the lowermost part ,, ,, ,, ,, end with Post. Interosseous in Post. Carpal Arch.

A Special Branch accompanies the Median Nerve beneath the Annular Ligament to the Superficial Palmar Arch.
Thus, of three Arteries to the Palm, one (Ulnar) passes *over* the Annular Ligament, one (Median) *beneath* it, and one (Radial) *outside* it.

Posterior Interosseous
- passes backwards above upper border of Interosseous Membrane to appear at back between { Supinator Brevis / Ext. Oss. Met. Pol. }
- runs down *superficially* along outer edge of Extensor Carpi Ulnaris to end in Posterior Carpal Arch.

The Anterior Interosseous thus lies as deeply as possible, whilst the Posterior lies superficially. Both end together in Posterior Carpal Arch.
Compare with the "Interosseous Nerves."

CARPAL ARCHES.

- **Anterior,** lies just *above* Wrist-joint along lower edge of Pronator Quadratus, resting on Radius.
- **Posterior** „ „ *below* „ „ { *receiving* above two Interosseous Arteries, viz., the Anterior and Posterior Interosseous.
  { *giving* off below „ „ „ „ the 2nd and 3rd Dorsal „

PALMAR ARCHES.

For their formation and relation see Radial and Ulnar Arteries in the Hand.

Branches.

- Superficial Arch— Four Digital to 3½ inner Fingers, lying superficial to Digital Nerves in Palm but beneath them on Fingers.
- Deep „ — { Three Palmar Interosseous to 3 inner Spaces, joining Digitals at clefts of Fingers.
  { Recurrent Branches to Wrist and Superior Perforating to join 1st Dorsal Interosseous.

Of the four Arches above mentioned { the Anterior Carpal and Deep Palmar (the two intermediate) lie the one above and the other below the Wrist-joint.
{ „ Superficial Palmar and Posterior Carpal (the most anterior and most posterior) lie „ „ „

The Superior and Inferior Perforating Arteries are both connected with the Dorsal Interosseous Arteries of the corresponding Spaces, but not with the Palmar Interosseous Arteries. The Superior joins the Deep Palmar Arch, and the Inferior the Palmar Digital Branches.

RADIAL ARTERY IN HAND.

- *On Dorsum* gives *four* Branches { Posterior Carpal to Posterior Carpal Arch, and Metacarpal to 2nd Interosseous Space,*
  { Dorsalis Pollicis and Dorsalis Indicis.
- *In Palm* „ *two* „ Princeps „ „ Radialis „

* Compare with Foot.

ARTERIES OF SCALP (*Four*).

One, Ophthalmic, sends branches backwards from the front,
One, Occipital ,, ,, forwards ,, behind.
Two, Temporal and Posterior Auricular, are placed laterally, one in front and one behind Pinna of Ear (see Diagram).

N.B.—The Frontal Artery accompanies the Supratrochlear Nerve.—The Frontal Nerve is accompanied by the Supraorbital Artery.

MENINGEAL ARTERIES.

In each of the three Fossæ of the Skull there are two small Meningeal Arteries on each side which supply the Dura-mater, etc., of the contiguous part of the *Base* of the Skull.
In the Middle Fossa is also on each side a single large Artery, which supplies the Dura-mater, etc., of the *Vault* of the Skull.

In the **Anterior Fossa** are twigs from the Ant. and Post. Ethmoidal Arteries, entering through the Ant. and Post. Ethmoidal Canals.
,, ,, **Middle** ,, ,, the Small Meningeal & Meningeal of Ascend. Pharyngeal ,, ,, ,, For. Ovale, and For. Lacerum Med.
,, ,, **Posterior** ,, ,, ,, Mening. of Vertebral & ,, ,, Occipital ,, ,, ,, ,, Magnum ,, ,, ,, Postic.
,, ,, **Middle** ,, is the Great Meningeal, lying in the Meningeal Groove ,, ,, ,, ,, Spinosum.

The **Gt. Meningeal** on entering the Skull, gives off *four* Branches radially { *outwards* to Dura Mater, etc. / *inwards* ,, Gasserian Ganglion } { *forwards* to join Lachrymal through Sphenoid. Fissure. / *backwards* to enter Tympanum ,, Hiatus Fallopii. }
It thus gives a branch to the *outer* wall of the Tympanum just before entering the Skull, and a branch to the *inner* wall just after entering it.

ARTERIES OF NOSE.

Three distinct Arteries supply the Nose; one (Internal Maxillary), from *behind*, one (Ophthalmic) from *above*, and one (Facial) from the *front*; each Artery giving two Branches.

Behind are { Superior Nasal, entering through Spheno-palatine Foramen, ramifying over Superior and Middle Turbinated Bones. / Inferior ,, (branches of Descending Palatine) ,, ,, Inferior ,, ,, ,, ,, }

In front are { Twigs from Lateral Nasal. / Artery of Septum (from Coronary Artery). }

Above are { Anterior Ethmoidal / Posterior ,, } terminal twigs.

Compare with Nerves of Nose.

ARTERIES OF TYMPANUM.

On *Outer* Wall (around Membrana Tympani) there is a circle, formed by { Stylo-mastoid from Posterior Auricular *behind*, and / Tympanic ,, Great Meningeal *in front*. }

On *Inner* Wall (over the Promontory) ,, ,, an anastomosis between { Branch of Great Meningeal through Hiatus Fallopii. / ,, ,, Vidian Artery ,, Eustachian Tube. }

A small twig or two from the Internal Carotid enters the Tympanum in front through the Carotid Canal.

ARTERIES OF SCALP.

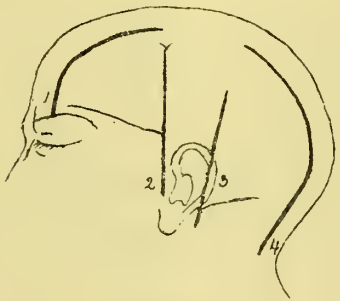

1.- Supraorbital Artery.
2.- Temporal " (Superf.).
3.- Posterior Auricular "
4.- Occipital "

See also "Cutaneous Nerves of Head & Neck."

ARTERIES OF NOSE.

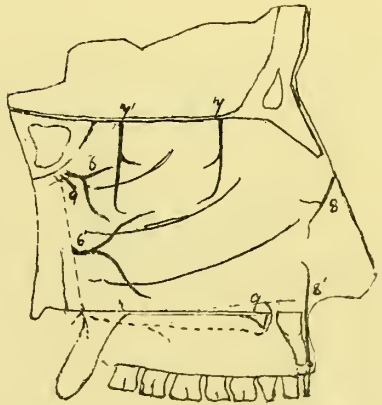

6 & 6' - Sup & Inf. Nasal Arteries.
7 & 7' - Ant. & Post. Ethmoidal Arteries.
8 & 8' - Br. of Lat. Nasal Art. & Art. of Septum.
9 - Naso-palatine Artery.

See also "Sup. Maxillary Nerve, etc."

ARTERIES OF EYELIDS.

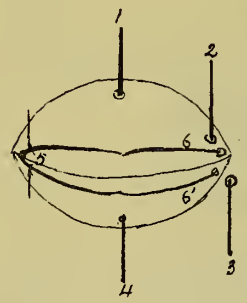

1.- Supraorbital Art.
2.- Frontal " .
3.- Nasal of Ophth^c " .
4.- Infraorbital Art.
5.- Lachrymal " .
6 & 6'- Sup. & Inf. Palp. Arts.

NERVES OF EYELIDS.

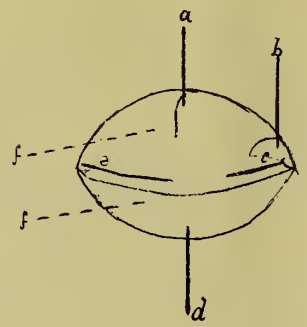

a.- Supraorbital N.
b.- Supratrochlear "
c.- Infratrochlear "
d.- Infraorbital N.
e.- Lachrymal
f.- Facial N. (Malar Brs).

See also "Cutaneous Nerves of Head & Neck."

For ARTERIES OF PHARYNX see pp147. and 148.

ARTERIES OF EYEBALL.

The **Short Ciliary** Branches (8 or 10) enter closely *round* the Optic Nerve and form a plexus throughout the Choroid.
,, **Long** ,, ,, (2) ,, one *on each side* of ,, ,, ,, ,, ,, circle round the Iris.*
,, **Anterior** ,, ,, (4 or 5) ,, *anteriorly* close to the Cornea ,, join the ,, ,, ,, ,,

* From this Circle Branches are sent into the Iris, which reunite to form a circular vessel round the Pupil.

ARTERIES OF EYELIDS.

Four in each Lid, two in each case being limited to the Lids.
In the **Upper Lid** is an Arch upon the anterior surface of the Cartilage formed by Sup. Br. of Lachrymal *externally*, and Sup. Palpebral *inter.*
,, ,, **Lower** ,, ,, ,, ,, ,, ,, ,, ,, ,, ,, Inf. ,, ,, ,, ,, Inf. ,, ,,
,, ,, **Upper** ,, *intermediately* are descending twigs of Supraorbital, whilst *above* its inner extremity are twigs of the Frontal.
,, ,, **Lower** ,, ,, ,, ascending ,, ,, Infraorbital ,, *below* ,, ,, ,, ,, Nasal.

Compare with Nerves of Eyelids.

ARTERIES OF PHARYNX, Etc.

On the *Outer Surface* of the Superior Constrictor are *four* Arteries (three supplying it), viz :—
Internal Carotid, in Sheath *posteriorly,* passing upwards to enter the Carotid Canal in Petrous Bone.

Ascending Pharyngeal	(main trunk)	,,	,,	,,		for whole of breadth of Sup. Constrictor close to Carotid Sheath.
Asc. Palatine	(of Facial)	*intermediately*	,,	,,	$\frac{2}{3}$,, ,, ,, ,,	between Stylo-pharyngeus and Stylo-glossus.
Tonsillar	(,, ,,)	*anteriorly*	,,	,,	$\frac{1}{3}$,, ,, ,, ,, ,,	Internal Pterygoid and Stylo-glossus.

The *Roof* is supplied by *two* Arteries, viz. :—
Vidian and **Pterygo-Palatine** (the former sending a branch to the Eustachian Tube).
The *Hard Palate* is supplied by *two*, viz. :—
Descending Palatine and **Naso-palatine** (Artery of Septum from Internal Maxillary).
The *Soft Palate* (with Tonsil) is supplied by *four*, viz. :—
Descending Palatine and **Ascending Pharyngeal** from *above*, **Ascending Palatine** and **Tonsillar** of Facial from *below*.

The Tonsil also receives a branch from the Dorsal Artery of the Tongue (from the Lingual).

The *Tongue* is supplied by *two*, viz. :—
The **Dorsal** of the Tongue and the **Ranine** (both from the Lingual).

Twigs may also reach it from the Tonsillar of the Facial.

The *Middle* and *Inferior Constrictors* are supplied by *two*, viz. :
The **Ascending Pharyngeal** and the **Superior Thyroid.**
The *Œsophagus* in the Neck is supplied by *two*, viz. :—
The **Superior** and **Inferior Thyroid.**

ARTERIES OF TEETH.

Upper *Molars* and *Bicuspids** are supplied by the **Alveolar**; (Sup. Dental) —*Canines* and *Incisors* by **Anterior Dental.**
Lower ,, ,, ,, ,, ,, ,, **Inf. Dental** (main trunk);— ,, ,, ,, ,, **Incisor Branch** of Inf. Dental.

The Inf. Dental Nerve supplies the lower Teeth in the same way as the Artery.
,, Sup. ,, ,, (Alveolar) differs from the Inf. and from the Arts. in supplying only the upper Molars, the Ant. Dental supplying the other Teeth.

ARTERIES OF SUBOCCIPITAL TRIANGLE.

The **Princeps Cervicis** (of the Occipital) passes *downwards* and inwards from above, } uniting over the Triangle with twigs of the
,, **Profunda Cervicis** (,, ,, Sup. Intercostal) ,, *upwards* ,, below } **Vertebral.**

ARTERIES OF LUNGS.

Pulmonary Artery { arises from Right Ventricle in front of origin of Aorta, and runs upwards to the left, on left side of Aorta, for 2 in.
divides in the concavity of the Arch of the Aorta into { *Right Branch*, the longer, passing *behind* Ascending part of Arch.
Left ,, ,, shorter ,, *in front* of Descending ,, ,,

Relations { *on either side* at its origin are the Auricular Appendages and the Coronary Arteries.
behind it ,, ,, is ,, Left Auricle.
around ,, ,, ,, ,, ,, Sheath of Serous Pericardium, common to it and to Aorta.

Since the Right Bronchus is more horizontal than the Left, it lies above the corresponding Branch of the Pulmonary Artery in the Root of the Lung, whereas the Left Bronchus lies below the level of the Left Branch. For comparative Relations of the Structures in the Root of the Lung, see 'Intercostal Arteries' (p. 117). For Bronchial Arteries see 'Thoracic Aorta' (p. 118).

ARTERIES OF STOMACH.

Three Vessels enter the walls of the Stomach at each end, viz. :—one on each border and one intermediately.
Upper Border,—**Pyloric** of Hepatic from Right Side,—**Coronary** (Gastric) of Cœliac Axis from left side.
Lower ,, —**Rt. Gastro-epiploic** ,, ,, ,, ,, ,, —**Left Gastro-epiploic** of Splenic ,, ,, ,,
Intermediately,—posteriorly, **Post. Pyloric** at Pyloric End, —**Vasa Brevia** ,, ,, at Cardiac End.

ARTERIES AND NERVES OF TEETH.

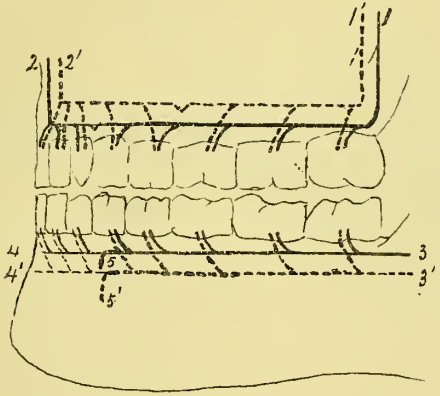

1.- Sup. Dental Artery.
1'- " " Nerve.
2 - Ant. " Artery.
2'- " " Nerve
3.- Inf. " Artery.
3'.- Inf. Dental Nerve.
4.- Incisor Br. of Inf. D. Art.
4'.- " " " Nv.
5.- Mental " " Art.
5'- " " " Nv.

ARTERIES OF STOMACH.

1.- Coronary Artery.
2.- Pyloric " .
3.- Post. Pyloric "
4.- Vasa Brevia.
5.- Left Gastro-epiploic Art.
6.- Right " " " .

ARTERIES AND VEINS IN RELATION WITH PANCREAS.

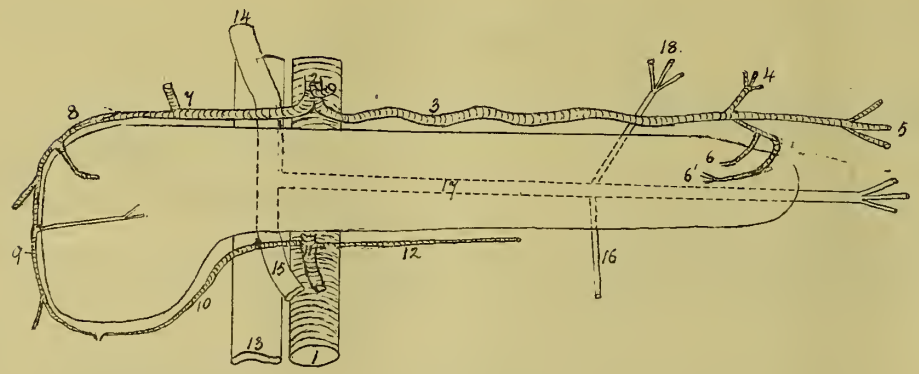

1.- Aorta.
2.- Coeliac Axis.
3.- Splenic Artery.
4.- Vasa Brevia.
5.- Terminal Brs.
6. & 6'- Pancreatic Brs. & Panc. Mag.
7.- Hepatic Artery.
8.- Gastro-duodenal Artery.
9.- Sup. Pancreatico-duodenal Art.
10.- Inf. " " "
11.- Superior Mesenteric Artery.
12.- First Br. to Small Intestine.
13.- Vena Cava Inferior.
14.- Portal Vein.
15.- Sup. Mesenteric Vein.
16.- Inf. " " .
17.- Splenic Vein.
18.- Veins from Cardiac End of Stomach.

See also pages 120 & 155.

ARTERIES OF PANCREAS.

As in the case of the Stomach, Arteries lie along each border and intermediately.

Above the *Upper Border* the **Cœliac Axis** arises from the Aorta.
Below „ *Lower* „ „ **Sup. Mesenteric** „ „ „

Along „ *Upper* „ „ **Hepatic** runs from the Cœliac Axis to the *right* and the **Splenic** to the *left*.
„ „ *Lower* „ „ **Inf. Panc.-duod.** of Sup. Mesenteric runs „ „ „ first **Artery to Small Intestine** to the *left*.
Intermediately „ **Sup. Panc.-duod.** of Hepatic sends branches inwards from the *right* & the **Pancreatic** of Splenic from the *left*.

See also 'Veins of Pancreas,' p. 155.

ARTERIES OF RECTUM.

The **Superior Hæmorrhoidal** divides at upper end of Rectum into *two* Branches running longitudinally one on each side.
Two **Middle** „ joining with Superior form with it *five* or *six* „ „ „ on Rectum *intermediately*.
Two **Inferior** „ „ „ the last-named Branches form *loops* at *lower end* of Rectum opposite Internal Sphincter.

Running *longitudinally* downwards in the *mid-line* of the Trunk in front of the Spine is the **Aorta.**

From the *lower end* of the Aorta come off on each side the main trunks for the Pelvis and Lower Limbs.

,, *upper part* ,, ,, ,, ,, ,, ,, ,, Head and Neck and Upper Limbs.

The former (the **Internal** and **External Iliacs**) arise from the Aorta by a common trunk, the **Common Iliac**, as do also the latter (the **Carotid** and **Subclavian**) on the right side by the **Innominate** Artery.

The Left Carotid and Left Subclavian are unsymmetrical, arising directly and separately from the Aorta.

Springing from Artery for Upper Limb (Subclavian) is a Branch (**Int. Mammary**) which turns *longitudinally* down near *mid-line* in front.

,, ,, ,, Lower ,, (Ext. Iliac) ,, ,, (**Epigastric**) ,, ,, ,, upwards ,, ,, ,,

Within the Rectus Muscle the Internal Mammary and Epigastric join.

There are thus *three longitudinal* Vessels in the wall of the Trunk, *one* in the mid-line behind, and *two*, one on each side of the mid-line in front.

Connecting the Aorta behind with these Vessels in front are on each side a series of arterial arches, one opposite each Dorsal Vertebra except the *first*, and each Lumbar Vertebra except the *last*. These arches are formed by the **Intercostal** and **Lumbar** Arteries *posteriorly* and outgoing Branches of the **Internal Mammary** and **Epigastric** Arteries *anteriorly* in the Dorsal and Lumbar Regions respectively.

The place of the Intercostal Arch opposite the 1st Dorsal Vertebra (1st Intercostal Space) is taken by the **Superior Intercostal**, a branch from the Subclavian, the *outer* of the two main trunks for the Head and Upper Limb.

The place of the Lumbar Arch opposite the last Lumbar Vertebra is taken by the **Ilio-lumbar**, a branch from the Internal Iliac, the *inner* of the two main trunks for the Pelvis and Lower Limb.

Springing from these Arches posteriorly, anteriorly, and laterally are perforating branches which supply the Integuments, etc.

ARTERIES OF TRUNK - WALLS.

1.- Aorta.
2-2'- Common Iliacs, Rt & Lft
3-3'- Internal " "
4-4'- External " "
5.-5'- Common Carotids "
6-6'- Subclavian Arts. "
7.- Innominate Art.

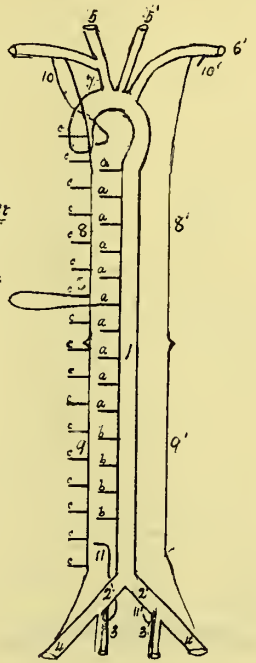

8.-8'- Int. Mammary Arts - Rt & Lft.
9.-9'- Deep Epigastric " "
10.-10'- Sup. Intercostal " "
11.-11'- Ilio-lumbar " "
a- Intercostal Arts.
b.- Lumbar "
c - Outgoing Brs. of Int. Mammary & Epigtric.

One only of the Intercostal & Lumbar Arches is indicated.

VEINS OF NECK.

1.- Subclavian Vein.
2.- Internal Jugular.
3.- External " .
4.- Innominate "

9.- Occipital Vein.
10.- Pharyngeal " .
11.- Facial "
12.- Lingual "
13.- Sup. Thyroid "
14.- Middle " "

21.- Vertebral Vein.

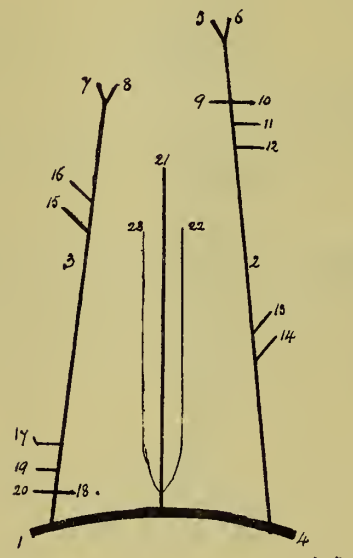

5.- Lateral Sinus.
6.- Inf. Petrosal "
7.- Temporal Vein.
8.- Int. Maxillary " .

15.- Post. Auricular V.
16.- Commun. with Int. Jug.
17.- Post. Ext. Jugular.
18.- Anterior "
19.- Transverse Cervical V.
20.- Suprascapular " .

22.- Ascending Cervical V.
23.- Deep " " .

The Subclavian Vein
- crosses inwards transversely at the root of the Neck under cover of the Clavicle.
- receives *three* veins from above
  - External Jugular, at the *outer* border of the Sterno-Mastoid,
  - Vertebral „ „ *inner* „ „ Scalenus Anticus,
  - Internal „ forming with it the Innominate Vein.

The External and the Internal Jugular Veins are each formed by the union of two Vessels, and each receives six Tributaries. The Vertebral Vein is supplemented by its union with two collateral Vessels.

External Jugular
- is formed in the Parotid Gland by the *union* of the Temporal and Internal Maxillary Veins,
- passes thence downwards *superficially* to the Cervical Fascia *over* the Sterno-mastoid, and
- ends beneath Fascia at lowermost part of *Posterior* Triangle, after crossing the **3rd** *Part* of the Subclavian Art.

Tributaries, *above*
- Communicating from Internal Jugular.
- Posterior Auricular.
- Posterior Ext. Jugular (from Post. Triangle).

below
- Anterior Jugular (usually).
- Transverse Cervical } forming a plexus over Subclavian Artery.
- Suprascapular }

Internal Jugular
- is formed below Foramen Jugulare by *union* of Lateral and Inferior Petrosal Sinuses.
- passes thence downwards *beneath* Cervical Fascia, *under* Sterno-mastoid, ext. to Int. and Common Carotids.
- ends at the lowermost part of the *Anterior* Triangle, after crossing the **1st** *Part* of the Subclavian Artery.

Tributaries, *above*
- Occipital.
- Facial.
- Lingual.

below
- Superior Thyroid.
- Middle Thyroid.
- Pharyngeal.

The upper end of the Internal Jugular and the lower end of the External, are each somewhat expanded. Compare the Jugular Veins as above described.

Vertebral Vein
- commences in Muscles, etc., below the Occiput, and receives twigs from the Spinal Canal, etc.
- descends through the Foramina in Cervical Transverse Processes in front of Vertebral Artery and crosses 1st part of Subclavian Artery.

Tributaries
- a vein from the *front* of the Spine (**Anterior Vertebral**) which accompanies the Ascending Cervical Artery.
- „ „ *back* „ „ (**Deep Cervical**) „ „ „ Deep „ „

Thus the Veins which correspond to the three Arteries which ascend *within*, *in front of*, and *behind* the Cervical Transverse Processes (see Subclavian Artery, p. 134) unite, and empty themselves by a common trunk.

Facial Vein

The Facial Vein receives blood from the Regions which lie around that supplied by the Facial Artery.

- Its *first* Tributaries are the Frontal, Supraorbital and Palpebral Veins, corresponding to Branches of the Ophthalmic Artery.
- „ *last* Tributary is the Ranine Vein „ „ a Branch „ Lingual „
- *intermediately* it receives the Ant. Int. Maxill. V. from the Pterygoid Plexus „ „ Branches „ Int. Maxillary „

The other Tributaries correspond to the Branches of the Facial Artery.

CRANIAL SINUSES.

There are *two Sets* of Sinuses { the *Posterior* comprising *four* single Sinuses and *one* pair.
the *Anterior* ,, *two* ,, ,, ,, *three* pairs.

A.—One Sinus of each Set receives Veins from the neighbouring parts of the Encephalon only.
B.—One ,, ,, ,, ,, ,, ,, special ,, ,, ,, also.
C.—The other Sinuses ,, ,, { receive ,, ,, neighbouring ,, ,, ,, and
communicate in addition with Veins on the exterior of the Skull.

A. { **Inferior Longitudinal S.** posteriorly
Transverse S. anteriorly } do not receive any special offsets.

B. { **Straight S.** posteriorly receives the Veins of Galen from the interior of the Cerebrum.
Circular S. anteriorly ,, ,, ,, the Pituitary Body.

C. { **Superior Longitudinal S.*** posteriorly ,, ,, Emissary Veins through the Parietal Foramen and Foramen Cæcum (often).
Lateral S.* ,, ,, ,, ,, ,, ,, ,, Mastoid ,, ,, Posterior Condyloid Foramen.
Occipital S. ,, ,, ,, Branches from the Plexus of Veins in the Spinal Canal.
[For. Vesalii.
Cavernous S.* anteriorly ,, ,, Ophthalmic Vein through Sphen. Fiss. and a vein from Pterygoid Plex. through
Superior Petrosal S. ,, ,, a Vein from the Internal Ear.
Inferior Petrosal S. ,, ,, an Emissary Vein through the Foramen Basis Cranii.

{ The Blood from the posterior Sinuses is entirely conveyed out of the Cranial Cavity by the Lateral Sinus.
,, ,, ,, anterior ,, partly ,, ,, ,, ,, ,, ,, and partly by the Inferior Petrosal Sinus.

{ The Inferior Petrosal Sinus joins with the Lateral Sinus below the Foramen Jugulare to form the Internal Jugular Vein.
,, Superior ,, ,, ,, ,, ,, within the Skull.

* See 'Emissary Veins,' p. 20.

SUPERIOR VENA CAVA

commences by the union of the Innominate Veins just below Cartilage of 1st Rib, on right side and *ends* at upper part of Base of Heart,
lies *between* the Aorta on the left, and the Right Phrenic Nerve on the right (by which it is separated from the Right Lung),
„ *in front of* the Root of the Right Lung and *within* a special sheath of the Serous Pericardium.

The **Tributaries** correspond to the Parietal Branches of the Thoracic Aorta { *Pericardiac* / *Mediastinal* } Veins.
Azygos Major Vein (receiving *Intercostal* Veins).

INNOMINATE VEINS { *commence* by the union of Subclavian and Internal Jugular Veins behind Sternal End of Clavicle, and
end by joining to form the Vena Cava Superior just below Cartilage of 1st Rib on the right side.

Right, 1½ in. long, lies *between* the Innominate Artery on the left & the Rt. Phrenic Nerve on the right (by which it is separated from Rt. [Lung).
Left 4½ „ „ { „ *behind* the Manubrium (upper half) *along* the upper edge of Transv. Part of Arch of Aorta.
resting *upon* the three large Branches of, and the Nerves crossing the „ „ „ „

The **Tributaries** correspond to the Branches of the Subclavian Artery (except Vertebral) { *Internal Mammary*, double, accompanying Internal Mammary Artery.
*Inferior Thyroid** from front of Trachea.
Superior Intercostal { the *Right* (often joining Azygos Major Vein).
„ *Left* crossing Arch of Aorta.

AZYGOS VEINS.

V. A. Major (Right) commences below from the Right Ascending Lumbar Vein, & enters Thorax through Aortic opening (or Rt. Crus sometimes).
V. A. Minor (Left) „ „ „ Left „ „ „ „ „ „ Left Crus (or Aortic opening sometimes).

Each passes up on its own side of the Bodies of the Dorsal Vertebræ receiving Intercostal Veins on its way,
The Minor opposite the **6**th (or 7th) Vertebra crosses beneath the Thoracic Duct to enter the Major,
„ Major „ „ **3**rd Intercostal Space, curves over the Root of the Rt. Lung „ „ „ Vena Cava Superior.

Tributaries { The *Minor* receives the Intercostal Veins of the lower **5** or 6 Spaces on the left side,
„ *Major* „ { „ „ „ „ 9 „ **10** „ „ right „ and also
Œsophageal twigs, the right Bronchial Vein,* the Vena Azygos Minor and Vena Azygos Minima.

V. A. Minima { is formed by the union of two or three Left Intercostal Veins just above those entering the Vena Azygos Minor, and
opens directly into the Vena Azygos Major.

The upper two or three Right, and the upper three or four Left Intercostal Veins unite to form the Right and Left **Superior Intercostal Veins** respectively.

* The Left Bronchial Vein generally enters the Left Superior Intercostal.

VEINS OF HEART.

- **Great Cardiac Vein** — commencing on the *front* of the Heart near the Apex, winds over the *Left* border of the Heart, and running in the *Left* Auriculo-ventricular Groove becomes continuous with the Coronary Sinus.
- **Post. Cardiac Veins** —commence on the *back* of the Heart near the Apex, and run upwards to join ,, ,, ,,
- **Oblique Vein** —runs obliquely across the back of the Left Auricle to enter ,, ,, ,,

Coronary Sinus —thus receives three sets of Veins, one from the front and one from the back of the Left Ventricle chiefly, and one from over the Left Auricle.

Venæ Cordis Parvæ —a few small vessels chiefly over the Right Ventricle anteriorly, opening directly into Right Auricle.

SPINAL VEINS.

- **Venæ Basis Vertebræ** —passing through bodies of Vertebræ, joining *anteriorly* veins on the anterior surfaces of the Vertebræ. *posteriorly* the Anterior Longitudinal Spinal Veins.
- **Dorsal Spinal Veins** — ,, between Laminæ ,, ,, ,, *anteriorly* ,, Posterior ,, ,, ,, *posteriorly* veins of Muscles, etc., of Back.

- **Ant. Longitudinal Veins**—(*two*) running vertically behind Bodies of Vertebræ, irregular and tortuous, giving branches outwards through Intervertebral Foramina.
- **Post. Longitudinal Veins**—forming a close plexus on anterior surfaces of Laminæ, joining branches of Anterior Veins through Intervertebral Foramina.

The **Veins of the Cord** —forming a plexus over the Cord, small and tortuous, communicating with Spinal Veins and Cranial Sinuses.

VEINS OF UPPER EXTREMITY.

- **Radial Vein** —commences on back of radial side of Wrist forming arch on Dorsum with Post. Ulnar V.
- **Post. Ulnar Vein**— ,, ,, ,, ,, ulnar ,, ,, ,, ,, ,, ,, Radial V.
- **Ant. Ulnar Vein**— ,, ,, front ,, ,, ,, ,, joining Post. Ulnar V. at bend of Elbow.
- **Median Vein** — ,, ,, ,, of Wrist and Palm & is joined by Br. from Deep Veins ,, ,, ,,

- **Median Vein** —divides at bend of Elbow into **Median Basilic**, the larger, shorter, and more oblique. **Median Cephalic** ,, smaller, longer ,, less ,,
- **Radial Vein** —unites with Med. Cephalic V. to form **Cephalic V.** which joins the Axillary Vein near its termination.
- **Ulnar Veins** —unite ,, Med. Basilic V. ,, ,, **Basilic V.** ,, ,, ,, Brachial Venæ Comites to form **Axillary Vein.**

AZYGOS VEINS, ETC.

1.- Vena Cava Sup.

2- Right Innominate V.

3 Left Innominate V.

4.- V. Azygos Major.

5- V. Azygos Minor.

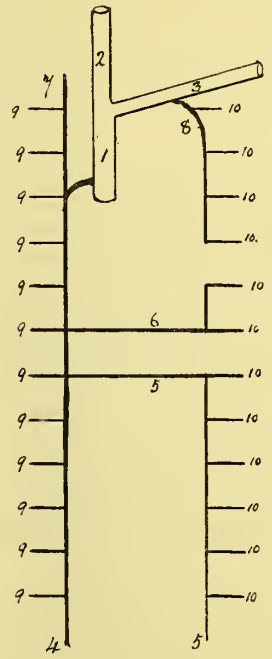

6.- V. Azygos Minima

7.- Right Sup. Intercostal V.

8.- Left Sup. Intercostal V.

9- Right Intercostal Vs

10- Left Intercostal Vs.

INFERIOR VENA CAVA
- commences on right side of 5th Lumbar Vertebra by the junction of the two Common Iliac Veins.
- ascends ,, ,, ,, Aorta, but is separated from it above by the Right Crus of the Diaphragm.
- becomes embedded in the posterior border of the Liver and passing through Diaphragm ends in Right Auricle.

It rests on all the right lateral branches of the Aorta except the Spermatic (or Ovarian) which crosses it.

Its **Tributaries** correspond to the Branches of the Abdominal Aorta which pass to the non-alimentary Viscera, and to the Abdominal Parietes. It also receives the Hepatic Veins.
On the left side the Suprarenal and Spermatic Veins open into the Renal Vein, but on the right side into the Vena Cava directly.
The Middle Sacral Vein generally ends in the Left Common Iliac Vein.

ILIAC VEINS, —For relations, etc., see 'Iliac Arteries,' p. 122.

Tributaries
- The Common Iliac Vein receives the Ilio-lumbar and Lateral and Middle Sacral Veins.
- ,, External and Internal Iliac Veins receive Branches corresponding to the Branches of the Arteries which they accompany.

The **Visceral Veins** *in the Pelvis* form a series of Plexuses from before backwards around or below the Viscera,

communicating
- *anteriorly* with the veins external to the Pelvis by the Dorsal Vein of the Penis.
- *above and behind* ,, ,, Portal Vein by the Superior Hæmorrhoidal Vein.
- *below* ,, ,, ,, ,, Int. Iliac Vein ,, direct branches.

PORTAL VEIN
- 3 inches long, commences by union of Superior Mesenteric and Splenic Vein, over Inf. Vena Cava, beneath Pancreas.
- passes up beneath Hepatic Duct and Hepatic Artery,—the former being to the right of the latter.
- divides in Transverse Fissure of Liver into right and left Branches for corresponding Lobes.

For Relations in root of Liver see 'Intercostal Arteries,' p. 118.

Relation of Veins to Pancreas
- Running from left to right *beneath* the Pancreas is the Splenic Vein,
- entering beneath its *lower border* are
  - the Inf. Mesenteric to the *left* on its way to join with the Splenic.
  - ,, Sup. ,, ,, *right* ,, ,, to form with Splenic the Portal [Vein.
- ,, ,, ,, *upper* ,, on the *left* side, are branches from the large end of the Stomach.
- emerging from ,, ,, ,, ,, *right* ,, is the Portal Vein.

See 'Arteries of Pancreas,' p. 149.

The Intercostal veins have complete valves; the Azygos veins have imperfect valves; the left Spermatic has one valve at its junction with the Renal; and the Inferior Vena Cava has an imperfect one at its point of entry into the Right Auricle. The other veins of the Thorax and Abdomen have no valves.

For Relations of **Femoral** and **Popliteal Veins** see 'Femoral' and 'Popliteal Arteries,' pp. 125 and 127.
The main vein crosses the Artery twice, lying first to its inner side, then behind it, then to its outer side, then (in Popliteal Space) crossing behind again, and lastly (at termination of Popliteal), lying at its inner side once more.

The **Saphena Veins** in their course correspond with the Saphenous Nerves (which see); they commence in a transverse arch on the Dorsum of the Foot.

THORACIC DUCT.

Course, etc.
- *Commences* in Abdomen opposite *first* Lumbar Vertebra, and *ends* in Neck opposite *last* Cervical Vertebra.
  Passes up *intermediately* through Aortic Opening in Diaphragm and through Posterior Mediastinum in Thorax.
- At its commencement (as the Receptaculum Chyli) it receives the Lumbar Lymphatics.
  ,, termination it opens into the outer angle of union of the Left Internal Jugular and Subclavian Veins.
- At its *lower end* it is largest, at its *upper* end it is also enlarged, *intermediately* it is narrowest or subdivided.

Relations
- *In Abdomen*, it lies *upon* Ant. Common Lig. of Vertebræ, *beneath* Aorta, *between* the Vena Azygos Major and Vena Azygos Minor.
- *In Thorax*
  - it lies at first *between* Aorta & Vena Azygos Major, crossing
    - opposite 6th Dorsal Vert. *over* the V. Azygos Min.
    - ,, 3rd ,, ,, *under* Arch of Aorta.
  - ,, ,, higher up ,, Œsophagus and Left Pleura.
- *In Neck* It curves outwards opposite 7th Cervical Vertebra
  - from *under* Carotid Sheath, resting *upon* Longus Colli,
  - *over* Subclavian Art. (3rd part) ,, ,, Scalenus Anticus.

Tributaries
- The Duct receives Lymph from all parts of the Body except the following:—
  - Right Side of Head and Neck,
  - ,, Upper Extremity,
  - Right Side of Thorax,
  - ,, ,, ,, Heart & Rt. Lung
  - — Post. and lateral parts of Sup. Surface of Liver.

The Lymphatics from these parts unite to form the **Right Lymphatic Duct**, which after a course of about half an inch at the Root of the Neck, opens into the outer angle of union of the Right Internal Jugular and Right Subclavian Veins.

NERVES.

GANGLIA (Branches, etc.)

- **Glosso-pharyngeal**
  - **Jugular Gangl.** —No Branches arise from it.
  - **Petrous Gangl.**
    - *forwards* —Jacobson's Nerve (see 'Tympanic Plexus").
    - *backwards* —Communicating Branch to Vagus (Ganglion of Root).
    - *downwards* — " " " Sympathetic (Superior Cervical Ganglion).
    - *outwards* — " " " Arnold's Nerve.
- **Pneumogastric**
  - **Gangl. of Root**
    - *outwards* —Arnold's Nerve.
    - *downwards* —Communicating Branch to Sympathetic (Sup. Cervical Ganglion).
    - *backwards* — " " " Spinal Accessory Nerve.
    - *forwards* — " " " Glosso-pharyngeal " .
  - **Gangl. of Trunk**
    - *behind*, 2 *Roots* — from Loop between 1st and 2nd Cervical Nerves. " Sympathetic (Superior Cervical Ganglion).
    - *in front*, 2 *Branches* — Pharyngeal Branch (to Pharyngeal Plexus). Superior Laryngeal Branch.
    - *above* — continuous with main trunk of Vagus. receiving Accessory Part of Spinal Accessory.
    - *below* — continuous with main trunk of Vagus.
- **Sympathetic—Sup. Cervical Ganglion**
  - *behind*, 4 *Roots* —from First, Second, Third and Fourth Cervical Nerves.
  - *in front*, 4 *Branches*
    - Communicating Branch to Hypoglossal and Vagus.
    - Nervi Molles (to External Carotid Artery).
    - Pharyngeal* (to Pharyngeal Plexus).
    - Superior Cardiac Nerve.
  - *above* — continuous with main trunk of Sympathetic. giving Communicating Branch to Petrous Gangl. and Gangl. of Root.
  - *below* — continuous with main trunk of Sympathetic.

In the communications above mentioned between the Pneumogastric, Hypoglossal, Sympathetic and Loop between 1st and 2nd Cervical Nerves, each Nerve communicates with the other three. Compare the Branches of the Petrous Ganglion and the Ganglion of the Root, and also those of the Ganglion of the Trunk and the Superior Cervical Ganglion as indicated above.

* The Laryngeal offset of the Sympathetic is generally blended with the Laryngeal of the Pneumogastric.

PLEXUSES (Branches, etc.)

- **Sympathetic**
  - **Cavernous Plexus** —*forwards*, **4** *Branches*
    - To join Third Cranial Nerve.
    - ,, Fourth ,, ,,
    - ,, Fifth ,, ,, (Ophthalmic Div.).
    - ,, Lenticular Ganglion.
  - **Carotid Plexus** —*radiately*, **4** *Branches*
    - ,, Fifth Cranial Nerve (Gasserian Ganglion).
    - ,, Sixth ,, ,,
    - ,, Great Superficial Petrosal Nerve to form Vidian Nerve.
    - To supply Dura-Mater.
  - *Terminal Branches*
    - *forwards*, **2** *Branches*
      - ,, Eye-ball.
      - ,, Ophthalmic Artery.
    - *upwards*, **2** *Branches*
      - ,, Pia Mater.
      - ,, Cerebral Arteries.

For Pharyngeal Plexus, etc., see Diagram **B**.

DEEP NERVES OF NECK.— DIAGRAM A.

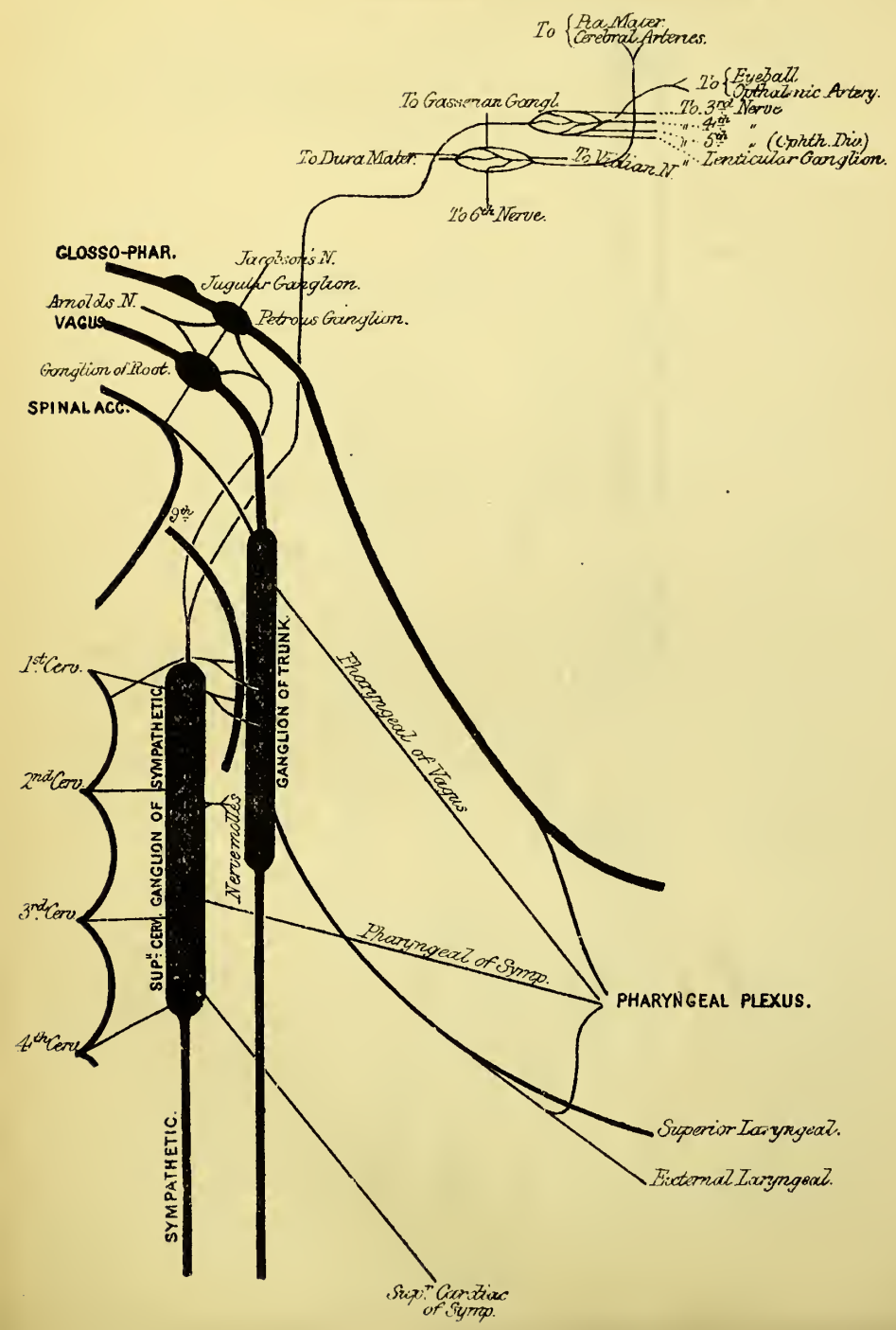

DEEP NERVES OF NECK. — DIAGRAM B.

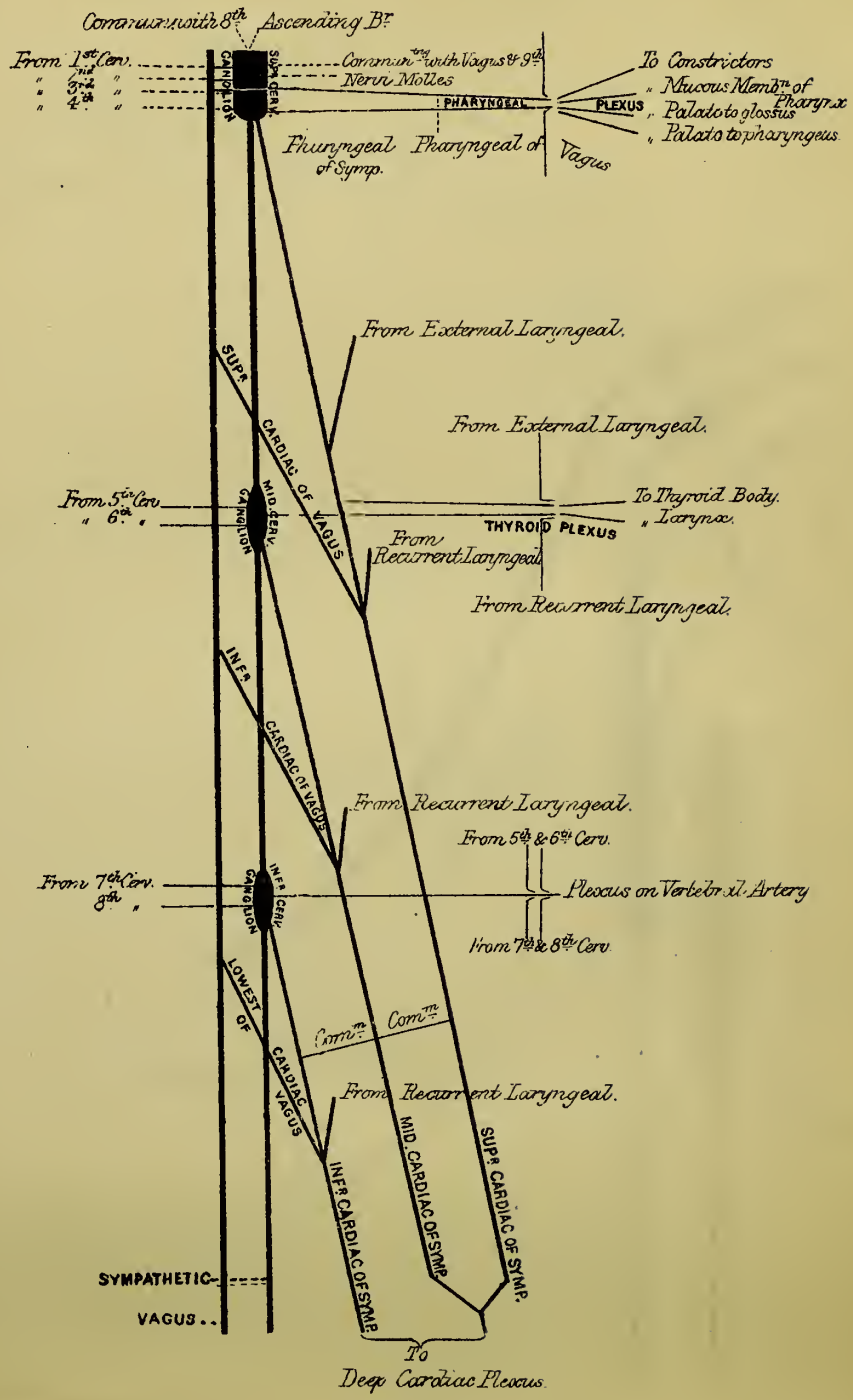

RIGHT SIDE.

Superior Cervical Ganglion, see Diagram A.

Middle ,, ,,
- *receives* from 5th Cervical Nerve.
  ,, 6th ,, ,,
- *gives* to Thyroid Plexus, along Inferior Thyroid Artery.
  Middle Cardiac Nerve.

Inferior ,, ,,
- *receives* from 7th Cervical Nerve.
  ,, 8th ,, ,,
- *gives* to Vertebral Plexus on Vertebral Artery.*
  Inferior Cardiac Nerve.

Compare the three Ganglia. Each Ganglion gives off a Cardiac Nerve and a Branch to a Plexus.
Compare the Thyroid and Pharyngeal Plexuses as indicated in the Diagram.

Superior Cardiac Branch of Sympathetic
- *receives* **4** *Branches*
  - from External Laryngeal.
  - ,, Superior Cardiac of Vagus.
  - ,, Recurrent Laryngeal.
  - ,, Middle Cardiac of Sympathetic.
- *gives* to Thyroid Plexus.

Middle ,, ,, ,,
- *receives* **3** *Branches*
  - from Inferior Cardiac of Vagus.
  - ,, Recurrent Laryngeal.
  - ,, Inferior Cardiac of Sympathetic.
- *gives* Branch Communicating with Superior Cardiac of Sympathetic.

Inferior ,, ,, ,,
- *receives* **2** *Branches*
  - from Cardiac of Vagus in Thorax.
  - ,, Recurrent Laryngeal.
- *gives* Branch Communicating with Middle Cardiac of Sympathetic.

LEFT SIDE.

The arrangement is the same as on the right side, except that the Inferior Cardiac of the Vagus does not join the Middle Cardiac of the Sympathetic, but enters the Superficial Cardiac Plexus separately, as does also the Superior Cardiac of the Sympathetic, and that the Middle Cardiac of the Sympathetic joins with the Inferior of the same to enter the Deep Cardiac Plexus.
The lowest Cardiac Branches of the Vagus are absent.

* The Plexus on the Vertebral Artery is not to be taken as if analogous to the Thyroid and Pharyngeal Plexuses, although it is represented in a similar form in the Diagram.

A. DEEP PLEXUS.

The Deep Plexus is divided into a Right and a Left Part.

The **Right Part** *receives* **2** *Trunks*:—

The *Upper* comprising **4** Nerves:
- Right Superior Cardiac of Sympathetic.
- ,, Middle ,, ,, ,,
- ,, Superior ,, ,, Vagus.
- ,, Inferior ,, ,, ,,

The *Lower* comprising **2** Nerves:
- From Right Recurrent and adjoining part of Vagus.
- The Inferior Cardiac of Sympathetic.

The **Left Part** also *receives* **2** *Trunks*:—

The *Upper* comprising **3** Nerves:
- Left Middle Cardiac of Sympathetic
- ,, Inferior ,, ,, ,,
- ,, Superior ,, ,, Vagus

The *Lower* comprising **1** Nerve:
- From Left Recurrent Laryngeal only.

The **Right Part** *gives* **4** Branches:
- To Right Anterior Pulmonary Plexus.
- ,, ,, Auricle.
- ,, ,, or Anterior Coronary Plexus.
- ,, Posterior Coronary Plexus.

The **Left Part** *gives* **4** Branches:
- To Left Anterior Pulmonary Plexus.
- ,, ,, Auricle.
- ,, Superficial Cardiac Plexus.
- ,, Posterior Coronary Plexus.

Notice the numerical composition of the Roots, and the analogous distribution of the Branches.

B. SUPERFICIAL PLEXUS.

Receives **2** Roots:
- Left Inferior Cardiac of Vagus
- ,, Superior ,, ,, Sympathetic

} *above*, and also a special offset from the Deep Plexus *below*.

Gives **2** Branches:
- To ,, Anterior Pulmonary Plexus.
- ,, Right or ,, Coronary ,, the latter receiving ,, ,, ,, ,, .

All the Cardiac Nerves end in the Deep Plexus, except the Left Superior or Superficial Cardiac of the Sympathetic and the Left Inferior Cardiac of the Vagus.

CARDIAC PLEXUS.

A

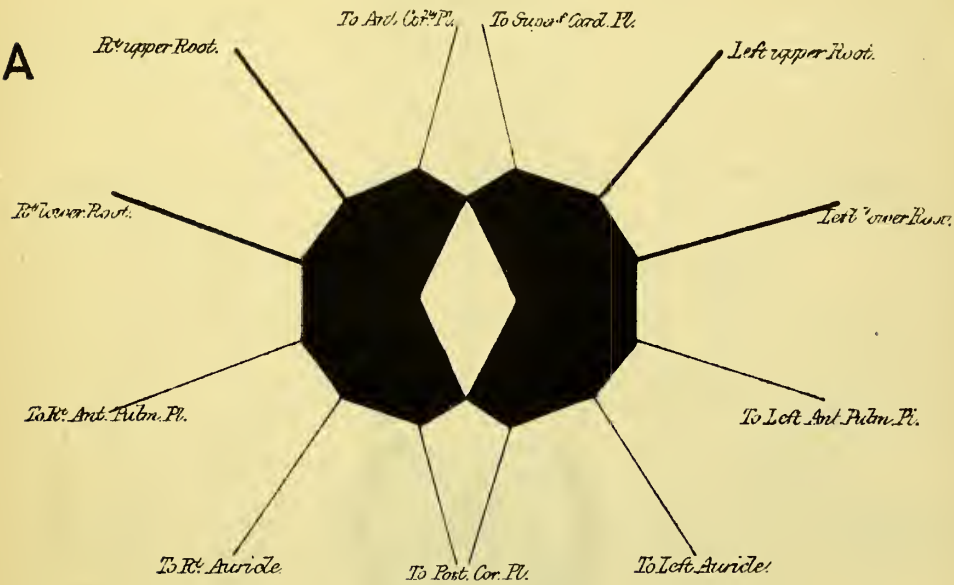

B

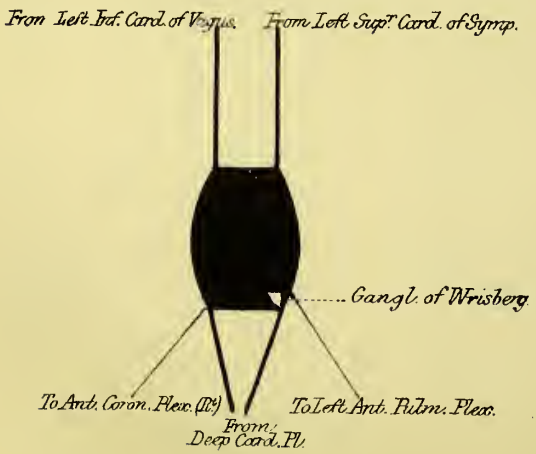

SOLAR PLEXUS.

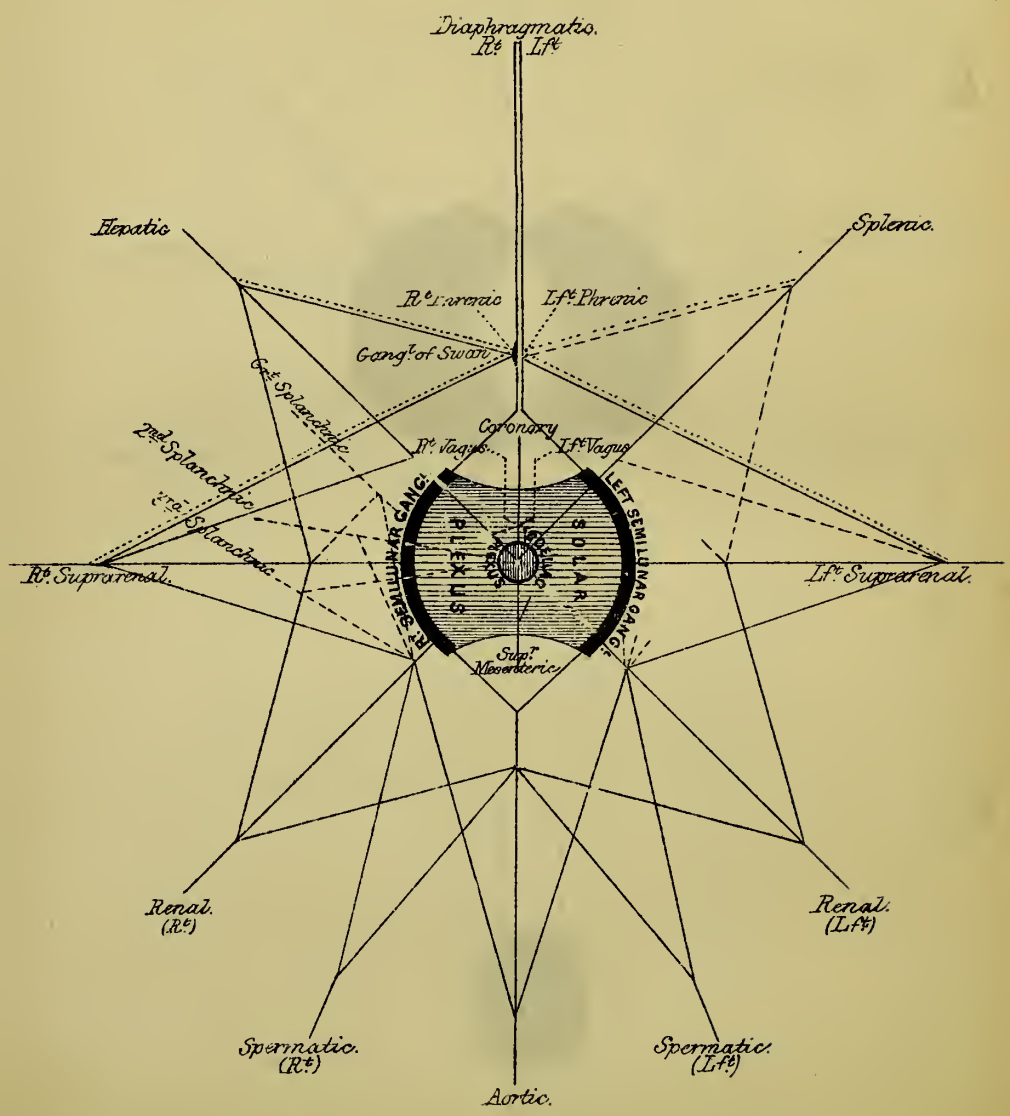

The Central shaded part of the Diagram represents the Right and Left Semilunar Ganglia with the intervening Solar Plexus, and the small circle in the centre represents the Cœliac Plexus. The radiating lines represent the main offsets from the central Plexuses, the other lines the communications of those offsets; the interrupted lines show where branches are wanting; the dotted lines mark out the special nerves joining the Plexus.

It will be noticed that the main offsets correspond to lines drawn so as to bisect the sides and angles of an imaginary square described about the figure representing the Plexus, and that the chief communications may be shown by triangles erected upon the sides and over the angles of such a square. The lines converging on the Hepatic, Splenic and Renal lines are sides of the triangles erected on the sides of the square.

BRANCHES.

All the *radiating branches*, except the Hepatic, join one or other of the Semilunar Ganglia.

The **Cœliac Plexus** gives off the Coronary, Splenic, Hepatic and part of the Superior Mesenteric Plexuses. The **Coronary** has no other origin. The **Splenic** joins only the Left Semilunar Ganglion, being itself joined by the Right Vagus. The **Superior Mesenteric** receives a root from the left side of the Solar Plexus.

The **Hepatic**	*receives from*	the	Diaphragmatic and Rt. Suprarenal,	and *gives to*	the Right Suprarenal.
The **Right Suprarenal**	,,	,,	,, Rt. Renal, Hepatic and Diaphrag.	,, ,,	,, Right Renal and Hepatic.
,, **Left Suprarenal**	,,	,,	,, Left Renal and Diaphragmatic	,, ,,	,, Left Renal.
,, **Renal** (Right or Left)	,,	,,	,, Suprarenal and Aortic	,, ,,	both, and to the Spermatic.
,, **Spermatic** (,, ,, ,,)	,,	,,	,, Aortic and Renal.		
,, **Aortic**	,,	,,	,, Renal (right and left)	,, ,,	both Renals and both Spermatics.
,, **Diaphragmatic**	gives to the Hepatic and to both Suprarenals.				

ROOTS.

The **Phrenic Nerves** join the Diaphragmatic Plexus; the **Right** through the Ganglion of Swan, sending on filaments to the Right Suprarenal and Hepatic; the **Left** sending only to the Left Suprarenal.

The **Right Vagus** joins the Cœliac Plexus (*left* side) and Splenic; the **Left Vagus** joins the Hepatic.

The **Great**	**Splanchnic**	ends in the	Semilunar Ganglion,	and joins the	Suprarenal and Renal.
The **Small** (2nd)	,,	,, ,,	Cœliac Plexus,	,, ,, ,,	Renal.
The **Smallest** (3rd)	,,	,, ,,	Renal ,,	,, ,, ,,	Cœliac.

N.B.—Primary or direct communications only are represented.

- **Hypogastric Plexus**
  - *Roots* from
    - Aortic Plexus.
    - Lumbar Ganglia.
    - Sacral „ (1st and 2nd).
  - *Branches*
    - Uterine Plexus (Fibres chiefly *sympathetic*).
    - Root of Right Pelvic Plexus.
    - „ Left „ „
- **Pelvic Plexus**
  - *Roots* from
    - Hypogastric Plexus.
    - 3rd, 4th, 1st and 2nd Sacral Nerves (especially 3rd).
    - Sacral Ganglia.
  - *Branches*
    - in *Male*
      - Inferior Hæmorrhoidal Plexus (Fibres *mixed*).
      - Prostatic Plexus, continued to
        - Large Cavernous Nerve
        - Small „ Nerves
        - (Fibres chiefly *spinal*).
      - Vesical Plexus „ „
        - Vas deferens
        - Vesicula seminalis
        - („ „ „).
    - in *Female*
      - Inferior Hæmorrhoidal Plexus (Fibres *mixed*).
      - Vaginal Plexus (Fibres chiefly *spinal*).
      - Vesical „ „ „ „

In the Diagram the Roots are represented by heavy lines, the Branches by light ones.

HYPOGASTRIC AND PELVIC PLEXUSES.

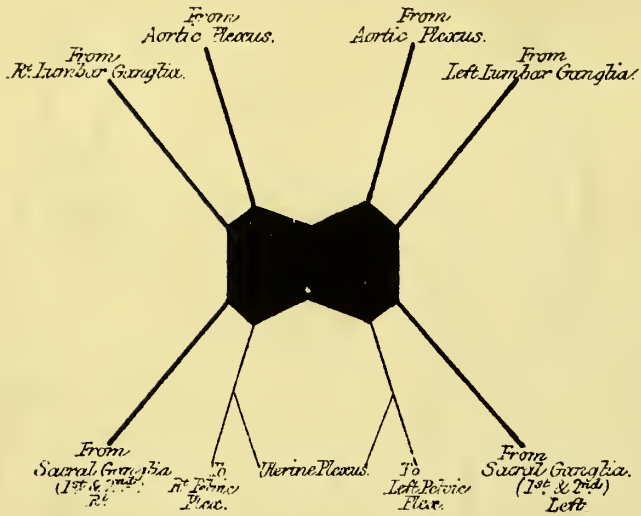

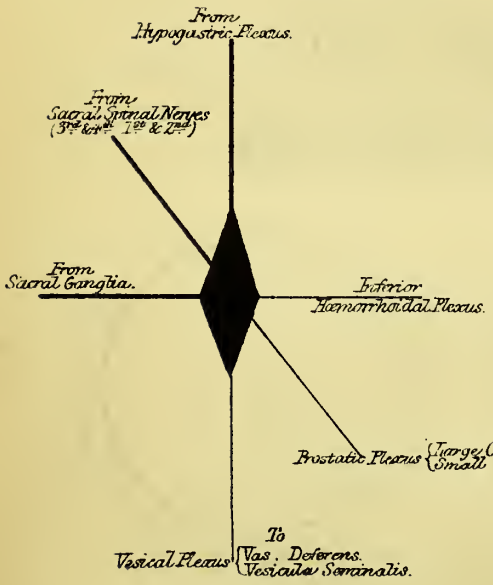

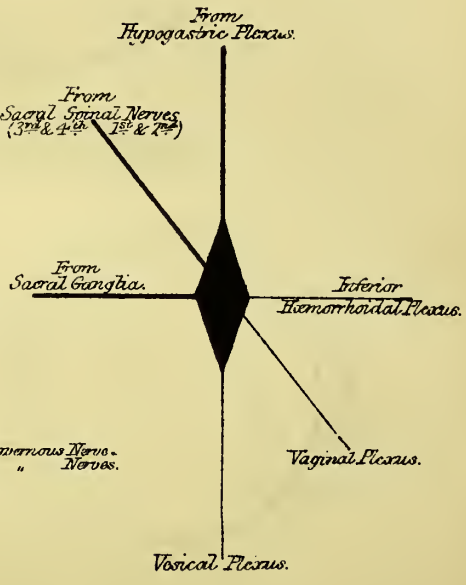

CUTANEOUS NERVES OF HEAD AND NECK.

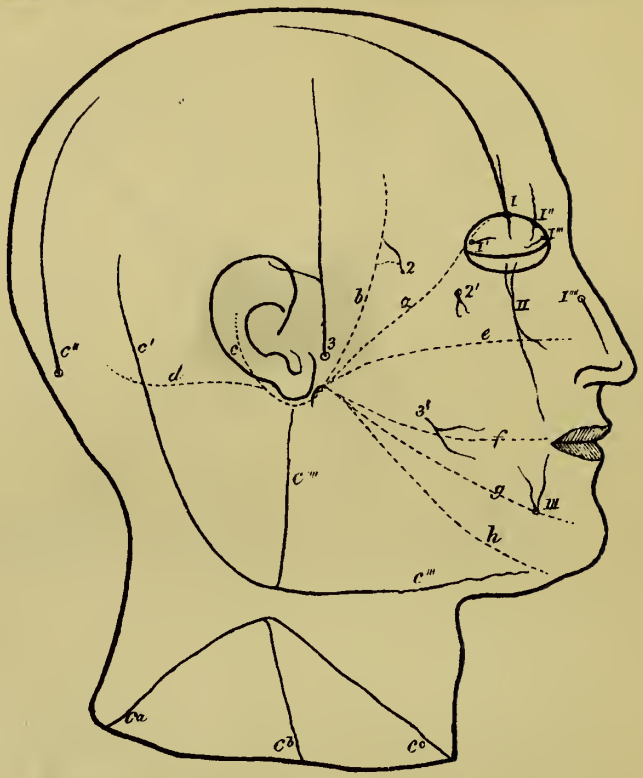

CUTANEOUS NERVES OF ARM.

RIGHT ARM.

Section seen from below.

RIGHT FORE-ARM.

Section seen from below.

On the Scalp Branches of the Facial Nerve alternate with Branches of the 1st, 2nd and 3rd Divs. of the 5th Nerve successively.
On the Face ,, ,, ,, ,, ,, and decussate with Branches of the same.

In the Diagram the Branches of the Facial Nerve are represented by dotted lines, and those of other Nerves by continuous lines.

ON THE SCALP there are from *before backwards* the following Nerves :—

Supraorbital (1) from the *First Division* of the **5th** Nerve.
Malar Branches (*a*) of **Facial Nerve.**
Temporo-malar (Temporal Branch) (*2*) from the *Second Division* of the **5th** Nerve.
Temporal Branches (*b*) of **Facial Nerve.**
Auriculo-temporal (*3*) from the *Third Division* of the **5th** Nerve.
Posterior Auricular (Auricular Branch) (*c*) of **Facial Nerve.**
Small Occipital (*c'*) from *Anterior* Branch of **2nd** Cervical Nerve.
Posterior Auricular (Occipital Branch) (*d*) of **Facial Nerve.**
Great Occipital (*c''*) from *Posterior* Branch of **2nd** Cervical Nerve.

ON THE FACE there are from *above downwards* the following Nerves :—

Malar (*a*)	of the *Facial* and	**Supraorbital**	Branches, etc. (**I**) of the *First Division* of the *Fifth.*
Infraorbital (*e*)	,, ,, ,,	**Infraorbital**	Branch (**II**) ,, *Second* ,, ,, ,,
Supramaxillary (*f*) with **Buccal** Branch (*g*)	,, ,, ,,	**Labial (III)** and **Buccal** (*3'*)	Branches ,, *Third* ,, ,, ,,

BELOW THE INFERIOR MAXILLA there are from *above downwards* the following Nerves :—

Inframaxillary of the *Facial* (*h*) with the first of the following Nerves, viz., the **Superficial Cervical** (*c'''*).

The former ramifies chiefly under the Platysma, the latter over it.

The *three* **Superficial Ascending Branches** of the Cervical Plexus, viz. :—

the *anterior* —the **Superficial Cervical** (*c'''*) passing transversely toward the most *anterior* branch (*h*) of the *Facial.*
,, *posterior* — ,, **Small Occipital** (*c'*) ,, vertically ,, ,, ,, *posterior* ,, (*d*) ,, ,,
,, *intermediate*— ,, **Great Auricular** (*c''''*) ,, obliquely ,, ,, *main trunk* ,, ,,

The *three* **Superficial Descending Branches** of the Cervical Plexus, viz. :—

the *anterior* —the **Sternal** Branch (c^c) (the shortest) passing down and in towards Sternum close above Clavicle.
,, *posterior* — ,, **Acromial** (c^a) (,, longest) ,, down and out over Deltoid across Acromion Process.
,, *intermediate*— ,, **Clavicular** (c^b) (of mid. size) ,, downwards ,, Pectoralis Major across Clavicle.

NERVES OF EYELIDS.

The **Upper Eyelid** is supplied by *four sensory* Nerves, viz. :—

Supraorbital (1)	*above*	Lachrymal (1′)	on *outer* side.
Supratrochlear (1″)		Infratrochlear (1‴)	„ *inner* „

The **Lower Eyelid** is supplied by *one sensory* Nerve only, viz. :—
Infraorbital (II)—(generally by a double twig).

Both Eyelids receive branches from the Facial Nerve (*motor*).

The *Nasal* Branch (1⁗) of the *First* Division of the Fifth ramifies on the Nose below the **Inner Canthus** of the Eyelids.
„ *Malar* „ (2′) „ *Second* „ „ „ over „ Malar Bone „ „ **Outer Canthus** „ „

Compare the Nerves of the Eyelids with the Arteries (See p. 147).

NERVES OF PINNA OF EAR.

On *External* surface (2)
- Great Auricular over the Lobule and lower part of Concha.
- Auriculo-temporal giving
  - one branch below External Meatus.
  - „ „ above „ „ and to Tragus.
  - „ „ to upper part of Pinna and Skin above it.

On *Internal* surface (4)
- Small Occipital above, —Great Auricular below.
- Auricular Branch of Vagus over Concha,—Posterior Auricular of Facial.

CUTANEOUS NERVES ON POSTERIOR ASPECT OF BODY.

OVER SCALP —see Diagram of Cutaneous Nerves of Head and Neck.

OVER BACK

1st **Cervical** (Suboccipital)	by *undivided*	Posterior Division	supplying Muscles of	Suboccipital Triangle.
2nd „ (Great Occipital)	„ *internal* branch	of „ „ „	Skin of	Scalp.
3rd, 4th and 5th Cervical	„ „ branches	„ „ „ „	„ „	Back of Neck.
1st to 6th **Dorsal**	„ „ „	„ „ „ „	„ „	Back.
7th „ 12th „	„ *external* „	„ „ „ „	„ „	„
1st „ 3rd **Lumbar**	„ „ „	„ „ „ „	„ „	Back & Gluteal Region.
1st „ 3rd **Sacral**	„ „ „	„ „ „ „	„ „	Gluteal Region.

The Nerves and Branches not indicated above supply the deeper structures.
The *lateral aspect* of the Back is supplied by the posterior twigs of the Lateral Branches of the Intercostal Nerves.

The *three* Cervical below the Second and the upper *six* Dorsal supply the Skin by their *Internal* Branches, the lower *six* Dorsal, upper *three* Lumbar and upper *three* Sacral by their External Branches.

OVER ARM	Acromial Branches of the **Cervical Plexus**	(6)	*externally* one below another.
	Posterior Cutaneous Branch of **Circumflex**	(7)	
	Posterior External Cutaneous of **Musculo-spiral**	(8)	
	Internal Cutaneous Branch of **Musculo-spiral**	(9)	*internally* ,, ,, ,,
	Intercosto-humeral	(10)	
	Small Internal Cutaneous (**Nerve of Wrisberg**)	(11)	
OVER FOREARM	Posterior Division of **Musculo-cutaneous**	(12)	on *outer* side.
	Posterior External Cutaneous of **Musculo-spiral**	(8)	*intermediately.*
	Posterior Division of **Internal Cutaneous**	(13)	on *inner* side.
OVER HAND	**Radial** to $3\frac{1}{2}$ outer Digits	(14)	on *outer* side.
	Ulnar (Dorsal branch) to $1\frac{1}{2}$ inner Digits	(15)	,, *inner* ,,
OVER GLUTEAL REGION	**Last Dorsal** (lateral branch)	(17)	*long,* at front of Crest.
	Ilio-hypogastric (,, ,,)	(16)	*short,* at middle ,, ,,
	Lumbar, 1st to 3rd (posterior divisions)		*long,* at back ,, ,,
	Sacral 1st (posterior division)		*shortest,* close to Posterior Superior Spine of Ilium.
	Sacral 2nd (,, ,,)		*long,* ,, ,, Coccyx.
	Sacral 3rd (,, ,,)		*short,* intermediately.
	Branches of **External Cutaneous**	(18)	round anterior border of Region.
	,, ,, **Small Sciatic**	(19)	,, posterior ,, ,, ,,
OVER THIGH	**External Cutaneous**	(20)	on *outer* side.
	Small Sciatic	(19)	*intermediately.*
	Internal Cutaneous	(21)	on *inner* side.
OVER LEG	Cutaneous of **External Popliteal**	(22)	on *outer* side.
	External Saphenous	(23)	*intermediately.*
	Internal Cutaneous (Posterior Division)	(24)	on *inner* side.
OVER SOLE OF FOOT	**Calcaneo-plantar**	(25)	*posteriorly* over Heel.
	Internal Plantar		*anteriorly* to $3\frac{1}{2}$ *inner* Toes.
	External Plantar		,, ,, $1\frac{1}{2}$ *outer* ,,

Notice the arrangement of the Nerves in sets of three, and compare each set as given above with the corresponding set on pp. 168 and 169.

OVER HEAD AND NECK—see Diagram of Cutaneous Nerves of Head and Neck.

OVER TRUNK

- **Intercostals**
  - **12 Ant. Cutaneous** Nerves (1–12)—*terminal* Branches of the Intercostals—*emerging* close to mid-line beside Sternum or through Rectus Abdominis; *diminishing* in size from above downwards, the 2nd being the largest.
  - **10 Lateral Cutaneous** Nerves (Ant. Brs.) (3′–12′)—*lateral* offsets of lower 10 Intercostals—*emerging* between digitations of Serratus Magnus or External Oblique; *increasing* in size from above downwards.
- There is no Lateral Branch from the First Intercostal; that of the 2nd, the largest of the series, is undivided and passes to the Arm as the Intercosto-humeral. The Lateral Branch of the *last* (12th Dorsal) is also undivided, and is the *first* from before backwards of the Nerves crossing the Crest of the Ilium.
- **Ilio-hypogastric** (24) emerging *above* the External Abdominal Ring, turning *upwards*.
- **Ilio-inguinal** (25) ,, *through* ,, ,, ,, ,, ,, *downwards*.

OVER ARM

- Acromial Branches of **Cervical Plexus** (13)
- Anterior Cutaneous Branch of **Circumflex** (14)
- Anterior External Cutaneous Branch of **Musculo-spiral** (15)

  } *externally*, one below another.

- Bicipital Branch of **Internal-cutaneous** (16)
- Anterior Division ,, ,, ,, ,, (17)
- Posterior ,, ,, ,, ,, (18)

  } *internally*, side by side.

OVER FOREARM

- Anterior Division of **Musculo-cutaneous** (19) on *outer* side.
- ,, ,, ,, **Internal-cutaneous** (17) ,, *inner* ,,
- Cutaneous Branch of **Median** (20) *intermediately* below.

OVER HAND

- Digital Branches of **Median** (22) to 3½ *outer* Digits.
- ,, ,, ,, **Ulnar** (23) ,, 1½ *inner* ,,
- Cutaneous Branch ,, ,, (21) ,, Palm *superiorly*.

OVER THIGH

- Posterior Division of **External Cutaneous** (27) on *outer* side
- **Ilio-inguinal** (25) ,, *inner* ,,
- Crural Branch of **Genito-crural** (26) *intermediately*

  } over Scarpa's Triangle.

- Anterior Division of **External Cutaneous** (28) on *outer* side
- ,, ,, ,, **Internal** ,, (30) ,, *inner* ,,
- **Middle Cutaneous** (29) *intermediately*

  } over lower ⅔rds of Thigh.

CUTANEOUS NERVES.— POSTERIOR ASPECT.

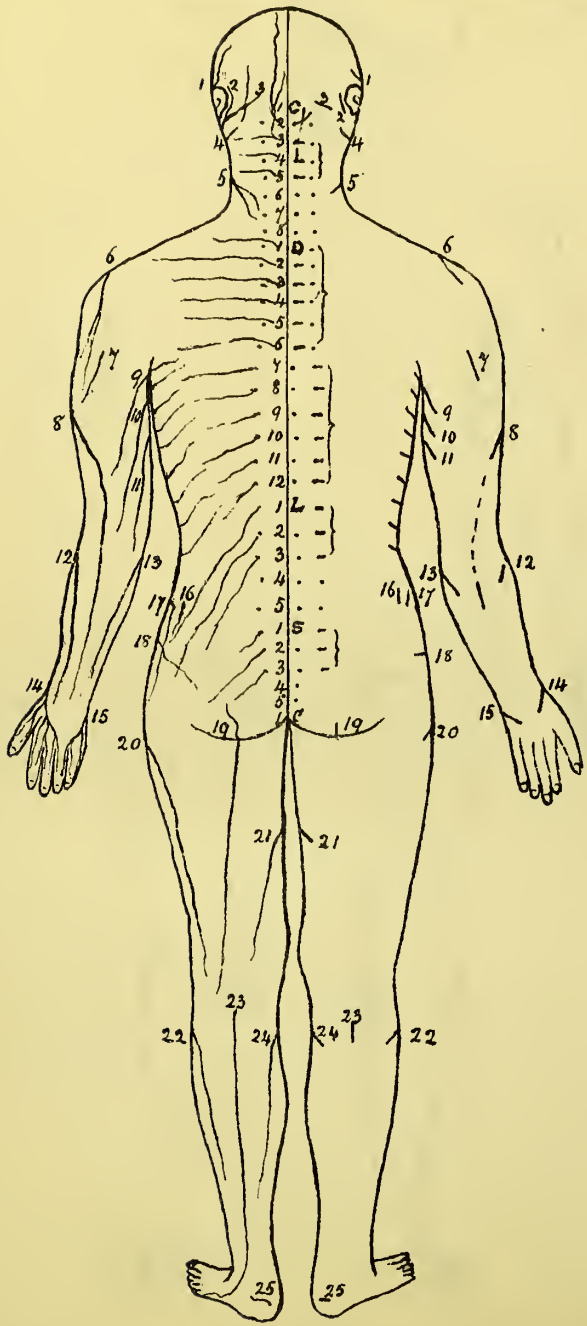

CUTANEOUS NERVES.—ANTERIOR ASPECT.

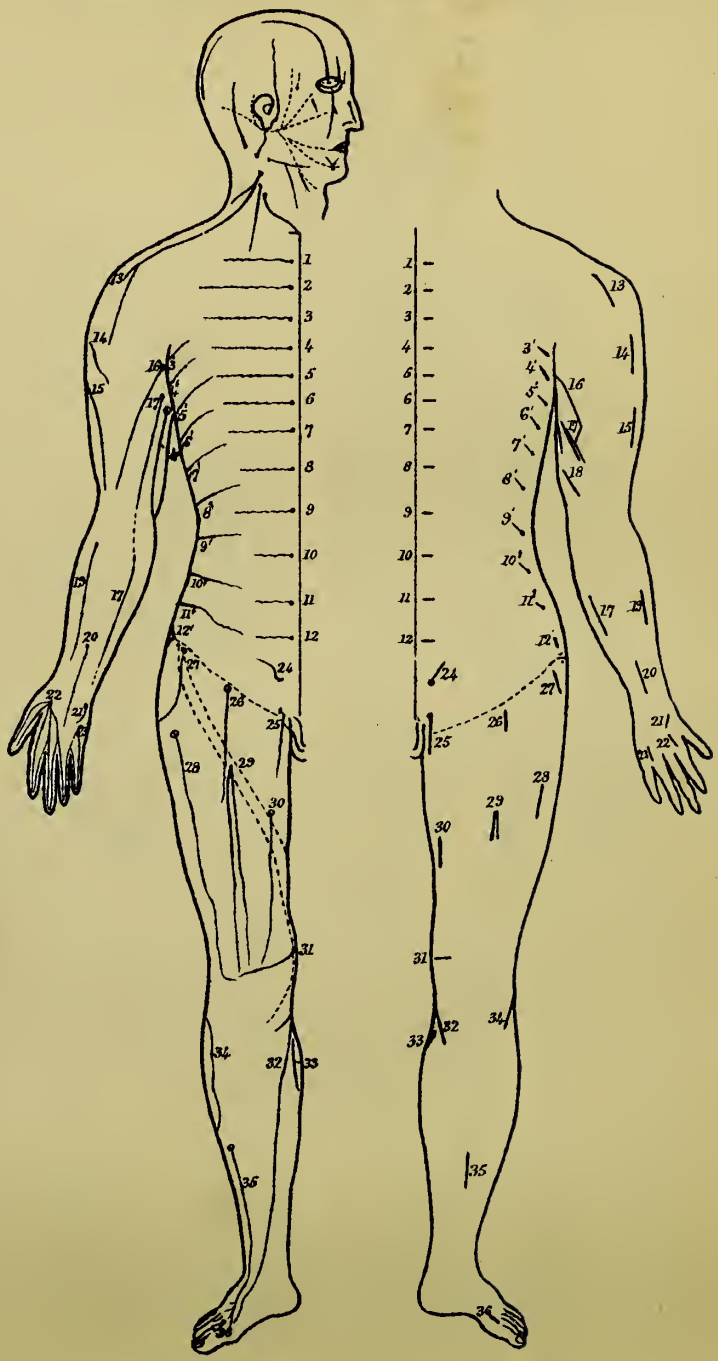

TO INNER SIDE OF KNEE	Patellar Branch of **Internal Saphenous**	(31)	*above* Patella.
	Internal Saphenous (main trunk)	(32)	*below* „ side by side.
	Posterior Division of **Internal Cutaneous**	(33)	
OVER LEG	Cutaneous of **External Popliteal**	(34)	on *outer* side above.
	Internal Saphenous	(32)	„ *inner* „
	Musculo-cutaneous	(35)	*intermediately* below.
OVER FOOT (on Dorsum)	Terminal Branches of **Anterior Tibial**	(36).	
	„ „ „ **Musculo-cutaneous.**		
	„ Branch „ **External Saphenous.**		

Note that the Sartorius (represented by parallel interrupted lines in the Diagram) is in relation with six Superficial Nerves, of which *two* (27 and 30) appear *over* its upper border, and *two* (29 and 31) *pierce* it, whilst the other *two* (32 and 33) lie *beneath* it in the greater part of its length and emerge behind the posterior border of its tendon. The Nerves of the first pair alternate with those of the second.

Note also that the two parts of the Internal Saphenous Nerve appear between the two parts of the Internal Cutaneous (31 and 32 between 30 and 33).

Note in regard to the two Saphenous Nerves (Internal and External) that the Nerve which arises *in front* and *higher* up than the other (viz., the Internal) passes *in front* of the Internal Malleolus and ends *higher* up than the other on the Foot (viz., about the ball of the Great Toe), whereas the Nerve which arises *behind* and *lower* down (viz., the External) passes *behind* the External Malleolus and ends *lower* down on the Foot (viz. on the outer side of the Little Toe).

Note in regard to the Nerves on the Dorsum of the Foot that the Branches of the Musculo-cutaneous alternate with those of the other Nerves, thus from within outwards there are first the Branch of the Musculo-cutaneous to the inner side of the Great Toe, next the Branch of the Anterior Tibial to the First Interosseous Space, then Branches of the Musculo-cutaneous to the other spaces, and lastly the Branch of the External Saphenous to the outer side of the Little Toe.

A. INTERCOSTAL NERVES OF WALL OF THORAX (Upper *Six*).

The **Intercostal Nerve** lies at first between the Pleura and the External Intercostal Muscle,
then ,, ,, Internal Intercostal Muscle ,, ,, ,, ,,
then ,, ,, ,, ,, ,, ,, Pleura,
lastly, piercing the Internal Intercostal and the Pectoralis Major close to the Sternum, it ends as an
Anterior Cutaneous Nerve of the Thorax.

Halfway between the Spine and the Sternum it gives off through the External Intercostal Muscle a
Lateral Cutaneous Nerve of the Thorax, which on becoming superficial, divides at once into an *Anterior* and a *Posterior* Branch.

The Skin between the end of the Posterior Branch and the Spine is supplied by the Posterior Primary Division of the corresponding Intervertebral Nerve.

The First Intercostal has no Lateral Branch, the *Second* has only the posterior division of one.

B. THE INTERCOSTAL NERVES extending into the WALL OF THE ABDOMEN (Lower *Six*).

These Nerves exactly resemble those higher up whilst they lie between the Ribs, and like them give off **Lateral Cutaneous Branches** which are similarly distributed. On reaching the Cartilages they pierce the Internal Intercostal, and thence run forward between the Internal Oblique and Transversalis till they reach the Rectus. This they perforate, and appear on the surface as **Anterior Cutaneous Nerves.**

The Lateral Branch of the last is single, see 'Nerves of Posterior Aspect of Body.

C. ILIO-HYPOGASTRIC AND ILIO-INGUINAL NERVES.

Ilio-hypogastric
- within the Abdominal Cavity lies higher than the Ilio-inguinal Nerve and crosses the Quadratus Lumborum only.
- pierces the Transversalis near the *back* of the Iliac *Crest*, the Int. Oblique near the *front* of the Iliac *Crest* and the External Oblique *above* the Pubic *Crest*, turning *upwards* under the Skin.
- half-way along Iliac Crest gives off the Lateral Branch through both Obliques to Gluteal Region.

Ilio-Inguinal
- within the Abdominal Cavity lies lower than the Ilio-hypogastric N. and crosses *both* the Quad. Lumbor. and Iliacus.
- pierces the Transversalis near *outer* end of Poupart's *Ligament*, the Int. Oblique opposite *middle* of *Ligament*, and the Ext. Oblique (through Ext. Abd. Ring) over the *inner* end of the *Lig.* turning *downwards* under Skin.
- near the Ant. Sup. Spine of Ilium gives a branch to join Ilio-hypogastric and lower down Branches to Int. Oblique.

Note that the Ilio-hypogastric Nerve pierces the three broad Muscles at points in relation with the Iliac and Pubic Crests, whereas the Ilio-inguinal pierces them at points in relation with Poupart's Ligament.

INTERCOSTAL NERVES ETC.

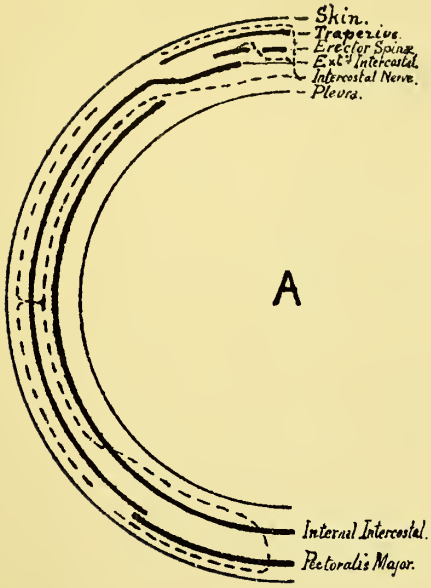

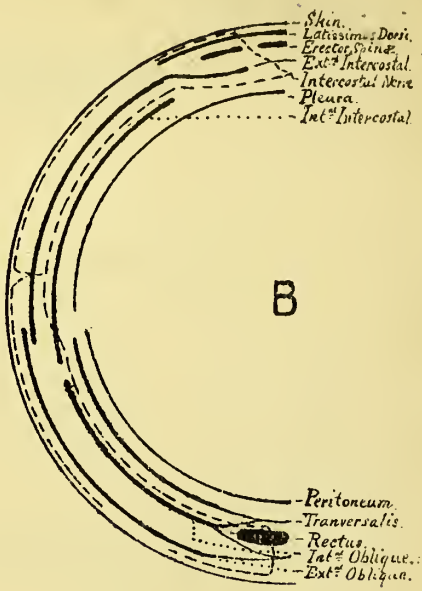

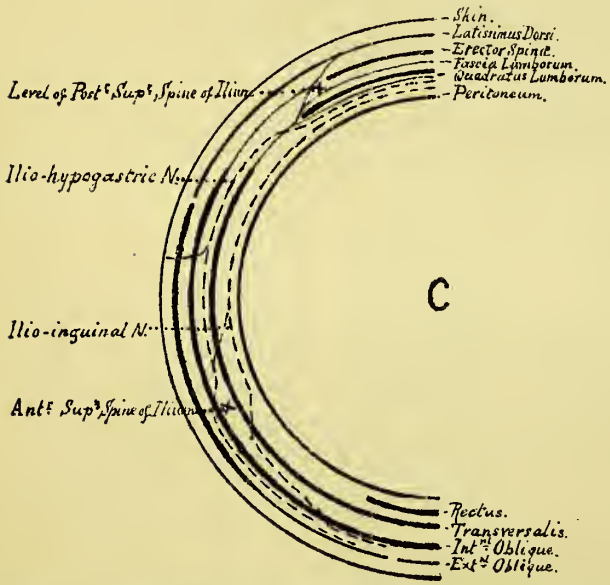

A. *Intercostal Nerve of Thoracic Wall.* – B. *Intercostal Nerve of Abdominal Wall.* – C. { *Ilio-hypogastric Nerve.* / *Ilio-inguinal Nerve.*

NERVES OF ORBIT.

Order in outer wall of Cavernous Sinus.



Order in Sphenoidal Foramen.

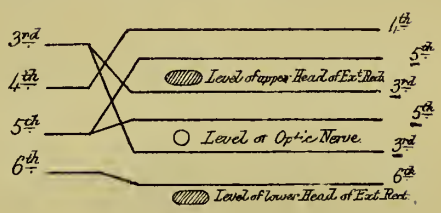

Order in Orbit.—(Gross Section of Rt. Orbit looking forwards.)

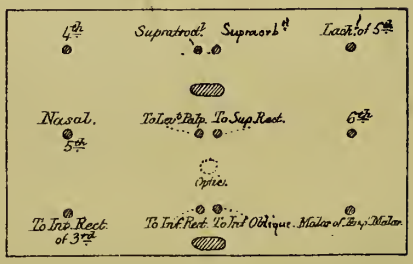

SURROUNDING THE ARM are the following Nerves :—

Bicipital Branch of **Internal Cutaneous**	—	(1)	—	superficial to Biceps	in *mid-line* anteriorly.
Anterior Division „ „ „	—	(2)	—	by side of „	*internally.*
Posterior „ „ „ „	—	(3)	—	„ „ „	*in front of* Internal Intermuscular Septum.
Small Internal Cutaneous (**N. of Wrisberg**)	—	(4)	—	„ „ Triceps	*behind* „ „ „
Intercosto-humeral	—	(5)	—	„ „ „	*internally.*
Internal Cutaneous of **Musculo-spiral**	—	(6)	—	superficial to „	*in mid-line* posteriorly.
Circumflex — Anterior Division	—	(7)	—	by side of Biceps	*externally.*
Circumflex — Posterior „	—	(10)	—	„ „ Triceps	„
External Cutaneous of **Musculo-spiral** — Anterior Branch	—	(8)	—	„ „ Biceps	*in front of* External Intermuscular Septum.
External Cutaneous of **Musculo-spiral** — Posterior „	—	(9)	—	„ „ Triceps	*behind* „ „ „

(Acromial Branches of **Cervical Plexus** descend over the upper part of the Deltoid.)

SURROUNDING THE FOREARM are the following Nerves :—

Cutaneous Branch of **Median**	—	in *mid-line*	*in front*	below.
Posterior External Cutan. of **Musculo-spiral**	—	„ „ „	*behind.*	
Internal Cutaneous — Anterior Division	—	on *inner* side	*anteriorly.*	
Internal Cutaneous — Posterior „	—	„ „ „	*posteriorly.*	
Musculo-Cutaneous (Ext. Cutan.) — Anterior „	—	„ *outer* „	*anteriorly.*	
Musculo-Cutaneous (Ext. Cutan.) — Posterior „	—	„ „ „	*posteriorly.*	

NERVES OF ORBIT.

Note in explanation of Diagram—

In the outer wall of the Cavernous Sinus the Nerves are in their numerical order from above down.

In the Sphenoidal Fissure the **4**th is highest, and the **6**th lowest, whilst intermediately the upper and lower branches of the Ophthalmic Division of the **5**th and the **3**rd alternate.

In the Orbit there are three *single* Nerves laterally one above another, and three *double* Nerves intermediately one above another.

Note the relation of the Nerves to the Heads of the External Rectus and to the Optic Nerve.

SUPERIOR MAXILLARY NERVE.—BRANCHES.

- *Downwards* to *Mouth*
  - **Spheno-palatine**
    - *Anterior* / *Posterior* — Branches — through Meckel's Ganglion to Palatine Nerves, forming Sensory Root of Ganglion.
  - **Posterior Dental** (Alveolar)
    - *Anterior* — Branch — to supply Gums and ,, ,, Buccinator Muscle.
    - *Posterior* — ,, — ,, join the Anterior Dental Nerve above the Teeth and ,, supply the Molar Teeth.
- *Forwards* to *Orbit*
  - **Infraorbital**
    - *Anterior Dental*
      - *Ant.* Branch — ,, ,, ,, Mucous Membrane over Inferior Turbinated Bone. ,, ,, ,, Incisor and Canine Teeth.
      - *Post.* ,, — ,, join the Posterior Dental Nerve. ,, supply the Bicuspid Teeth.
    - *Facial* Branch
      - *Sup.* Branches. — Palpebral Branch, to supply parts in Lower Eyelid. Nasal ,, ,, ,, on side of Nose.
      - *Inf.* ,, — Labial ,, ,, ,, of Upper Lip. Branch to communicate with the Infraorbital Branch of the Facial.
  - **Orbital**
    - *Temporal* Branch — ,, ,, ,, Lachrymal Nerve in the Orbit. Superficial Branch to the Skin above the Zygoma.
    - *Malar* ,, — External Superficial Branch / Internal ,, ,, — to the skin over the Malar Bone.

Notice the mode of division of the Nerve. The Branches come off in pairs, and subdivide into pairs of Secondary Branches, from which again pairs of Tertiary Branches arise. The two Sets correspond to the Anterior and Descending Branches of the Internal Maxillary Artery, which see.

MECKEL'S GANGLION.—BRANCHES.

- *Downwards* to *Mouth*, —**Palatine** Branches (*Three*)
  - **Anterior Palatine** — To lower and back part of Nose (Inferior Nasal Branches). ,, supply the Mucous Membrane of the Hard Palate. ,, ,, Soft ,,
  - **External Palatine** — ,, the Tonsil. ,, supply the Mucous Membrane of the Soft Palate. ,, ,, Uvula.
  - **Posterior Palatine** — ,, the Tonsil. ,, supply the Mucous Membrane of the Soft Palate. ,, ,, Uvula.
- *Forwards* to *Orbit*, —**Orbital** Branches (*Three*) — ,, ,, Periosteum of the Orbit. ,, join the Lenticular Ganglion. ,, ,, Sixth Nerve.
- *Inwards* to *Nose*, —**Nasal** Branches (*Two*)
  - **Superior Nasal** — *Nasal*, to supply the Mucous Membrane on Superior and Middle Turbinated Bones. To join the Ganglion of Bochdalek, on Anterior Dental Nerve, above Canine Tooth.
  - **Naso-palatine** — *Nasal*, to supply the Mucous Membrane on the Septum Nasi. Naso-palatine proper, joining the Anterior Palatine Nerve on the Hard Palate.
- *Backwards* to *Pharynx*, —**Pharyngeal** Branches (*Two*)
  - **Vidian** (Motor & Sympathetic / Root of Ganglion) — *Nasal*, to supply the Mucous Membrane on posterior part of Roof of Nose. Vidian proper, derived from Gt. Superficial Petrosal Nerve, & Sympathetic on Int. Carotid.
  - **Pterygo-palatine** — *Nasal*, to supply Mucous Membrane on posterior part of Roof of Nose. Pterygo-palatine, to supply the Roof of the Pharynx.

Note that there are three Branches downwards, each triple, and three forwards, with two inwards and two backwards, each double. Of the two Branches inwards, twigs from each pass to supply structures connected with the anterior part of the Roof of the Mouth. Of the two Branches backwards, twigs from each pass to supply structures connected with the posterior part of the Roof of the Nose. The Interior and Posterior Sets resemble the *corresponding Branches of the Internal Maxillary Artery*, which see.

SUPERIOR MAXILLARY NERVE, ETC.

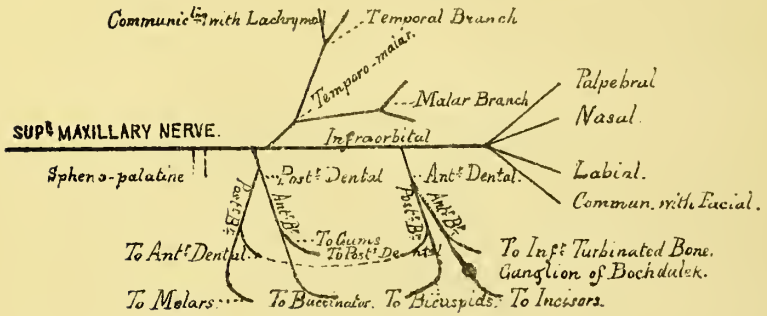

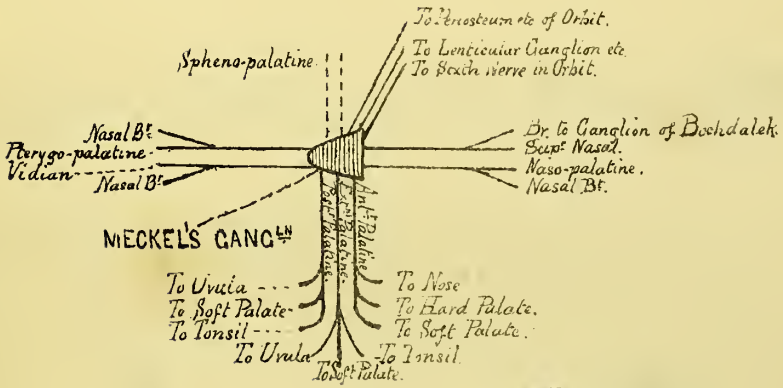

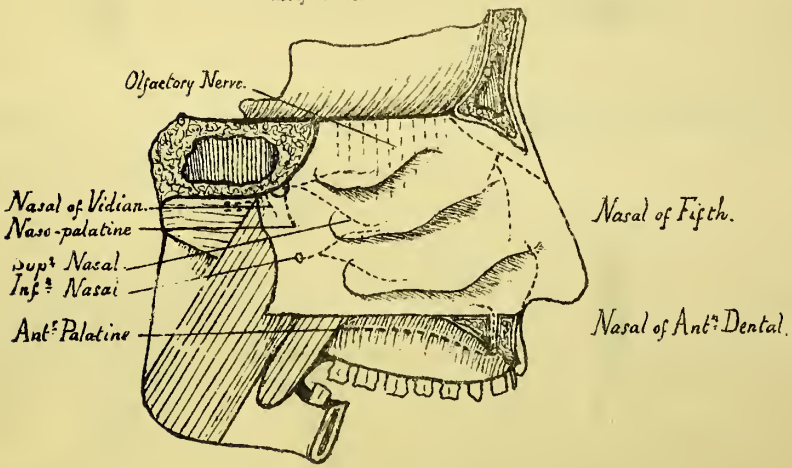

NERVES OF NOSE.

INFERIOR MAXILLARY NERVE.

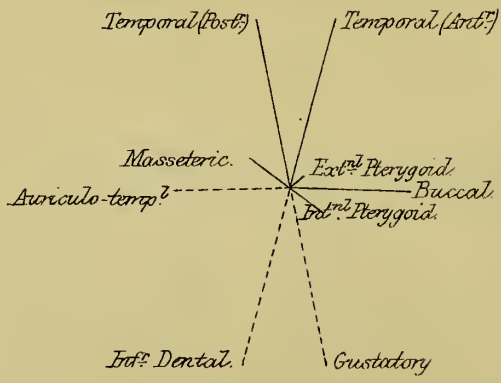

GANGLIA OF FIFTH NERVE AND TYMPANIC PLEXUS.

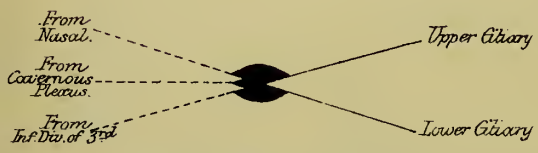

LENTICULAR GANGLION.

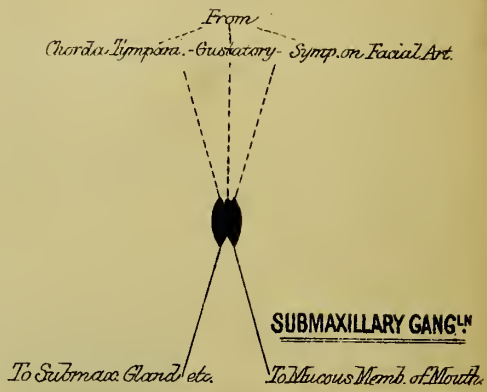

SUBMAXILLARY GANGLN

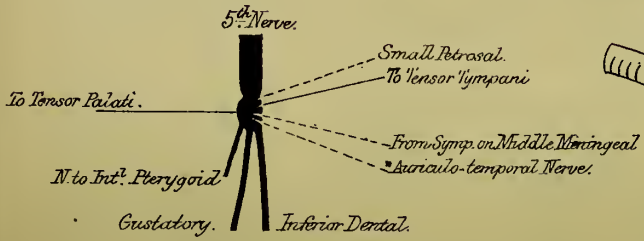

OTIC GANGLION.

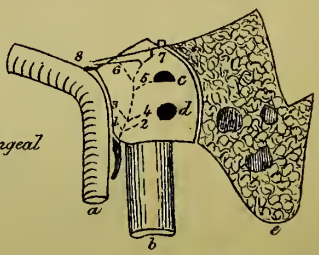

TYMPANIC PLEXUS.

NERVE SUPPLY OF THE NOSE (excluding the Olfactory Nerve, the Special Nerve of the Nose).

- On **Outer** Wall,
  - *posteriorly*
    - Superior Nasal — To supply the Mucous Membrane on the *Superior* Turbinated Bone.
      ,, ,, ,, ,, ,, *Middle* ,, ,,
    - Inferior Nasal, of Great Palatine — ,, ,, ,, ,, ,, ,, ,, ,,
      ,, ,, ,, ,, ,, *Inferior* ,, ,,
  - *anteriorly*
    - Nasal of Ophthalmic of 5th N. — ,, ,, ,, ,, ,, *Middle* ,, ,,
      ,, ,, ,, ,, ,, *Inferior* ,, ,,
    - Nasal of Anterior Dental — ,, ,, ,, ,, ,, ,, ,, ,,
- On **Inner** Wall, *posteriorly* — Nasal of Vidian; Superior Nasal — *Anteriorly* — Nasal of Ophthalmic of 5th Nerve; Naso-palatine.
- On **Roof** from *behind forwards*, Pterygo-palatine, Vidian, Superior Nasal and Nasal of Ophthalmic of 5th Nerve.

N.B.—Compare with 'Arteries of Nose,' p. 146.

BRANCHES.*

The Branches come off close together from the Nerve as soon as it appears below the Foramen Ovale.

Upwards	pass the	**Anterior**	and **Posterior Temporal** Nerves, and *forwards*	the	**Buccal.**
Downwards	,, ,,	**Inferior Dental**	,, **Gustatory** ,, ,, *backwards*	,,	**Auriculo-temporal.**
Upwards and outwards	passes ,,	**Masseteric**	and *downwards and inwards*	,,	**Internal Pterygoid** Nerve.
Outwards	in conjunction with the Buccal passes the				**External** ,, ,,

The Internal Pterygoid Nerve is connected at its root with the Otic Ganglion.
For the *Inferior Dental and Gustatory Nerves* see 'Nerves of Submaxillary Region,' p. 176.

The **AURICULO-TEMPORAL NERVE**

arises close to the Foramen Ovale by *two Roots*, and
ends opposite the upper part of the Pinna of the Ear in *two Branches.*

Intermediately it gives off *six Branches, three* single and *three* double alternating.
(1) A Branch to Otic Ganglion (Sensory Root of Ganglion).
(2) *Two* Branches round External Carotid Artery, to join Facial Nerve.
(3) A Twig to the Temporo-Maxillary Articulation.
(4) *Two* Branches to the Auditory Meatus, passing between Cartilage and Bone.
(5) A Branch to the Parotid Gland.
(6) *Two* Auricular Branches { to Pinna below Meatus and to Sympathetic on Internal Maxillary Artery.
,, above ,, ,, Tragus.

Between *the Roots* passes the Great Meningeal Artery.
The *posterior terminal branch* ends in { the Attrahens Aurem, and
the Skin of upper part of Pinna.
The *anterior* ,, ,, ,, over the course of the Posterior Superficial Temporal Artery.

* In the Diagram the continuous lines represent motor, and the dotted lines sensory branches.

Each Ganglion (except Meckel's*) has *three* **Roots**, one of which is Motor, one Sensory and one Sympathetic, thus :—

	Lenticular Ganglion.	Submaxillary Ganglion.	Otic Ganglion.
Motor	*Root* from—Inf. Div. of Third Nerve.	Chorda Tympani of Facial Nerve.	Small Petrosal of Facial Nerve.†
Sensory	,, ,, —Nasal Br. ,, 1st Div. of 5th N.	Gustatory of 3rd Div. of 5th N.	Auric-temp. ,, 3rd. Div. of 5th N.
Sympathetic	,, ,, —Cavern. Pl. on Int. Carot. Art.	Symp. Pl. on Facial Art.	Symp. Pl. on Grt. Meningeal Art.

Each Ganglion (except Meckel's*) gives off *two* **Branches**, thus :—

Lenticular G. { Upper Ciliary / Lower ,,

Submaxillary G. { To Submaxillary Gland, etc. / ,, Muc. Memb. of Mouth

Otic G. { To Tensor Palati. / ,, ,, Tympani.

* For Meckel's Ganglion see 'Superior Maxillary Nerve,' p. 172.
† Some motor fibres are said to be derived from the Nerve to the Internal Pterygoid Muscle.

TYMPANIC PLEXUS AND JACOBSON'S NERVE.

BRANCHES are distribnted as follows :—

{ To Mucous Membrane of Tympanum (2) / ,, ,, ,, ,, Eustach. Tube (1)

{ To Foramen Rotundum (4) / ,, ,, Ovale (5)

{ To Sympathetic on Internal Carotid (3). / ,, Great Petrosal Nerve (6).

The uppermost Branch is prolonged as the Small Petrosal (7), joining the Facial by a special twig.

In connection with the Submaxillary Region there are *four* chief Nerves, viz. :—the **Inferior Dental, Gustatory, Hypoglossal** and **Glosso-pharyngeal.**

These four Nerves lie in similar curves and give off Branches in a similar manner.

The first two Nerves have analogous **RELATIONS**, as have also the last two, thus :—

The **Inferior Dental** and **Gustatory** are Branches of the Inferior Maxillary Nerve and descend side by side,

lying first between { the Ext. Pterygoid Muscle and / ,, Int. ,, ,, } and then between { the Internal Lateral Ligament and / ,, Ramus of the Jaw.

{ The *Inferior Dental* then enters its Canal *in* the Jaw to supply the Teeth and Skin, etc., of Lower Lip.
{ ,, *Gustatory* ,, runs on the Muc. Memb. *under* ,, ,, ,, ,, Tongue ,, Mucous Membrane of Mouth.

The **Hypoglossal** and **Glosso-pharyngeal** arise directly from the Medulla and

appear in the Neck between { the Internal Carotid Art. and / ,, ,, Jugular Vein } ——thence curving forward

{ the Hypoglossal crosses over { ,, *External* Carotid Art. and / ,, Occip. Art. (at origin) } and passes between { the Mylo-hyoid and / ,, Hyo-glossus } to end in *Muscles* of Tongue.
{ ,, Glosso-phar. ,, ,, { ,, *Internal* Carotid Art. and / ,, Ascending Pharyngeal } ,, ,, ,, { ,, ,, ,, and / ,, Mid. Constrictor } to end in *Mucous Membrane* of Tongue.

BRANCHES.

Each Nerve first receives or gives a *special* Branch, then gives off a double Branch or *two* sets of Branches, both upwards and downwards, and finally ends in a double Branch or *two* sets of Branches, thus :—

	Special Branch.	Branches upwards.	Branches downwards.	Terminal Branches.
Inf. Dental	Mylo-hyoid Branch, to Mylo-hyoid Muscle & ant. belly of Digastric.	{ To Lower Molars and / ,, ,, Bicuspids.	Inf. Labial* { To Skin, etc., of Lower Lip. / ,, join Supramaxillary Br. of Facial Nerve.	Incisor Br. { To Incisor Teeth. / ,, Canine Tooth.
Gustatory	Chorda Tympani N., from Facial N. through Tympanum & Glaserian Fissure.	{ ,, Muc. Memb. of Mouth / ,, Sublingual Gland.	{ To Submaxillary Ganglion. / ,, join Hypoglossal on Hyo-glossus.	{ To ant. ⅔rds of surf. of Tongue. / Commun. with 9th N. in Tongue.
Glosso-pharyngeal	Brs. to Int. Carotid, joining Sympathetic on Artery.	{ ,, Tonsil. / ,, Soft Palate.	{ ,, Stylo-pharyngeus. / ,, Pharyngeal Plexus.	{ Lateral Br. / Median Br. } to post. ⅓ of surf. of Tongue.
Hypoglossal	Descendens Noni, to Omo-hyoid, Thyro-hyoid & Sterno-thyroid	{ ,, Stylo-glossus. / ,, Hyo-glossus.	{ ,, Thyro-hyoid (special branch). / ,, Genio-hyoid.	{ To Intrinsic Muscles of Tongue. / ,, Genio-hyo-glossus.

* The Inferior Labial passes outwards not downwards.

For further Relations see 'Muscles of Submaxillary Region,' p. 77.

NERVES OF SUBMAXILLARY REGION.

INF^R. DENTAL N^Y.

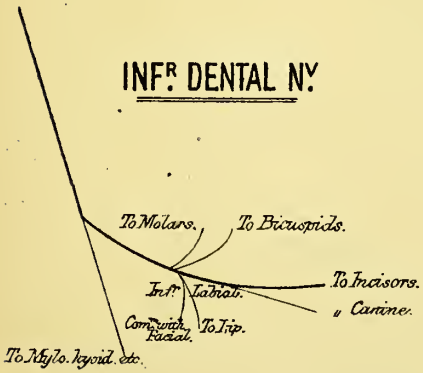

GUSTATORY N^Y.

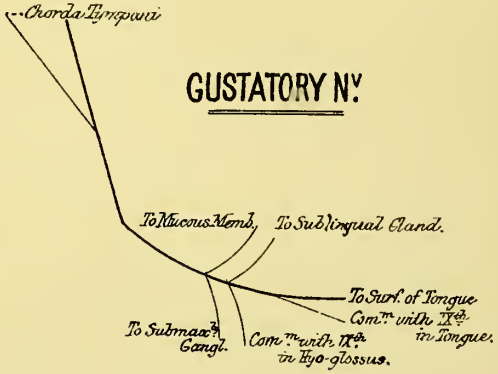

GLOSSO-PHARYNGEAL N^Y.

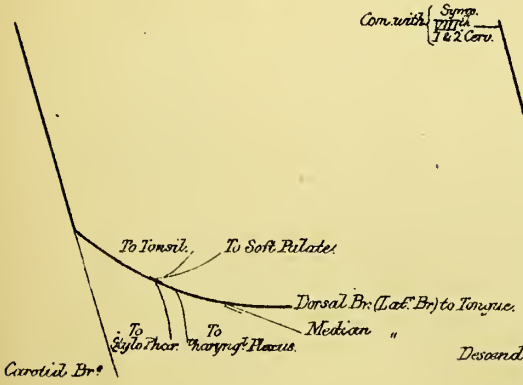

HYPOGLOSSAL N^Y.

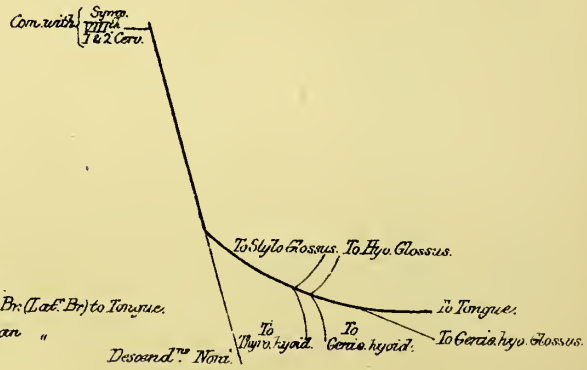

CERVICAL PLEXUS.

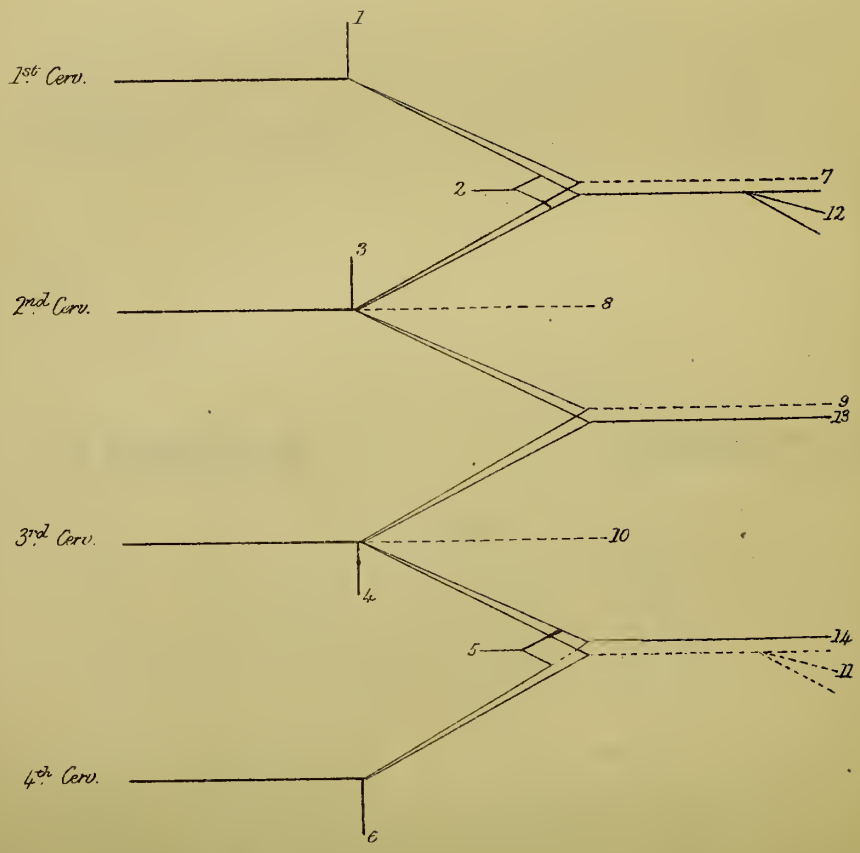

The Cervical Plexus is **formed** by the union in loops of the Anterior Divisions of the first three Cervical Nerves and part of the fourth in front of the corresponding Transverse Processes of the Vertebræ.

The **BRANCHES** come off both from the Nerves themselves and from the Loops between them, and may be divided into Cutaneous, Muscular and Communicating Nerves.

The **Cutaneous** Branches arise one from each Loop and one from each Nerve, except in the case of the *first* and *last* Nerves.
,, **Muscular** ,, ,, ,, ,, ,, ,, ,, ,, *middle* Loop.
,, **Communicating** ,, ,, ,, only.

	Muscular.	Cutaneous.	Communicating.
1st Cervical Nerve	To Rectus Lateralis (1)	—	—
Loop between 1st and 2nd Nerves	,, Recti Antici (2)	Mastoid Branch* (7)	With {Pneumogastric, Hypoglossal, Sympathetic} (12)
2nd Cervical Nerve	,, Sterno-mastoid (3)	Small Occipital (8)	—
Loop between 2nd and 3rd Nerves	—	Great Auricular (9)	,, Descendens Noni Nerve. (13)
3rd Cervical Nerve	,, Lev. Ang. Scap. (4)	Superficial Cervical (10)	—
Loop between 3rd and 4th Nerves	,, Scalenus Med. (5)	Desc. Cut. {Sternal, Clavicular, Acromial} (11)	,, With Spinal Accessory N. (14)
4th Cervical Nerve	,, Diaphragm (Phrenic N.)† (6)	—	—

* The Mastoid Branch is frequently undeveloped.
† The Phrenic Nerve derives its main Root from the 4th, a second Root from the 5th, and a third from the 3rd Cervical Nerve.

The Branches of the Plexus are usually divided into Superficial and Deep Sets.

The **Superficial Set** consists of Cutaneous Branches grouped as {*Ascending* and *Descending*} Nerves.

,, **Deep** ,, ,, ,, {Muscular and Communicating} ,, ,, {*Internal* and *External*} ,,

FORMED by the union of **6** Nerves at the lower part of the Neck,
giving off **6** Branches above the Clavicle and **6** below, and ending in **6** terminal Branches.

Formation *as frequently described* :—
The 5th Nerve joined by the 6th near the Vertebræ and by the 7th near the 1st Rib forms *an outer* *Cord* (γ).
,, 8th ,, ,, ,, part of the 1st Dorsal, near the Vertebræ ,, ,, *inner* ,, (α).
A Branch from the outer Cord joins a Branch from the inner to form *a posterior* ,, (β).

Formation *as sometimes described and usually found* :—
Each Nerve near its origin divides into an Anterior and a Posterior Division.
The Anterior Divisions of the 5th, 6th and 7th Nerves unite to form *an outer* *Cord* (γ).
,, Posterior ,, ,, 5th, 6th, 7th and 8th ,, ,, ,, *a posterior* ,, (β).
,, Anterior ,, ,, 8th Cerv. and 1st Dors. ,, ,, ,, *an inner* ,, (α).

See Diagrams.

BRANCHES given off *above the Clavicle* (**6**) :—

From 5th and 6th (generally also 7th and 8th)	twigs	to the Muscles closing *Summit* of Thorax, viz. :—	Scalenes (and Longus Colli)	(1).
,, 5th (before union with twig of 4th)	branch	,, Muscle forming *Base* ,, ,, ,,	Diaphragm	(2).
,, 5th (after ,, ,, ,, ,,)	,,	,, Muscles joining Shoulder-girdle to Trunk	*posteriorly*	(3).
,, 5th and 6th (by separate roots)	,,	,, Muscle ,, ,, ,, ,, ,,	*laterally*	(4).
,, 5th ,, 6th (at point of union)	,,	,, ,, ,, ,, ,, ,,	*anteriorly*	(5).
,, 5th ,, 6th (from common trunk)	,,	,, Muscles ,, ,, ,, ,, ,, Humerus	*posteriorly*	(6).

The **Brs. to the Scalenes**	(1) turn *inwards deeply*	to end in Scalenes & Longus Colli.	
,, **Br.** ,, ,, **Diaphragm**	(2) turns ,, ,,	,, join **Phrenic** N.	[Rhomboidei.
,, **Rhomboid Nerve**	(3) *pierces* Middle Scalene *transversely* & passes *outwards* deeply	,, supply Lev. Anguli Scapulæ and	
,, **Nerve to the Serratus**	(4) ,, ,, ,, *obliquely* ,, *downwards* ,, ,, ,,	Serratus Magnus.	
,, **Nerve to the Subclavius**	(5) runs *downwards superficially* over 3rd part of Subclavian Art.	,, ,, Subclavius.	[spinatus.
,, **Suprascapular Nerve**	(6) ,, *outwards* ,, with Suprascapular Artery	,, ,, Supraspinatus and Infra-	

BRANCHES given off *below the Clavicle* (**6**).

Three backwards	—**Subscapular**	(from *Post.* Cord or Trunks forming it)	*Highest*	(7)	to Subscapularis (upper part).
			Middle	(8a)	,, Subscapularis (lower part) and Teres Major.
			Lowest	(8b)	,, Latissimus Dorsi.
Two forwards	—**Ant. Thoracic**	(one from *Ext.* and one from *Int.* Cord)	*External*	(9a)	,, Pectoralis Major.
			Internal	(9b)	,, ,, ,, and Pectoralis Minor.
One outwards	—**Circumflex**	(from *Posterior* Cord) —by 3 *sets of* Brs.		(10)	,, Shoulder-joint. ,, Teres Minor. ,, Deltoid and Skin over it.

These Nerves arise—one from the *Outer* Cord, one from the *Inner* Cord, and the rest from the *Posterior* Cord. Compare with 'Axillary Artery,' p. 141.

BRACHIAL PLEXUS. DIAGRAM A.

As generally found and described.

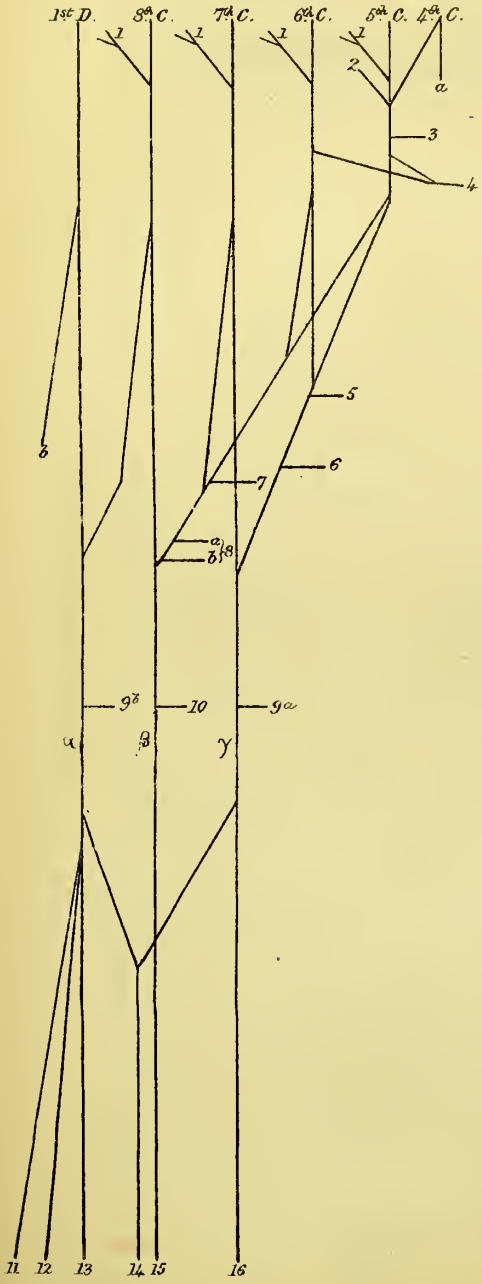

As formerly described.

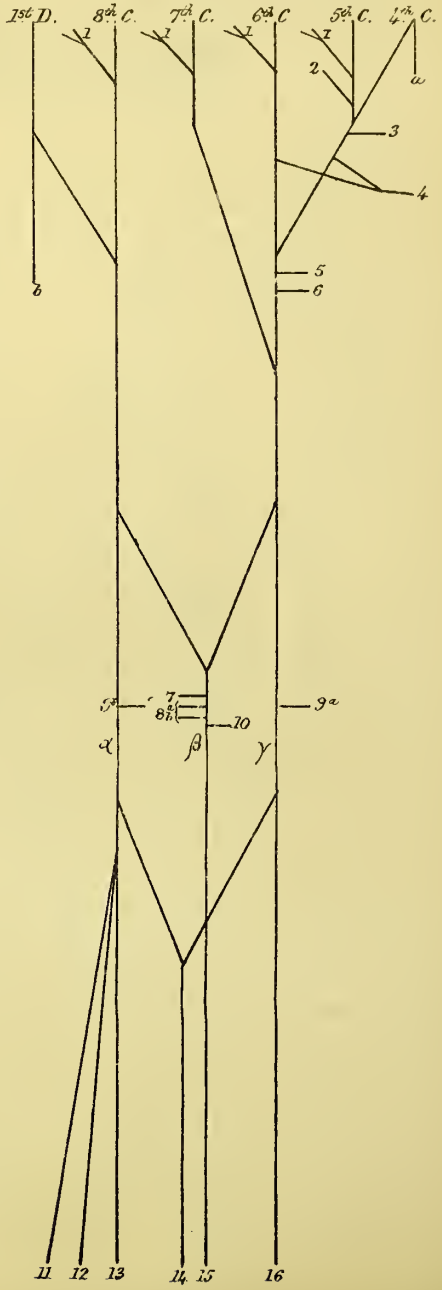

BRACHIAL PLEXUS. — DIAGRAM B.

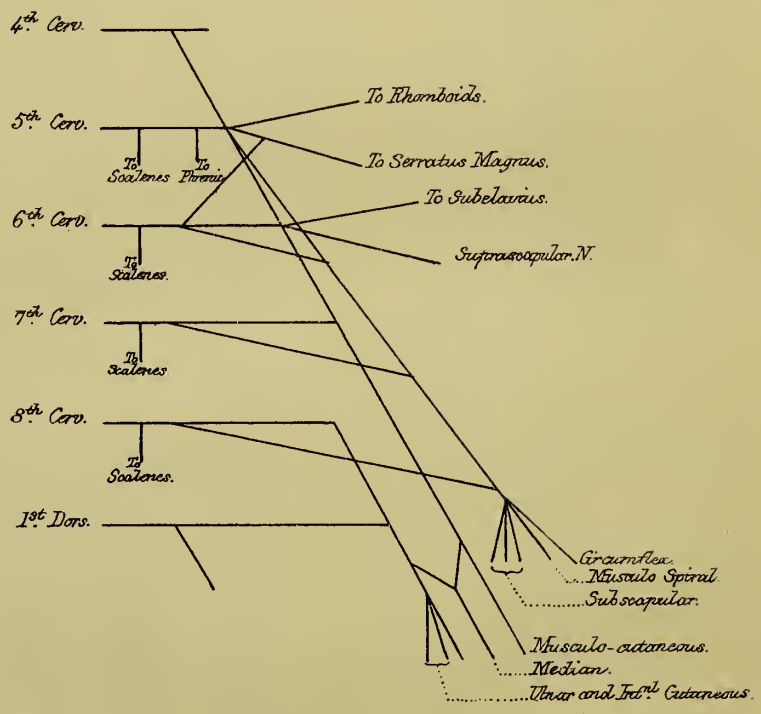

BRANCHES given off *terminally* (6)

Three internally	—term. brs. of *Int.* Cord (chiefly Cutaneous)	**N. of Wrisberg**	(11)	to Skin		*of inner side* of Arm.
		Int. Cutaneous	(12)	,, ,,		,, ,, ,, Forearm.
		Ulnar	(13)	,, ,,	and Muscles	,, ,, ,, Hand.
Two intermediately	formed from *Int.* and *Ext.* Cord (chiefly Muscular)	**Median**	(14)	,, ,, ,,	,,	*on front* of Forearm and Hand.
		Musculo-spiral	(15)	,, ,, ,,	,,	,, *back* ,, Arm, Forearm & Hand.
One externally	—term. br. of *Ext.* Cord Muscular and Cutaneous	**Musculo-cutaneous**	(16)	,, Muscles ,, Skin		,, *front* of Arm and *of outer side* of Forearm.

Of these Nerves the *external* passes down on the outer side of the limb; the *middle* two pass down more or less centrally, one on the front, the other on the back; the three *internal* run on the inner side.

DISTRIBUTION OF TERMINAL BRANCHES.

Median (*Twelve* Branches).

In Forearm (*six*).

Four Muscular Branches
- To Pronator Teres.
- ,, Flexor Carpi Radialis.
- ,, Palmaris Longus.
- ,, Flexor Sublimis Digitorum.

One Ant. Interosseous Br.
- ,, Pronator Quadratus.
- ,, Flexor Longus Pollicis.
- ,, half of Flexor Profundus Digitorum.

One Cutaneous ,, —Palmar Cutaneous.

In Hand (*six*).

Five Digital Branches
- *Three*
  - To contiguous sides of 3rd & 4th Fingers
  - ,, ,, ,, ,, 2nd & 3rd ,,
  - ,, radial side ,, 2nd Finger.
- *Two*
  - ,, ulnar ,, ,, Thumb.
  - ,, radial ,, ,, ,,

One Muscular Branch
- ,, Abductor Pollicis.
- ,, Opponens ,,
- ,, half of Flexor Brevis Pollicis.

Musculo-cutaneous (*six* Branches).

Three Muscular Branches
- To Biceps.
- ,, Coraco-brachialis.
- ,, Brachialis Anticus.

Two Cutaneous ,,
- Anterior, to Forearm.
- Posterior ,, ,,

One Articular Branch —To Elbow-joint.

Musculo-spiral (*nine* Branches).

Three Cutaneous Branches
- *One* —Internal Cutaneous.
- *Two*
  - Short External Cutaneous.
  - Long ,, ,,

Six Muscular ,,
- To Triceps *
- ,, Subanconeus *
- ,, Anconeus *
- ,, Brachialis Anticus †
- ,, Supinator Longus †
- ,, Extensor Carpi Radialis Longior †

* Extensors of Forearm.
† Muscles attached to External Intermuscular Septum.

Ulnar Nerve.

In Forearm (*Six* Branches).

Three Cutaneous Brs. { Internal Cutaneous to Forearm.
Palmar ,, ,, Palm of Hand. [Digits.
Dorsal ,, ,, Back of Hand and 1½ inner

Two Muscular ,, { To Flexor Carpi Ulnaris.
,, half of Flexor Profundus Digitorum.

One Articular Branch — ,, Elbow-joint.

In Hand (*six* sets of Branches).

Three Sets of Muscular Branches { *Three* { To Abductor Minimi Digiti.
,, Opponens ,, ,,
,, Flexor Brevis ,, ,,
Nine { ,, the seven Interossei.
,, two Inner Lumbricales.
One & a half { ,, Adductor Pollicis. [licis.
,, Inner half of Flexor Brevis Pol-

Two Superficial Palmar Branches { To inner side of Little Finger.
,, contiguous sides of Little & Ring Fingers.*

One Articular Br.— ,, Wrist-joint.

* Supplying also the Palmaris Brevis.

Internal Cutaneous (*three* Branches).

{ Bicipital Branch to Skin over Biceps.
Ant. Division ,, ,, ,, front of inner aspect of Forearm.
Post. ,, ,, ,, ,, back ,, ,, ,, ,, ,,

{ The **N. of Wrisberg** ends *between* Int. Condyle and Olecranon.
The Intercosto-humeral ,, *over* the Olecranon.
The Internal Cutaneous crosses *over* the Internal Condyle.

LUMBAR PLEXUS.

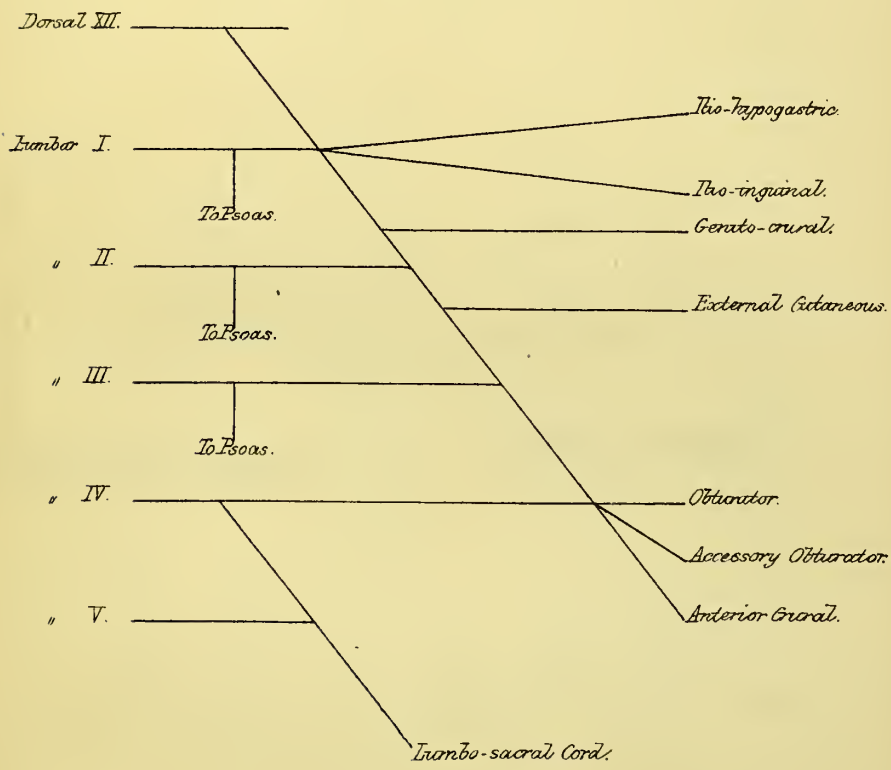

ANTERIOR CRURAL NERVE.

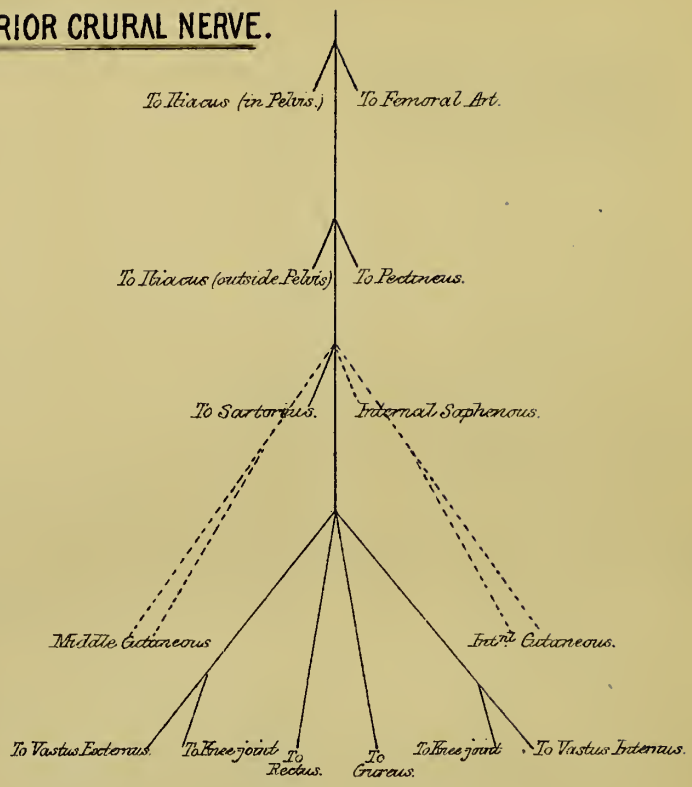

OBTURATOR NERVE.

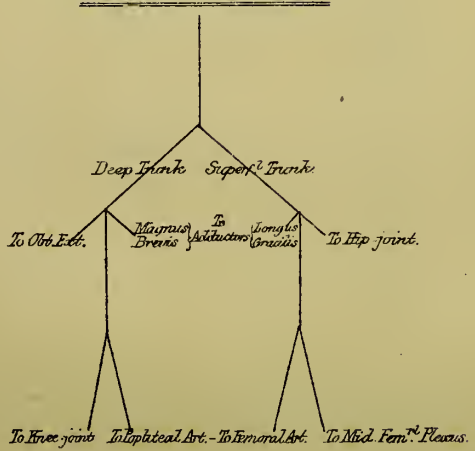

ACCESS.RY OBTUR.TR NERVE.



THE LUMBAR PLEXUS is formed by the union of the upper three Lumbar Nerves and is supplemented by part of the 12th Dorsal and part of the 4th Lumbar.

The remainder of the 4th, together with the 5th, forms the Lumbo-sacral Cord, which goes on to the Sacral Plexus.

BRANCHES.

Twigs to the **Psoas** from the 1st, 2nd and 3rd Nerves near their commencement.

From the **1st** Nerve	are given off the	**Ilio-hypogastric.**	
		Ilio-inguinal.	
,, loop between 1st and 2nd is	,, ,,	**Genito-Crural.**	
,, ,, ,, 2nd and 3rd ,,	,, ,,	**External Cutaneous.**	
,, *extremity* of Plexus are	,, ,,	**Obturator** and **Accessory Obturator.**	
		Anterior Crural.	

The Anterior Crural forms the *continuation* of the Plexus in the direct line, the other offsets forming *branches*. Apart then from the direct continuation of the Plexus there are given off *six* lateral Branches, two of which are accessory to the main continuation.

Compare with the Sacral Plexus and Diagram **B** of the Brachial Plexus.

At first the Nerves are contained in the substance of the Psoas Magnus.

The **Ilio-hypogastric** and **Ilio-inguinal**	emerge	through	*outer*	edge of	Muscle	*near the top.*
,, **External Cutaneous**	emerges	,,	,,	,,	,,	*at the middle.*
,, **Anterior Crural**	,,	,,	,,	,,	,,	*below.*
,, **Obturator** and **Accessory Obturator**	emerge	,,	*inner*	,,	,,	,,
,, **Genito-crural**	emerges	,,	*anterior*	surface		*near the top* and lies throughout on that surface.

See Diagram of 'Relations of Psoas Magnus,' p. 101.

Note that the *first* branch of the Plexus (Ilio-hypogastric) emerges through the *outer edge* of the Psoas.
the *third* (Genito-crural) through the *anterior surface*, and the *fifth* (Obturator) through the *inner edge*.
The other branches appear through the outer edge one *above*, one *below*, and one *intermediately*.

In their Course outwards the Nerves lie as follows :

The **Ilio-hypogastric** on the Quadratus Lumb. only.
,, **External Cutaneous** on the Iliacus only.
,, **Genito-crural** on the Psoas only.

The **Ilio-inguinal** first on the Quadratus, then on the Iliacus.
,, **Anterior Crural** between the Iliacus and Psoas.
,, **Obturator** and **Accessory Obturator** to inner side of Psoas (over Obturator Int.).

Note that the Nerves lie on *one* Muscle and on or between *two* alternately.

For the *Distribution* of the
- **Ilio-hypogastric** and **Ilio-inguinal**, see 'Intercostal Nerves,' p. 170.
- **Genito-crural*** and **External Cutaneous**, ,, 'Cutaneous Nerves of Body,' pp. 167 and 168.
- **Anterior Crural** and **Obturator** ,, 'Anterior Crural Nerve,' p. 182.

* The Genito-crural sends a special branch to the Cremasteric covering of the Cord through the Internal Abdominal Ring and another twig to the Femoral Artery.

ANTERIOR CRURAL NERVE.

The **Branches** of the Nerve are grouped in *three* Sets of *four* Branches each; the *First* Set being muscular, comprising two Branches above Poupart's Ligament and two below, *all* short; the *Second* Set, forming the *Superficial* Division of the Nerve, consisting of 3 cutaneous branches and one muscular, *all* long; the *Third* Set, forming the *Deep* Division of the Nerve, consisting of 4 muscular branches, *two* short and *two* long.

First Set
- To Iliacus (within Pelvis).
- ,, Femoral Artery.
- ,, Iliacus (external to Pelvis).
- ,, Pectineus.

Second Set
- Middle Cutaneous (double).
- Nerve to Sartorius.
- Internal Saphenous.
- Internal Cutaneous (double).

Third Set
- To Rectus Femoris.
- ,, Cruræus.
- ,, Vastus Ext. (giving br. to Knee-joint).
- ,, ,, Int. (,, ,, ,, ,,).

OBTURATOR NERVE.

The Obturator Nerve just before emerging from the Pelvis splits into *two Divisions*, Superficial and Deep. The **Superficial Division** passes out *above* the Obturator Externus, and lies *over* the Adductor Brevis; the **Deep Division** emerges *through* the Obturator Externus and runs *beneath* the Adductor Brevis.

The **Branches** are as follows:

Superficial Division* to
- Superficial Adductors
  - Pectineus.
  - Gracilis.
  - Adductor Longus.
  - ,, Brevis.
- Hip-joint.
- Femoral Artery.
- Mid-femoral Plexus betw.
  - Int. Cutaneous and
  - ,, Saphenous.

Deep Division to
- Deep Adductors
  - Adductor Brevis.
  - ,, Magnus.
- Knee-joint.
- Popliteal Artery.
- Obturator Externus.

ACCESSORY OBTURATOR NERVE.

Passes out from Pelvis over Pubic bone and divides at once into 3 Branches:—

1. To Pectineus. 2. To Hip-joint. 3. To Superficial Division of Obturator Nerve.

* Three of the Branches of each Division are similar to three of those of the other. The remaining Branch of the Superficial Division goes to the Skin and tha of the Deep Division to a Muscle. The corresponding Branches of each Division are put first in the above table.

THE SACRAL PLEXUS is formed by the union of the upper three Sacral Nerves, and is supplemented by part of the 4th Sacral below, and by the Lumbo-sacral Cord (composed of the 5th and part of the 4th Lumbar) above.

The remainder of the **4th SACRAL** is subdivided as follows :—A triple Muscular Branch supplies the Levator and the Sphincter Ani and the Coccygeus,—a Pelvic Branch joins the Pelvic Plexus to end in the Pelvic Viscera,—and a Coccygeal Branch joins with the 5th Sacral and the Coccygeal to form a Plexus over the Coccyx.—The fourth Sacral thus gives four Branches.

BRANCHES.

From the **2nd** and **3rd** near their origin are given off special Branches to the **Pyriformis.**

,, ,,	Lumbo-sacral Cord	is ,, ,,	the **Sup. Gluteal.**		
,, ,,	Loop between **1st** and **2nd**	,, ,, ,,	,, N. to the **Obtur. Int.**		
,, ,, ,, ,,	**1st** ,, **2nd**	,, ,, ,,	,, ,, ,, **Sup. Gemellus.**		
,, ,, ,, ,,	**2nd** ,, **3rd**	,, ,, ,,	,, ,, ,, **Inf. Gemellus** and **Quadratus.**		
,, ,,	Lower end of the Plexus	are ,, ,,	,, ,, ,, **Pudic** and **Small Sciatic.**	,, ,, ,, **Great Sciatic.**	

The Great Sciatic forms the direct continuation of the Plexus, the Pudic and Small Sciatic being accessory to it. As in the case of the Lumbar Plexus there is thus one terminal Branch and six lateral.—Compare with the Lumbar Plexus and Brachial Plexus, Diagram **B.**

Note that excluding the three terminal Branches, the lateral Branches supply the Muscles attached round the Great Trochanter from before back, and that they come off from the Plexus in the order in which those Muscles are fixed to the Trochanter.

BRANCHES OF SACRAL PLEXUS—DISTRIBUTION.

The **Nerves to the Pyriformis** enter the anterior surface of the Muscle within the Pelvis.

The **Superior Gluteal** Nerve emerges from the Pelvis through the Great Sacro-sciatic Foramen, above the Pyriformis, and divides into two Branches.

The *Upper* Branch, the smaller, supplies the two superior or anterior Glutæi, viz. :—the G. Medius and G. Minimus.
, *Lower* ,, ,, larger ,, ,, same muscles together with the Tensor Vaginæ Femoris.

The Superior Gluteal Nerve thus supplies the three *Rotators in* of the Hip-joint.

The **N. to the Obturator Int.** emerges from the Pelvis through the Gt. Sacro-sciatic Foramen, below the Pyriformis, over the Ischial Spine, and re-enters ,, ,, ,, ,, Small ,, ,, ,, with the Obt. Int. Tendon to pierce the inner surface of the Muscle.

The **N. to the Gemellus Sup.** —passes out of the Pelvis with the preceding to enter the *superficial* surface of the muscle.
The **N. to the** { **Gemellus Inf.** and **Quadratus Fem.** } ,, ,, ,, ,, ,, ,, ,, } *deep* surface of the muscle, and usually to supply the Hip-joint.

The **Pudic Nerve** { accompanies the Nerve to the Obturator Internus out of, and back into the Pelvis, and then ,, ,, Internal Pudic Vessels through the Perineum.

Branches { *firstly*, at *back of Ischio-rectal Fossa*, the Inferior Hæmorrhoidal Nerve, accompanying Inf. Hæmorrhoid Artery to Ext. Sphincter, Integuments, etc.,
lastly, in *front of Triangular Ligament*, the Dorsal Nerve of the Penis and the Nerve to the Corpus Cavernosum.
intermediately, at *front of Ischio-rectal Fossa*, the Perineal Nerve.

The **Perineal Nerve** gives off secondary Branches { Two *Superficial* Perineal, Anterior and Posterior.
Muscular Nerves to Muscles of Anterior part of Perineum.
Nerve to the *Corpus Spongiosum* (Bulb).

Compare with the Internal Pudic Artery, p. 123. The Branches of the Artery are all primary, the intermediate Branches of the Nerve are secondary.

Relations of Nerves, etc., at lower part of Great Sacro-sciatic Foramen (see Diagram).

Externally are the Great and Small Sciatic Nerves and the Sciatic Artery, the two latter resting on the former.
Internally ,, ,, Pudic ,, Internal Obturator ,, ,, ,, Int. Pudic ,, ,, ,, ,, ,, ,, either side of the ,,
Intermediately ,, ,, Nerve to the Superior Gemellus and the Nerve to the Inferior Gemellus and Quadratus.

Two Nerves and an Artery lie on either side, and two Nerves intermediately.

Small Sciatic Nerve.

Relations { *In Gluteal Region* it lies upon Gt. Sciatic N., *beneath* Gluteus Maximus, supplying { *Muscular* Br., Inferior Gluteal, to Gluteus Maximus.
At back of Thigh it leaves ,, ,, ,, & runs ,, Fascia Lata ,, *Cutaneous* Brs., Int. and Ext.
At back of Leg it pierces Fascia Lata opposite lower part of Popliteal Space, and joins External Saphenous Nerve.

Of the Cutaneous Branches { one of the Internal set, the Inferior Pudendal, passes to Perineum to join the superficial Perineal Nerves.
some ,, ,, External ,, turn upwards over the Gluteus Maximus, becoming recurrent.

Great Sciatic Nerve.

Relations { Continuous above in Pelvis with Sacral Plexus, bifurcating below, at upper part of Popliteal Space, into Popliteal Nerves.
In Gluteal Region it rests *upon* the Muscles at the back of the Hip-joint, *beneath* Gluteus Maximus (see above).
At back of Thigh ,, ,, ,, ,, Adductor Magnus, *between* Biceps and Semi-membranosus.

Branches { *Articular* to Hip-joint (often derived from the Sacral Plexus).
Muscular ,, Hamstrings and to Adductor Magnus (Posterior Fibres)

SACRAL PLEXUS.

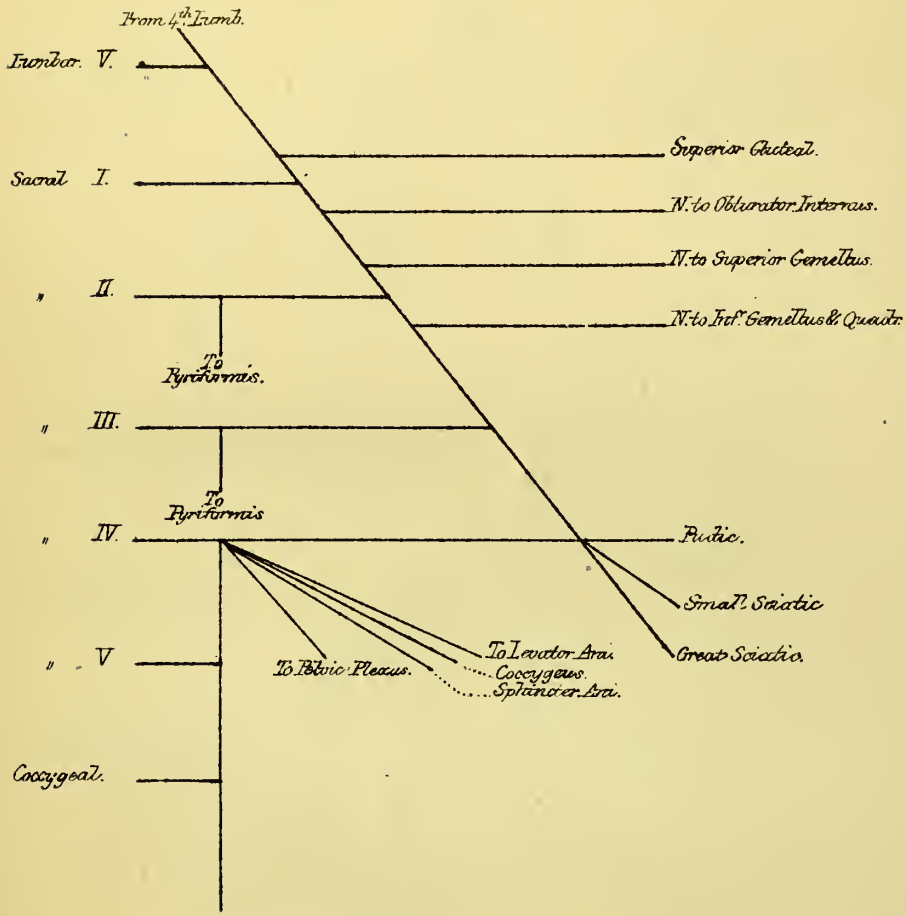

NERVES OVER ISCHIAL SPINE.

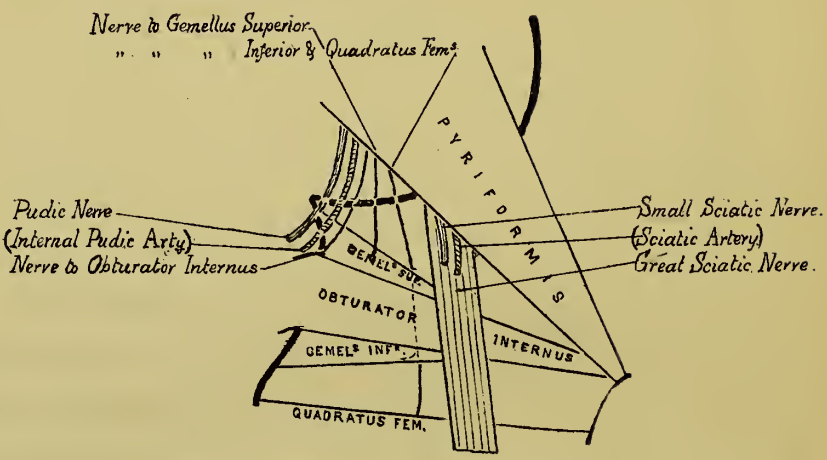

PLANTAR NERVES.

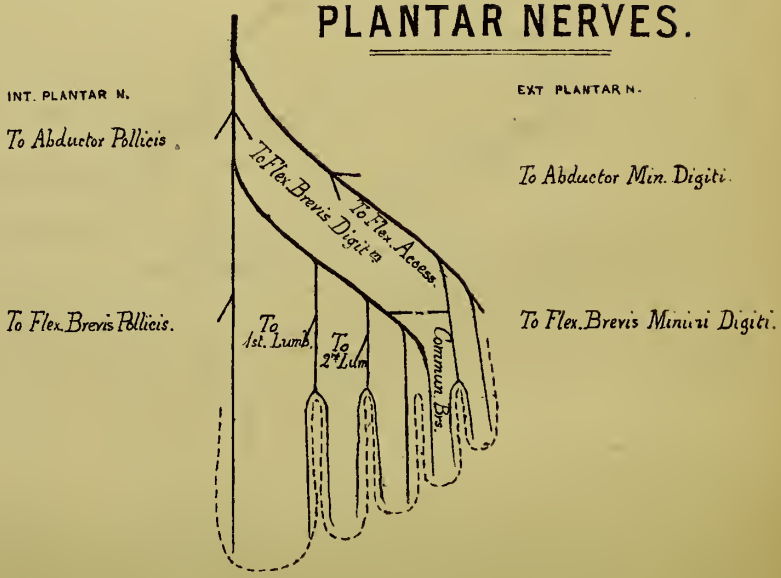

Internal Popliteal Nerve.

Course, etc. — Accompanies the Popliteal Artery, lying first on its *outer* side, then *over* it, and lastly to its *inner* side. Is continuous at the lower part of the Popliteal Space with the Posterior Tibial Nerve.

Branches (Nine)
- *Three Articular* to Knee-joint, one with each Internal Articular Artery and one with the Azygos Articular Artery.
- *One Cutaneous*, External Saphenous (see 'Nerves of Anterior and Posterior Aspects of Body,' and Note on p. 169).
- *Five Muscular*, to each Head of Gastrocnemius, to Soleus, to Plantaris and to Poplitens.

External Popliteal Nerve.

Course —Accompanies the tendon of the Biceps to end below Head of Fibula, between Bone and Peroneus Longus Muscle.

Branches (*Six*)
- *Three* lateral
  - *One* Articular, with Superior External Articular Artery, sending a branch with the Inferior External Articular Artery.
  - *Two* Cutaneous
    - one or two twigs to the Skin over the outer head of the Gastrocnemius.
    - ,, , Communicans Fibularis, to join External Saphenous at middle of back of Leg
- *Three* terminal
  - Articular Recurrent, accompanying Recurrent Articular Artery of Anterior Tibial.
  - Musculo-cutaneous, to Peronei Muscles and Skin of front of Leg.
  - Anterior Tibial Nerve.

All the structures connected with the Popliteal Space may be grouped in sets of three or multiples of three.

Anterior Tibial Nerve.

Course —Passes under Extensor Longus Digitorum, and accompanies Ant. Tibial Artery in its lower $\frac{2}{3}$, lying to its *outer* side.

Branches
- *Muscular* } in *Leg*, to the four muscles on the front of the Leg.
- *Articular* } ,, *Foot* ,, Extensor Brevis Digitorum and Tarsal Joints.
- *Cutaneous*, to contiguous sides of 1st and 2nd Toes.

Posterior Tibial Nerve.

Course — Accompanies Posterior Tibial Artery, lying first to its inner side, then over it and at ankle to its *outer* side. dividing at upper border of Internal Annular Ligament into the External and Internal Plantar Nerves.

Branches
- *Muscular*, to the three deep muscles on the back of the Leg.
- *Cutaneous* (Calcaneo-plantar), through the Internal Annular Ligament to Skin of Heel, etc.

Plantar Nerves.

- **Internal**, before dividing, supplies the two Muscles between which it lies, viz. :—Flexor Brevis Digitorum and Abductor Pollicis.
- **External** ,, ,, ,, ,, ,, ,, ,, ,, ,, ,, Acces. ,, ,, ,, Minimi Dig.

- **Internal** divides into four Digital Brs. supplying
  - by the 1st the Flexor Brevis Pollicis and the inner side of the Great Toe.
  - ,, ,, 2nd ,, 1st Lumbrical ,, ,, contiguous sides of 1st & 2nd Toes.
  - ,, ,, 3rd ,, 2nd ,, ,, ,, ,, ,, ,, 2nd ,, 3rd ,,
  - ,, ,, 4th a branch to join Ext. Plantar ,, ,, ,, ,, ,, 3rd ,, 4th ,,
- **External** ,, ,, two Digital Brs. ,, and a Deep Branch
  - ,, ,, 1st the Flex. Brev. Min. Digiti ,, ,, outer side of the Little Toe.
  - ,, ,, 2nd a br. to join br. of 4th Digital of Ext. Plantar, & contiguous sides of the 4th and 5th Toes.
  - ,, all the Muscles of Foot except those above-mentioned accompanying Ext. Plant. Art.

Note that each Nerve supplies two Muscles, one a Flexor of the Toes, the other a special Abductor, by its undivided trunk, and that each supplies a special branch from each of its digital divisions.

N.B.—The Internal Plantar Nerve supplies **5** muscles and the External Plantar **14**.
In the Hand, the Median Nerve ,, **4½** ,, ,, Ulnar Nerve **14½**.

APPENDIX.

EXTERNAL ILIAC ARTERY.*

Course — From Lumbo-sacral Articulation to lower border of Poupart's Ligament, indicated by a *surface line* drawn from left side of Umbilicus to middle of Poupart's Ligament.

Relations
- Lies at first *along inner* margin of, and near its termination upon *anterior* surface of Psoas Magnus.
- ,, *beneath* Peritoneum, *upon* Fascia Iliaca, and is *invested* by Subperitoneal Fascia,
- is *accompanied by* the External Iliac Vein, which lies to its inner side below and behind it above,†
- is *crossed* near its termination by the
  - Spermatic *Artery*,
  - Circumflex Iliac *Vein*,
  - Genito-Crural *Nerve*.

† Lymphatics and Lymphatic Glands also lie alongside the Artery.

Branches —(both arising near its termination).

Epigastric (Deep)
- Runs *first forwards* to Poupart's Ligament, *then upwards and inwards* to pass over the Fold of Douglas, and *lastly upwards* in the substance of the Rectus to join the Internal Mammary Artery.
- Near its origin it passes upwards by the inner side of the Internal Abdominal Ring, and
- sends its *Pubic* ,, *Branch* along ,, ,, ,, Crural ,, ,,
- ,, ,, *Cremasteric* ,, into ,, Inguinal Canal to supply the coverings of the Cord.
- Its other Branches are the *Perforating* forwards through the Rectus, and the *Lateral*, *outwards* to join the latera arteries of the Abdominal Wall.

Circumflex Iliac (Deep)
- Passes outwards in the Subperitoneal Fascia to the *anterior* end of the Iliac Crest, where it gives off a Muscular Branch *upwards* through the Transversalis to the Abdominal Muscles,
- perforates the Transversalis near the *middle* of Crest, anastomoses with the Ilio-lumbar Artery, and gives Branches *outwards* to the Gluteal Region and *inwards* to the Iliac Fossa.

* Omitted from p. 125.

INTERARTICULAR FIBRO-CARTILAGES.

There are *five Joints* on each side of the Body which contain more or less freely moveable Interarticular Fibro-Cartilages, viz. :—

One in the Head, —the **Temporo-maxillary** Joint.
,, ,, ,, Upper Extremity, — ,, **Inferior Radio-ulnar** ,, (Wrist).
,, ,, ,, Lower ,, — ,, **Knee-Joint.**
,, at each end of the Clavicle,— ,, **Sterno-clavicular** and **Acromio-clavicular** Joints.

NUTRIENT FORAMINA.

When the Body is semi-recumbent and when all the Joints are semi-flexed, the Nutrient Foramen in each bone will be found to be directed more or less toward the ground.

SUPRASCAPULAR ARTERY AND NERVE (p. 134), **ETC.**

In the case of these structures, as in most cases where an Artery and a Nerve take similar courses, the Artery takes the course which *appears* to render it less liable to compression than the Nerve, *e.g.*, Naso-palatine Nerve and accompanying Artery in the Anterior Palatine Foramen, Hypoglossal Nerve and Lingual Artery in relation with Genio-hyo-glossus, etc.

Nerves on the *left* side of the Body generally lie more anteriorly than those on the *right* side, *e.g.*, the Naso-palatine Nerves in the Ant. Palatine Foramen, the Phrenic Nerves and the Pneumogastric Nerves. **Muscles** and **Aponeuroses**, on the other hand, are more developed on the *right* side than on the *left*, e.g , the Right Crus of Diaphragm, the Right Platysma and the Right External Oblique (which overlap the Left), etc.

When *two associated structures* lie one above another, the lower is generally the larger, *e.g.*, the two sets of Branches of the Lenticular Ganglion, the two Branches of the Superior Gluteal Nerve, the Pudic Nerve and the Nerve to the Obturator Internus on the Ischial Spine, etc.

INDEX.

BONES.

	Description.	Articulation.	Ossification.	Structures in relation.
	PAGE	PAGE	PAGE	PAGE.
Astragalus	42	39, 40, 41, 43	48	64, 105
Atlas	7	51, 52	44	51, 52, 73, 84, 134
Axis	7	51, 52	44	51, 52, 83, 84
Calcaneum	41	42	48	64, 103–106, 111, 129
Carpus	31, 32		47	56, 109
Clavicle	23, 30		46	23, 54, 55, 75, 76, 81, 90–93, 108, 109, 131, 134, 151, 153, 165
Coccyx	8, 35		45	59, 83, 89, 102, 122, 167, 183
Cuboid Bone	42	41, 43	48	64, 106
Cuneiform Bone of Carpus	31, 32		47	56, 57
Cuneiform Bones of Tarsus	43	42, 43	48	64, 104–106
Ethmoid Bone	14, 20, 21	11, 15, 17	45	
Femur	36, 37	38	48	60–62, 100–103, 125–128
Fibula	40	38, 39	48	61–64, 102, 104, 105, 111, 129, 130, 185
Frontal Bone	11, 20, 21	10, 11, 15	45	67
Humerus	25		47	26, 55, 90–96, 141, 142
Hyoid Bone	18		46	76, 78, 80, 108
Ilium	33		48	33, 59, 60, 81, 83, 100, 101, 103, 128
Innominate Bone	33, 34		48	34, 100–103
Ischium	33, 34		48	33, 34, 59, 60, 89, 101–103
Lachrymal Bone	21	11	46	67
Malar Bone	21	11, 12	46	69, 71, 172
Maxillary Bone, Inferior	18, 77	12	46	71, 72, 76, 78, 108, 132, 133, 135–137, 176
Maxillary Bone, Superior	16, 21	11, 17	45	68, 71, 72
Metacarpal Bones	32	31, 32	47	57, 58, 96–99, 143–145
Metatarsal Bones	43	42, 43	48	64, 104–107, 130
Nasal Bone	21	11	46	
Occipital Bone	9, 10, 20	12–14, 51, 52	45	51, 67, 73, 75, 81–84, 93
Os Magnum	31, 32		47	57, 98
Palate Bone	17, 21	15, 17	46	72
Patella	37		48	62, 63, 100, 103
Parietal Bone	10, 20	10–12	45	
Pelvis	35	59		81, 82, 110
Phalanges of Foot	43		48	64, 104–107
Phalanges of Hand	32, 43		47	58, 97–99
Pisiform Bone	31, 32		47	56, 57, 97, 99, 109
Pubes	34		48	6, 34, 59, 85, 86, 89, 101, 103
Radius	29, 31	25, 31	47	55, 56, 94–96, 109, 143–145
Ribs	22, 84	5, 52, 53	46	29, 52, 53, 73, 81–88, 91–93, 108, 109, 117, 122, 131, 134, 135, 141, 170
Sacrum	8, 35	33	44	51, 59, 82, 83, 89, 101, 102, 122
Scaphoid Bone of Carpus	31, 32	29	47	56, 57, 109
Scaphoid Bone of Tarsus	43	42, 43	48	64, 111
Scapula	24		46	55, 76, 81, 90–94, 134, 135, 142
Semilunar Bone	31, 32	29	47	57
Sphenoid Bone	14, 15, 20, 21	10–15, 17	45	14, 15, 71, 79
Sphenoidal Turbinated Bone	21		45	
Sternum			46	53, 54, 75, 76, 87, 91, 93, 108, 122, 134, 153, 165, 168, 176
Tarsus	41–43		48	64, 105, 130
Temporal Bone	12, 13, 20	10, 12, 13	45	76, 78, 79, 93
Tibia	38, 39	40, 42	48	61–64, 100–105, 110 111, 129, 130
Trapezium	31, 32		47	56, 57, 97, 98, 109
Trapezoid	31, 32		47	57, 98
Turbinated Bones		17	46	172, 173
Ulna	27, 28, 30	25, 29, 31	47	27, 28, 55, 56, 94–96, 143–145
Unciform	31, 32		47	57, 99, 109
Vertebræ	5–8, 84	51, 52	44	51, 52, 59, 73, 81–84, 86–88, 91, 93, 100, 108, 109, 115–117, 132, 134, 135, 150, 154
Vertebræ, Special	7, 8		44	
Vomer	17, 21		46	

CANALS.

	Position.	Structures in relation.
	PAGE	PAGE
Carotid	**13**	133, 139, 146, 147
Dental, posterior	16	137
Eustachian Tube	**13**	79, 137–139, 146, 175
Ethmoidal Canals	**11**	146
Infra-orbital	16, 21	137
Meatus Auditorius Externus	13	20, 133, 166
Meatus Auditorius Internus	13	20
Palatine Canals	16, 17	137
Pterygo-palatine	14, 15	137
Vidian	15	137

CRESTS, Etc.

Iliac Crest	33	59, 82, 85, 86, 91, 101, 102, 167, 170, App.
Pubic Crest	34	170
Superciliary Ridge	11	67
Temporal Ridge	10–12	108

CARTILAGES.

Costal		53, 54, 76, 85–88, 91, 93, 115, 134, 153, 170
Cricoid		78, 132, 133
Interarticular of Jaw		72
Thyroid		76, 78, 79, 132, 135
Triangular of Wrist	28, 56	
Xiphoid		53, 86–88

FORAMINA.

	Position.	Structures in relation.
	PAGE	PAGE
Cæcum of Frontal Bone	11	20, 152
Carotid	12	146
Condyloid, Anterior	**9**	20, 152
Condyloid, Posterior	**9**	20
Dental, Inferior	18, 72	137
Ethmoidal	21	146
Hiatus Fallopii	13	20, 146
Glaserian Fissure	12	137
Lacerum, anterius	15, **19**	20
Lacerum, medium	**19**	138, 146, 152
Lacerum Posterius (Jugular)	**19**	14, 151, 152
Magnum	9, **19**	51, 52, 146
Mastoid		20, 152
Mental	18, 69	
Obturator	33–35	101
Optic	15	20, 70
Ovale	**14**	20, 137, 146, 173
Parietal		20, 152
Rotundum	**14**, 15	20
Sacro-sciatic	33	101, 123, 183, 184
Sphenoidal Fissure	15, **19**	20, 70, 139, 171
Spheno-palatine	21	137
Spinosum	**14**	20, 137, 146
Stylo-mastoid	12, **13**	138
Supra-orbital	21	11
Vesalii	**14**	20, 152

FOSSÆ, Etc.

Acetabulum	33, 34	60
Antrum	16, 21	
Ischio-rectal		123, 184
Meatuses of Nose	17, 21	
Nasal	21	
Orbital	21	67
Popliteal Notch	38, 61	
Spheno-maxillary	15, 17	137
Sphenoidal Sinus	14, 15, 21	
Bicipital Groove	25	26, 81, 91, 92, 94
Lachrymal Groove	16	70
Musculo-spiral Groove	25	26

PROCESSES.

	Description.	Articulation.	Ossification.	Structures in relation.
	PAGE	PAGE	PAGE	PAGE
Acromion	24		46	54, 81, 91, 92, 165
Angular	16			11, 67
Basilar	9, 14		45	52, 73, 78
Clinoid	14, 15			139
Condyloid of Lower Jaw	18			71, 72, 137
Coracoid	24		46	54, 55, 91, 94, 109
Coronoid of Lower Jaw	18			71, 72, 137
Coronoid of Ulna	27, 28	25		27, 55, 94, 95, 96
Jugular	9			51, 73
Malleolus, Internal	38, 39	42		64, 104, 105, 111, 129, 130
,, External	39, 40	42		63, 64, 104, 111, 129, 130, 169
Mastoid			45	67, 75, 82, 83, 133, 138
Odontoid		7	44	52
Olecranon	27, 28	25		27, 55, 94, 95
Pterygoid of Sphenoid	14		45	71, 72, 78
Tuber Ischii	34		48	59, 89, 101, 102, 123
Styloid of Fibula	40			61
Styloid of Temporal	13, 79		45	61, 71, 76, 79, 108, 132, 133
Styloid of Ulna	28			56
Styloid of Radius	29, 30, 40			56, 96
Zygomatic	12		45	67, 71, 108, 138, 172

JOINTS AND LIGAMENTS.

	Description.	Attachments.	Structures in relation.	Use.
	PAGE	PAGE	PAGE	PAGE
Acromio-clavicular	54	24		
Ankle	64			
Anterior Ligament	39, 42, 64	39, 42		
External lateral ,,	39, 42, 64			
Internal lateral ,,	40–42, 64	39–42		
Posterior ,,	39, 64	39, 42		
Atlo-axoid	51			
Calcaneo-astragaloid	64	41, 42		
Calcaneo-cuboid	64			
Calcaneo-scaphoid	64	42		
Capsular, of Knee	61		62	62
,, of Hip	60		100–102	
,, of Shoulder	55		92	
Carpo-metacarpal	57			
Clavicular	54			
Carpal	57			
Check Ligaments		7, 9		
Conoid	54	23, 24		
Costo-transverse	52		117	
Elbow	55, 142–144	25, 94, 96	26, 56, 94, 143–145, 179, 180	
Glenoid	55	92, 94		
Hip	60		100, 101, 102, 182, 184	
Ilio-lumbar		8, 59, 86, 100		
Intervertebral		51, 100	52	5
Knee	61			
Posterior Ligament	61	102, 103	127, 182, 185	62
Lateral Ligaments	61	37, 40, 100, 102	63, 127	62
Crucial ,,	61	37, 38	62	62
Ligamentum Patellæ	61	37	63, 127	62
Lumbo-sacral		59	122, 123, App.	
Metacarpal	57, 58			
Metatarsal	64			
Nuchæ Ligamentum		81, 83, 108		

Joints and Ligaments—*continued.*

	Description.	Attachments.	Structures in relation.	Use.
	PAGE	PAGE	PAGE	PAGE
Occipito-atloid	**51**			
Occipito-axoid	**52**			
Orbicular	56	55	29	
Phalangeal of Foot		64		
,, ,, Hand	**58**			
Plantar	**64**	41, 42, 106		
Poupart's		85, 86	122, 125, 126, 170, App.	
Pterygo-maxillary		72, 78		
Pubic	**59**			
Radio-ulnar	**56**			
Sacro-iliac	**59**	8, 33, 83		
Sacro-sciatic, Greater		8, 34, **59**, 101, 102		
,, ,, Lesser		8, 33, 89, 101, 102		
Shoulder	**55**, 141	94	90–93, 178	
Sterno-clavicular	**54**	131, 132, 133		
Sternal	**53**			
Stylo-hyoid		78, 79	77	
Stylo-maxillary		79, 108		
Vertebro-costal	**52**			
Tarsal	**64**		70, 185	
Temporo-maxillary			174	
Internal Lateral			137, 176	
Trapezoid	**54**	23, 24		
Transverse, of Hip	**60**			
Transverse, of Knee	**61**			
Vertebral	**51**, 52	52, 91	81, 115, 119, 122	52
Triangular		**89**	123	
Wrist	**143–145**	28, 29	109, 180	

SYNOVIAL MEMBRANES AND BURSÆ.

Of Ankle	64
Of Annular Ligaments of Hand	110, 98
Of Annular Ligaments of Foot	104, 105, 111
Atlo-axoid	52
Of Carpus	57, 58
Costo-sternal	52
Of Elbow	55, 56
Of Foot	64
Interchondral	52
Of Knee	62, 63, 103
Of Hip	60, 100
Radio-ulnar	55, 56
Of Shoulder	55, 93
Tibio-Fibular	63
Of Wrist	56, 98

Figures in block type indicate the page on which the structure to which they refer is more fully treated of.

MUSCLES.

	Description.	Attachments. Origin.	Attachments. Insertion.	Relations.	Action.
	PAGE	PAGE	PAGE	PAGE	PAGE
Adductors (of Thigh)	**101**	34	37	110, 125–127, 182, 184	100
Anconeus	**96**	26	27	94, 95, 179	
Biceps (of Arm)	**94**	24, 55, 92	29	55, 56, 91, 141, 142, 171, 179	92
,, (of Leg)	**102**	34	40, 61	103, 110, 127, 184, 185	103
Brachialis Anticus	**94**	26, 109	27, 28	142, 179	
Buccinator	**71, 72**			136, 172	
Cervicalis Ascendens	**82**		84	84	
Coccygeus	**89**	8, 33		183	
Complexus	**82**	84	10	84, 135, 138	
Constrictor Inferior	**78**			135	
,, Middle	**78**	18, 79		176	
,, Superior	**78**	15, 72		71, 80, 138, 147	
Coraco-brachialis	**91**	24	26	92, 94, 141, 142, 179	90
Crureus	**103**	36	40	182	
Deltoid	**91**	23, 24	26	55, 92, 141, 165, 171, 178	90
Diaphragm	**88**			119, 122, 154–156, 177	
Digastric	**76**	18		12, 75, 132, 135, 138, 176	77
Erector Spinæ, etc.	**82**	8, 33, 109		83, 86	
Extensor Carpi Radialis Brevior	**95, 97**			30	
Extensor Carpi Radialis Longior	**96, 97**	26, 109		30, 95, 179	95
Extensor Carpi Ulnaris	**95, 97**	28		30, 144, App.	
Extensor Com. Digitorum	**95, 98**			30, 99, App.	58
,, Indicis	**95, 98**	28	95	30, 95, App.	95
,, Longus Digitorum	**104**	40	106	111, 129, 185	
,, Minimi Digiti	**95, 98**			30, App.	
,, Ossis Metac. Poll.	**95, 98**	28, 29		30, 95, 143, 144, App.	95
,, Primi Intern. Poll. / ,, Secundi Intern. Poll.	**96, 98**	28		30, 95, 143, App.	95
Extensor Proprius Pollicis	**104**	40	106	111, 129, 185	
Flexor Accessorius	**106**	41		105, 107, 130, 185	
,, Carpi Radialis	**95, 97**			143, 179	
,, ,, Ulnaris	**95, 97**	28	99	143, 180	
,, Brevis Digitorum	**106**	41		105, 107, 111, 130, 185	
,, ,, Pollicis (of Hand)	**98**			97, 179, 180	
,, Brevis Pollicis (of Foot)	**106**	104		105, 107, 186	
,, Longus Digitorum	**105**	38, 104		39, 104, 106–107, 111, 129, 185	104
,, ,, Pollicis (of Hand)	**96, 97**	27, 29		95, 179	95
,, Longus Pollicis (of Foot)	**105**	40		39, 41, 42, 107, 111, 185	104, 130
,, Profundus Digitorum	**96, 97**	27, 28		95, 99, 179, 180	95
,, Sublimis Digitorum	**96, 97**	27, 29		95, 179	95
Gastrocnemius	**103**	37, 61		62, 63, 105, 127, 129, 130, 185	
Genio-hyo-glossus	**76**		18, 80	80, 135, 176, App.	77
Genio-hyoid	**76**		18	176	77
Gluteus Maximus	**102**	18, 33	36, 110	103, 184	100, 103
,, Medius	**101**	33, 110	36	183	100
,, Minimus	**101**	33	36, 60, 102	102, 183	100
Gracilis	**101**	34	38	61, 63, 103, 182	100, 103
Hyo-glossus	**76**	18	80	80, 135, 176	77
Iliacus	**100**	33	36	102, 125, 170, 181, 182	101
Infraspinatus	**93**	24	25, 26	55, 142, 178	
Intercostals	**87**			117, 170	
Interossei of Foot	**107**			130, 186	
Interossei of Hand	**99**		98	107, 143–145, 180	
Latissimus Dorsi	**81, 91**	24, 33, 109	26	85, 92, 141, 178	90
Levator Anguli Scapulæ	**81**	73, 84	24	73, 75, 84, 177, 178	92, 93
,, Ani	**89, 90**	33	80	183	
Longus Colli	**73**	7		131, 132, 134, 156, 178	116, 117
Masseter	**71, 72**			108, 136	

Muscles—*continued*

	Description.	Attachments. Origin.	Attachments. Insertion.	Relations.	Action.
	PAGE	PAGE	PAGE	PAGE	PAGE
Multifidus Spinæ	83	84, 91	84, 91	84, 102	
Mylo-hyoid	76	18, 72	18	176	77
Obliqui Abdominis	85, 86	33, 91	34, 59, 91	168, 170	
,, Capitis	81, 84		10	138	
,, Oculi	70				
Obturator Externus	101	34	36	33, 102, 124, 126, 182	100
,, Internus	101	33, 34	36	102, 123, 181, 183	100
Occipito-frontalis	67	10, 11, 68			
Omo-hyoid	76	24	18	75, 108, 131, 132, 176	
Pectineus	101			125, 126, 182	100
Pectoralis Major	91	23, 34, 85	26, 36	92, 109, 141, 165, 170, 178	90
,, Minor	91		24	141, 178	
Peronei	104	40		39, 40–42, 104–107, 111, 185	
Plantaris	103	61		127, 185	104
Popliteus	103	37	38	61–63, 127, 185	
Pronator Quadratus	96, 97	28	29	95, 145, 179	95
,, Teres	95, 97	26	27, 29	94, 142, 179	
Psoas Magnus	100			102, 121, 122, 125, 126, 181, App.	
Pterygoideus Ext.	71, 72	15		18, 176	
,, Int.	71, 72	15		136, 147, 176	
Pyriformis	101	33	36	33, 102, 123, 183	100
Quadratus Femoris	102	34	36	101, 126, 183, 184	100
,, Lumborum	86	33		85, 122, 170, 181	
Quadriceps Ext. (Tendon)			37, 110	62, 63, 126	
Rectus Abdominis	86	34		85, 134, 168, App.	
Recti Capitis Antici	73, 81		10	74, 132–134, 177	
,, ,, Postici	84		10, 73		
Rectus ,, Lateralis	73		9, 10	74, 177	
Rectus Femoris	103	33, 60	37, 102	102, 126, 182	
Recti Oculi	70			171	
Rhomboidei	81		24	178	92, 93
Sartorius	100	33	38	61, 63, 101–103, 125, 126, 169, 182	103

	Description.	Attachments. Origin.	Attachments. Insertion.	Relations.	Action.
	PAGE	PAGE	PAGE	PAGE	PAGE
Scalenus Anticus	73		74	74, 75, 131, 132, 134, 151, 156, 178	
,, Medius and Post.	73		74	74, 75, 131, 177, 178	
Semi-membranosus } Semi-tendinosus }	102	34	38	61, 103, 127, 184	103
Serratus Magnus	93	73	24	85, 141, 168, 178	92
Serrati Postici	81		73	109	
Soleus	105	38, 40, 104		129, 130, 185	104
Splenius	83	84	10, 74, 84	12, 74, 75, 84	
Sterno-cleido-mastoid	75	93	10, 23, 93	12, 108, 131–133, 135, 151, 177	92, 93
Sterno-hyoid } Sterno-thyroid }	76	23	18	75, 131; 132, 176	
Stylo-glossus		79	80	79, 80, 136, 147, 176	76
Stylo-hyoid	76	79	18	79, 132, 136	
Stylo-pharyngeus	79			78, 132, 133, 136, 147, 176	
Subclavius	93		23	109, 134, 178	92
Subscapularis	93	24	25, 26	55, 141, 143, 178	
Supinator Brevis	96	27	29	95, 144	
,, Longus	96	26, 109	29	95, 143, 179	
Supraspinatus	93	24	25, 26	55, 142, 178	
Temporal	71, 72	11, 15, 108	18	18, 108, 138	
Tensor Palati	79, 80	15		78, 175	
Tensor Vaginæ Femoris	101	33		103, 183	103
Teres Major and Minor	92	24	25, 26	94, 178	90
Tibialis Anticus	104	38		111, 129, 185	
,, Posticus	105	38, 40, 104		39, 107, 111, 129, 185	104, 130
Trachelo-mastoid	82	84		12, 75, 84	
Transversalis Abd.	85, 86	33	34,	122, 170, App.	
Trapezius	81	10, 92, 93	23, 24, 92, 93	108, 135, 138	92
Triceps (of Arm)	94	24, 26, 55, 92	27, 109	55, 92, 141, 142, 171, 179	92
Vasti, Ext. and Int	103	36		62, 110, 126, 127, 182	

ARTERIES.

	Origin.	Course.	Distribution.	Relations.
	PAGE	PAGE	PAGE	PAGE
Acromio-thoracic	**141**	109		
Anastomotica (of Arm)	**142**	109, 144	144	144
Anastomotica Magna (of Leg)	**126**		128, 129	
Aorta, Arch of	**115**		116–118; 153	148, 150, 153, 156
,, Thoracic	**115**	116–118, 153	116	116, 150, 153, 156
,, Abdominal	**119**	88	120–122, 155	150, 155
Articular of Knee	**127**	61	126–129	61, 185
Auditory Arteries		13, 20		
Auricular, Posterior		**146**		133
Axillary	**141**			
Basilar	**139**	20	143	140
Brachial	**142**			
Bronchial	**118**			
Carotid, Common	115, **116**, 132	132, 133	131	117, 132, 150, 151
,, External	**132**	123	131, 135–138	71, 79, 159, 174, 176
,, Internal	132	13, 19, **133**, 139, 147	131, 139	71, 79, 138–140, 147, 151, 176
Carpal Arch, Anterior } ,, ,, Posterior }	**143–145**		130	
Cerebellar	139	**140**		
Cerebral	139	**140**		160
Cervical Ascending	**134**			75, 135, 151
,, Transverse	134	**135**		75, 131, 132
Cervicis Princeps	**138, 148**		135	
,, Profunda	**135, 148**			151
Choroid	**140**			
Ciliary	**139**	147	147	
Circumflex, Ant. and Post.	**141**			
Circumflex, Ext. and Int.	**126**		128, 129	
Circumflex Iliac, Superf. and Deep	App.		128	
Coccygeal	123		123, 128	
Colica Dextra, Media, and Sinistra	120, 121		120, 121	
Cœliac Axis	119	**120**	148	149
Coronary of Heart	115, **118**		120	115
,, ,, Lips	136			
Dental	**137**		69, 77, 148	
Diaphragmatic	**122**		121	
Dorsalis Linguæ	**135**		147	
,, Pedis	129	**130**		
Epigastric Arteries	**126, App.**		128, 134, 150	150
Ethmoidal ,,	**139**, 146	11, 20	146	
Of Eyelids			147	
Facial	**136**	18	139, 146, 147	77, 136, 151
Femoral	**125**		126, 128, 129	127, 182
Frontal	**139**		147	
Gastric	**120**		148	148
Gluteal	**124**	33	123, 128	
Hœmorrhoidal	121, **124**		121	122, 149, 184
Of Hard Palate			147	
Hepatic	**120**		148	118, 149, 155
Iliac Arteries	**122**	App., 123	123, 124, 128, 150	118, 121, 123 150
Ilio-lumbar	**124**		128, App.	150
Infra-orbital	**137**		69, 147	
Innominate	115, **116**			150, 153
Intercostal	116, **117**		122	118, 150
,, Superior	**135**		134, 148	150
Interosseous, Ulnar	**144**	56	145	56
,, of Foot and of Hand	**130**			
Intestinal	120		120	
Lachrymal	**139**	15	19, 138, 147	
Laryngeal	134, **135**	78		
Lingual	**135**		147	77, 151
Lumbar	**122**			150
Of Lungs			148	
Mammary Internal	**134**		117, 122, 150, App.	150
Maxillary Internal	**137**		146	71, 151, 172
Mediastinal, Posterior	116, 117	117		
Meningeal, Anterior	146			
,, Middle	**137, 146**	10, 12, 14, 19, 20	19, 20, 139	138, 174
,, Posterior	**138**, 139, **146**	19		
Mesenteric, Inferior	119	**121**		
,, Superior	119	**120**	149	149

Arteries—*continued.*

	Origin.	Course.	Distribution.	Relations.
	PAGE	PAGE	PAGE	PAGE
Metacarpal and Metatarsal	**130**			
Musculo-phrenic	**134**		122	
Mylo-hyoid	**137**			77
Nasal of Ophthalmic	**139**		136, 147	
,, ,, Internal Maxillary	**137**, 146	146	146	
,, (Lateral) of Facial	**136**		146	
Of Nose		146	146	
Obturator	**124**		128	
Occipital	**138**	146	19, 133, 146, 148	74, 75, 133, 138, 176
Œsophageal	**118**, 134		**148**	
Ophthalmic	**139**	20, 146	146	151, 160
Orbital	**137**			
Ovarian	**121**			155
Palatine, Ascending	**135**	147	147	147
,, Descending	**137**		147	
Palmar Arches	143, **145**			
Palpebral	**139**		147	
Pancreatic	120		120, **149**	149
Pancreatico-duodenalis	120		120	149
Perforating of Hand	**145**			
,, of Foot	**130**			
,, of Thigh	**126**		128	
Plantar	129	**130**		
Pericardiac	116, 117	117		
Peroneal	**130**	63		63
Pharyngeal, Ascending	**138**	147	19, 147, 148	133, 176
Popliteal	125	**127**	127–129, 182	185
Profunda, of Arm	**142**	109, 144	144	144
,, of Thigh	126	125	126, 128, 129	125
Pterygo-palatine	**137**		147	
Pudic Internal	**123**	33, 34		184
Pulmonary	**148**			115, 118
Pyloric	**120**			148
Radial		**143**	130	
,, Recurrent	**143**	**144, 145**		
Ranine	**135**		147	
Of Rectum			149	
Renal	**121**			118
Sacral Lateral	**124**		122, 128	
,, Middle	**122**			
Of Scalp		**146**	138	
Scapular Posterior	**135**		142	
Sciatic	**123**	33	128	184
Of Soft Palate			147	
Spermatic	**121**			155, App.
Of Spinal Cord	**117**	19		
Spinal Arteries	**117**, 139			
Splenic	120		148	149
Sterno-mastoid, of Occipital	**138**			75, 133
Sterno-mastoid, of Sup. thyroid	**135**			75, 132
Stylo-mastoid	**146**			
Subclavian	115, **131**	73, 117	134, 135, 150, 153	75, 116, 134, 150 151, 156
Sublingual	**135**			
Of Suboccipital Triangle			**148**	
Subscapular	**141**		142	
Supra-orbital	**139**	11	147	
Supra-scapular	**134**		142	75, 131, 132
Temporal Superficial	**138**	146	108	146, 174
Thoracic	**141**	109		
Thyroid Axis	**134**			
,, Inferior	**134**		75, 78	132, 161
,, Superior	**135**		75, 78, 132, 148	
Tibial Arteries	**129**	63, 111	130	185
Of Tonsil	135–137	**147**		
Tympanic	137–139, **146**	137	146	
Ulnar	**143**		130, 143-145	
,, Recurrent	**144**			
Uterine, etc.	**124**		121	
Vasa Brevia	120		120	148
Vertebral	**134**	7, 19, 51, 139	19, 135, 139, 148	7, 74, 135, 139, 140, 151, 160
Vesical	124		124	
Vidian	137		146 147	

VEINS.

	Origin.	Course.	Distribution.	Relations.
	PAGE	PAGE	PAGE	PAGE
Axillary	154			141
Azygos Veins	**153**	88		116, 119, 155, 156
Basilic	**154**			142
Cardiac	**154**			
Cava Superior	**153**			115
Cava Inferior	122, **155**			88, 119, 121, 122
Cephalic	**154**	109		141
Emissary		11, 14, 19, 20, 152		
Facial		151	**151**	133
Femoral		**156**		125
Iliac Veins	**155**			118, 122, App.
Innominate	151, **153**			115, 116, 117
Intercostal, Superior		163		115, 153
Jugular, Anterior		151		75, 131, 132
,, External	**151**	133		71, 75, 131, 133
,, Internal	**151**, 152			71, 74, 131, 132, 133, 134, 138, 176
Lingual		151		133
Median Veins	**154**			142
Mesenteric Veins		**155**		
Occipital Veins		151	20	75
Ophthalmic		19, 20, 152		
Pelvic	**155**			
Poplitcal		**156**		
Portal	**155**			118
Pterygoid Plexus			20, 151	
Radial	**154**			
Renal		121	**155**	118, 119, 121
Saphena Veins	**156**			
Sinuses Cranial			**152**	
Sinus Cavernous		14	20	139, 171
,, Lateral		9, 10, 12, 13, 19, 151	20	9
,, Longitudinal Superior		9, 10	20	9
,, Petrosal Inf.		9, 13, 19, 151		9
,, ,, Sup.		13		
Spermatic		**121**		
Spinal	**154**	19	152	
Splenic		155		119
Subclavian	**151**			131, 132, 134
Suprascapular		**151**		131
Thyroid Veins		151, 153		132, 153
Transverse Cervical		**151**		131
Ulnar	**154**			
Vertebral	**151**		135	131, 134

DUCTS.

	Origin.	Course.	Distribution.	Relations.
Hepatic Duct				118, 155
Lymphatic Duct (right)		156		75
Receptaculum Chyli				118
Steno's Duct		133		138
Thoracic Duct	156	88, 156	156	75, 115, 116, 117, 153
Wharton's Duct				77

NERVES.

	Origin.	Course.	Distribution.	Relations.
	PAGE	PAGE	PAGE	PAGE
Arnold's	159	13		
Auricular, Posterior	**165**		166	138, 166
,, Great	177	**165**	166	166
Auriculo-temporal	**165, 174**		166, 175	72, 137, 166
Buccal	165, 174	174		72, 137, 174
Cardiac Nerves			161, 162	115, 116, 117, 131
Carotid of Sympathetic		19		139
Cavernous of Sympathetic		19		139
Cervical, 1st		7		7, 74
,, 2nd		51		75
,, Anterior	177		159, 160	134, 177
,, Posterior	**166**			
,, Superficial	177	**165**		177
Chorda Tympani	176	176	175	
Circumflex	**178**	171	167, 168, 171	171
Crural, Anterior	**181**, 182		100, 182	125
Cutaneous, Internal of Arm	**179**	171, 180	168, 171, **172**, 180	137, 141, 142, 171, 180
,, ,, ,, Leg		**167-169**		125
,, External ,, ,,		**167-169**	181	
,, Middle ,, ,,	182	**168, 169**		
Dental, Inferior	**176**	174	69, 77	72, 137, 174
,, Posterior			172	137
Descendens Noni				
Dorsal Spinal	**166**		170	170
,, ,, last			**167**, 181	
Facial		13, 20, **165**, **166**	174, 175	71, 133, 138
Fifth Cranial		**165**, **166**	160	
Fourth ,,		19, **171**	160	140
Frontal		19		139
Genito-crural	**181**		168	168, App.
Glosso-pharyngeal	**176**	19, 78	159	77, 133
Gluteal, Superior	**183**	33	101	
Gustatory	**176**	174	175	72, 77, 137, 174
Hypoglossal	**176**	9, 20	159, 177	77, 133, 138
Ilio-hypogastric	**181**	168, **170**	167, 168	167, 168
Ilio-inguinal	**181**	168, **170**	168	168
Infra-orbital	**165**		166, 172	
Infra-trochlear			69, 166, **172**	137
Intercostal		**168, 170**		
Intercosto-humeral			**171**	180
Jacobson's	159	13	**175**	
Lachrymal		19, 171	166, 172	139, 171
Laryngeal, Recurrent (Inf.)		78	161, 162	115, 131, 132
,, Superior	159	78		133
Lumbar, Posterior	**166**	**167**		
Lumbo-sacral	**181**		183	
Masseteric		174		72
Maxillary, Inferior		14, 20, **165**	175, 176	71
,, Superior		14, 20, **165**, **166**	**172**	137
Median	**179**		180, 168, 171, 186	141, 142, 144
Musculo-cutaneous of Arm	**179**	**171**	94, 167	141, 171, 185
,, ,, ,, Leg		**169**		129
Musculo-spiral	**179**	109	94, 167, 168, 171, **180**	141, 142
Nasal, of Ophthalmic		20, **171**	166, 173, 175	166
,, from Meckel's Ganglion			**172**, 173	137
Naso-palatine			**172**, 173	137
Obturator	**181**		101, 182	124, 125, 127
Occipital, Great	**165, 166**			
,, Small	**165**, 177		166	166
Olfactory		14, 20		
Ophthalmic		**165, 166, 171**	175	
Optic		14, 20		139, 171
Palatine		16	**172**	137
Perineal	**184**			123
Petrosal, Great		20	160, 172, 175	
,, Small		20	175	
Pharyngeal	159			133
Phrenic	177, 178		163	115, 116, 132, 153
Plantar			130, **167**, 186	
Pneumogastric		19, 88	159, 161, 163, 166, 171	115, 116, 117, 131 132, 140
Popliteal	**185**		167, 169	127
Pterygo-palatine			**172**, 173	137
Pudic	183	33, **184**		123
Radial			167	143

Nerves—*continued.*

	Origin.	Course.	Distribution.	Relations.
	PAGE	PAGE	PAGE	PAGE
Sacral, Posterior . .	**166**	**167**	164	
Saphenous, Long or Int.	182	**169**		125, 126
,, Short or Ext.	185			
Sciatic, Great . . .	183	33, **184**		
,, Small . . .	183	33, **184**	167	167
Sixth Cranial . . .		14, 19, **171**	160, **172**	139
Spinal Accessory . .		19	93, 159, 177	75, 140
Splanchnic . . .		88	163	
Suboccipital . . .	**166**	51		
Subscapular . . .	**178**			
Supra-orbital . . .	**165**	11, **166**, 171		139, 171
Supra-scapular . . .	**178**			
Supra-trochlear . .		**166**, 171		171

	Origin.	Course.	Distribution.	Relations.
	PAGE	PAGE	PAGE	PAGE
Sympathetic . . .		88	19, 29, 159–164, 175–177	115, 119, 121, 131–133
Temporal, Deep . .				72, 137, 174
Temporo-malar . .	**165**	171	166, **172**	137, 166, 171
Third Cranial . . .		19, **171**	160, 175	139, 140
Thoracic, Posterior . .	**178**			131
,, Anterior . .	**178**	109		141
Tibial, Anterior . .	**185**		169	129
,, Posterior . .	**185**	111	129	129
Ulna		109	130, 167, 168, 186	141–143
Vidian	160	19	172	137
Of Wrisberg . .	**179**	**171**, 180	167	141, 180

GANGLIA.

	Position.	Roots.	Branches.	Relations.
	PAGE	PAGE	PAGE	PAGE
Cervical, Inferior		161	164	
,, Middle		**161**		133, 134
,, Superior		**159**		
Gasserion			160	
Jugular			159	
Lenticular		19, **175**	160, 172	
Lumbar			164	
Meckel's		**172**		137
Otic		174, **175**		
Petrous			159	
Of Root of Vagus			159	
Sacral			164	
Semilunar		**163**		
Submaxillary		**175**, 176		77
Of Trunk of Vagus		**159**		
Of Wrisberg			162	

PLEXUSES.

	Description.	Branches.	Roots.	Relations.
	PAGE	PAGE	PAGE	PAGE
Aortic		163, 164	163	119
Brachial	178–180	178–180		75, 131, 141
Cardiac, Deep	**162**		161	115
,, Superficial	**162**		161	115
,, Superior		159		
Carotid		160		
Cavernous		160, 175		
Cervical	**177**	165		
Cœliac		**163**		
Coronary, of Heart			162	
,, of Stomach		**163**		
Diaphragmatic		**163**		
Hœmorrhoidal, Inferior		**164**		
Hepatic		**163**		75, 131
Hypogastric		**164**		122
Lumbar	181, 182	100, **181–182**		
Mesenteric, Superior		**163**		
Pelvic		**164**	183	
Pharyngeal		159	176	
Prostatic		**164**		
Pulmonary			162	116
Renal		**163**		
Sacral	183–186	**183–186**		123
Solar	163	**163**		119
Spermatic		**163**		
Suprarenal		**163**		
Thyroid		160		
Uterine		**164**		
Vaginal		**164**		
Vesical		**164**		

A FEW OF THE WORKS FOR PRACTITIONERS AND STUDENTS PUBLISHED BY BAILLIÈRE, TINDALL, & COX.

Gant's Science and Practice of Surgery. By F. J. GANT, F.R.C.S., President of the Medical Society of London, Senior Surgeon to the Royal Free Hospital. With Chapters on Special Subjects by Drs. ROBT. BARNES, MORELL, MACKENZIE, MAHOMED, PURVES, Messrs. W. ADAMS, F.R.C.S., HY. POWER, F.R.C.S., C. S. TOMES, F.R.S., SIR ERASMUS WILSON, F.R.S. New Edition in 2 vols., 31s. 6d., entirely rewritten and enlarged, with nearly 1000 Original Illustrations.

"May be safely recommended to students."—*British Medical Journal.*

"We shall be much surprised if it does not become one of the most popular surgical text-books in the English language."—*Medical Press.*

"A very complete and trustworthy guide to practice."—*Medical Times.*

"One of the best, if not *the* best, of surgical text-books."—*Students' Journal.*

"A sound and complete exposition of Modern Surgery, combining the merits of a Text-book with the advantages of a system."—*Indian Medical Gazette.*

Text Book of Operative Surgery. From the French of Professors CLAUDE BERNARD and HUETTE. Illustrated with eighty-eight hand-coloured plates. Edited and re-written by ARTHUR TREHERN NORTON, F.R.C.S., Surgeon to, and Lecturer on Surgery at, St. Mary's Hospital. Price 25s. plain, hand-coloured, 50s.

Politzer's Text Book of Aural Surgery, including the Anatomy and Physiology of the Organ of Hearing: the causes, symptoms, and treatment of ear diseases. Authorised translation by Dr. PATTERSON CASSELLS. Price £1 1s. (*Shortly.*)

Text Book of Anatomical Plates, designed under the direction of Professor MASSE, with descriptive Text. By E. BELLAMY, F.R.C.S., Professor of Anatomy, Government Science and Art Department, Lecturer in Anatomy and Operative Surgery, Charing Cross Hospital. 2nd Edition, plain, 21s., hand-coloured, 42s.

"With these plates, the Student will be able to read up his anatomy almost as readily as with a recent dissection before him."—*Students' Journal.*

Essentials of Anatomy. Designed as a Text-book for Students, and as a book of easy reference for Practitioners on a new and more easily comprehensible basis. By W. DARLING, M.D., F.R.C.S. Eng., Professor of Anatomy in the University of New York, and AMBROSE RANNEY, A.M., M.D., Adjunct Professor. Price 12s. 6d.

"The methods of memorising are peculiar to the authors, and are the results of long experience in the teaching of students. . . . Of much value to the student and practitioner."—*New York Medical Record.*

Osteology for Students, with Atlas of Plates. By ARTHUR T. NORTON, F.R.C.S., Surgeon to, and Lecturer on Surgery at, St. Mary's Hospital. 2nd Edition in one vol. 7s. 6d., two vols. 8s. 6d.

"The handiest and most complete hand-book of Osteology."—*Lancet.*

Manual for the Physiological Laboratory. By VINCENT HARRIS, M.D. Lond., Demonstrator of Physiology at St. Bartholomew's Hospital; and D'ARCY POWER, B.A. Oxon., Assistant-Demonstrator. Price 3s. 6d.

"A book that should be in every student's hands."—*Medical Press.*

A Guide to the Examinations at the College of Surgeons of England for the Diplomas of Member and Fellow, with the Examination Papers from 1869 to 1880. By FREDERICK J. GANT, F.R.C.S., President of the Medical Society of London, Senior Surgeon to the Royal Free Hospital. 4th and Enlarged Edition, price 4s. 6d.

The Pocket Gray; or, Anatomist's *Vade Mecum.* Compiled especially for Students, from the Works of GRAY, ELLIS, QUAIN, HEATH, and LEONARD. Price 2s. 6d.

Anatomography; or, Graphic Anatomy. By W. DARLING, M.D., F.R.C.S., Eng. Price 1s.

The Student's Case Book: Practical Instructions, and all the Necessary Information for Clinical Work and Systematic Case-taking, with Ruled Sheets for recording particulars of cases as seen. By GEORGE BROWN, M.R.C.S. 2nd Edition, enlarged, 1s.

Materia Medica and Pharmacy: For the use of Medical and Pharmaceutical Students preparing for Examination. By W. HANDSEL GRIFFITHS, Ph.D., F.C.S., L.R.C.P. Edin., etc. Edited by GEORGE F. DUFFEY, M.D. Dub., Fellow and Examiner K.Q.C.P., Examiner in Materia Medica, Queen's University of Ireland, Lecturer on Materia Medica in the Carmichael College of Medicine, etc. 8vo., pp. 309, with numerous Tables, 9s.

"A standard text-book on Materia Medica."—*Edin. Med. Journ.*

"Conveys a large amount of reliable information in a clear and attractive form. —*Dublin Journal of Medical Science.*

A Key to Organic Materia Medica. By JOHN MUTER, Ph.D., M.A., F.C.S., President of the Society of Public Analysts. 3rd Edition, 12s. 6d.

An Introduction to Analytical Chemistry for Laboratory Use. By the same Author. 7s. 6d.; also

An Introduction to Pharmaceutical and Medical Chemistry, Theoretical and Practical. With Analytical Tables and copious Index. Same Author. 10s. 6d.

An Introduction to Practical Histology. By GEORGE THIN, M.D. Crown 8vo., price 5s.

"No more valuable Text-book for the Student will be found, nor one containing a greater amount of useful information in the most convenient form."—*Medical Press.*

Modern Medical Therapeutics. A compendium of recent Formula and Specific Therapeutical directions, from the practice of eminent contemporary Physicians, English, American, and Foreign. Edited by G. H. NAPHEYS, A.M., M.D. 7th Edition, price 18s.

Modern Surgical Therapeutics. By the same Author. 7th Edition price 18s.

"No one who carefully peruses this work can feel surprised at the demand for it; edition after edition sells with great rapidity."—*Medical Press.*

"A summary of the best modes of treatment."—*Practitioner.*

"The volume will supply what many practitioners are often anxious to possess for reference in the practice of their art."—*Glasgow Medical Journal.*

LONDON: BAILLIÈRE, TINDALL, AND COX, PARIS AND MADRID.

A Manual of Naval Hygiene. By J. Wilson, M.D., Medical Director of the United States Navy. 2nd Edition, price 10s 6d.
"No ship should leave port without this valuable manual; yachtsmen will also find it a most readable and useful companion."—*Medical Press.*

Manual of Examination of the Eyes. By Professor Landolt. Translated by Swan M. Burnett, M.D. Revised by the Author. Demy 8vo., illustrated, price 12s. 6d.
"For examining eyes this will prove most helpful."—*The Lancet.*

Bright's Disease of the Kidneys. By Professor Charcot. Translated by Dr. Millard. Revised by the Author. With coloured plates, price 7s. 6d.
"We doubt if there exists in the English language any monograph in which the various forms are so accurately and concisely described."—*Medical Press.*

THE STUDENTS' AIDS SERIES.

Specially designed to assist Students in committing to memory, and grouping the subjects upon which they are to be examined.

Aids to Anatomy. By George Brown, M.R.C.S. Fifth Thousand. Price 1s. 6d. cloth, 1s. paper wrapper.

Aids to Surgery. Part I. By the same Author. Price 1s. 6d. and 1s.
" " Part II. Price 1s. 6d. and 1s.

Aids to Botany. Brief Outlines of the Elementary Facts of the Science. By C. E. Armand Semple, B.A., M.B. Cantab., M.R.C.P. Lond. Examiner in Arts at the Apothecaries' Hall. 2nd Edition in preparation.

Aids to Chemistry. By the same author. Third thousand.
Part I.—Inorganic; Non-Metallic Substances. 1s. 6d. and 1s.
Part II.—Inorganic. The Metals. Double part. Price, 2s. 6d. and 2s.
Part III.—Organic. Double part. Price 2s. 6d. and 2s.

Aids to Materia Medica and Therapeutics. By the same author.
Part I. Price 1s. 6d. and 1s.
" Part II. Double part. Price 2s. 6d. and 2s.

Aids to Medicine. Same author. Part I. Double part, price 2s. 6d. cloth, 2s. paper.
" " " Part II. Price 1s. 6d. and 1s.
" " " Part III. Price 1s. 6d. and 1s.

Aids to Forensic Medicine and Toxicology. By W. Douglas Hemming, M.R.C.S. Second Thousand. Price 1s. 6d. cloth, 1s. paper wrapper.

Aids to Examinations; being Questions and Answers on Materia Medica, Medicine, Midwifery. By the same author. Price 1s. 6d. cloth, 1s. paper wrapper.

Aids to Physiology. By B. Thompson Lowne, F.R.C.S., Examiner in Physiology, and Arris and Gale Lecturer, Royal College of Surgeons. Double Part. Price 2s. 6d. cloth, 2s. paper.

The Students' Aids Series—*continued.*

Aids to Diagnosis. Part I.—**Semeiological.** By J. Milner Fothergill, M.D., M.R.C.P. Lond. Price 1s. 6d. and 1s.
Part II.—**Physical.** By J. C. Thorowgood, M.D. and F.R.C.P. Lond., Lecturer on Materia Medica, Middlesex Hospital. Price 1s. 6d. cloth, 1s. paper wrapper.
Part III.—**What to Ask.** By J. Milner Fothergill, M.D., M.R.C.P. Lond. Price 1s. 6d. and 1s.

Aids to Rational Therapeutics, with forms of Prescriptions. By J. Milner Fothergill, M.D., M.R.C.P. Lond. Double Part. Price 2s. 6d. cloth, 2s. paper wrapper.

Aids to Dental Surgery. (In preparation.)

Aids to Mechanics. (In preparation.)

Aids to Obstetrics and Diseases of Women. (In preparation.)

HUMAN ANATOMY AND PHYSIOLOGY.

Illustrated by a series of Movable Atlases of the Human Body, showing the relativ positions of the several parts by means of Superposed Coloured Plates, from the designs of Prof. G. J. Witkowski, M.D. *The Only Authorised English Edition.*

Part I.—**The Human Body (Neck and Trunk).** Text by Robt. Hunter Semple, M.D., F.R.C.P. Lond. Price 7s. 6d.

Part II.—**Throat and Tongue, Showing the Mechanism of Voice, Speech, and Taste.** Text by Lennox Browne, F.R.C.S., Edin., Senior Surgeon to the Central London Throat and Ear Hospital. Price 7s. 6d.

Part III.—**The Female Organs of Generation and Reproduction.** Text by James Palfrey, M.D., M.R.C.P., Lond., Senior Obstetric Physician to and Lecturer on Midwifery and Diseases of Women at the London Hospital. Price 7s. 6d.

Part IV.—**The Eye and the Apparatus of Vision.** Text by Henry Power, F.R.C.S., Senior Ophthalmic Surgeon to, and Lecturer on Ophthalmic Surgery at, St. Bartholomew's Hospital, Surgeon to the Royal Westminster Ophthalmic Hospital. Price 7s. 6d.

Part V.—**The Ear and Teeth.** Text of the Ear by Lennox Browne, F.R.C.S., Edin., Senior Surgeon to the Central London Throat and Ear Hospital; Text of the Teeth by Henry Sewill, M.R.C.S. Price 7s. 6d.

Part VI.—**The Brain** (Cerebrum, Cerebellum, and Medulla Oblongata). By T. Stretch Dowse, M.D., F.R.C.P. Edin., formerly Medical Superintendent of the Central London Sick Asylum. Price 7s. 6d.

Part VII.—**The Male Organs of Generation.** Text by D. Campbell Black, M.D., F.R.C.S. E. Price 7s. 6d.